

Female urethral diverticulum presenting with acute urinary retention: Reporting the largest diverticulum with review of literature

Manas Ranjan Pradhan, Priyadarshi Ranjan, Rakesh Kapoor

Department of Urology and Renal Transplantation, Sanjay Gandhi Postgraduate Institute of Medical Sciences, Raebareli Road, Lucknow, Uttar Pradesh, India

ABSTRACT

Female urethral diverticulum is a rare entity with diverse spectrum of clinical manifestations. It is a very rare cause of bladder outlet obstruction and should be considered as a differential diagnosis in females presenting with acute urinary retention associated with a vaginal mass. Strong clinical suspicion combined with thorough physical examination and focused radiological investigations are vital for its diagnosis. Herein we report a case of giant urethral diverticulum presenting with acute urinary retention in a young female. It was managed by excision and urethral closure, and is the largest urethral diverticulum reported till date in the literature.

Key words: Diverticulum, females, magnetic resonance imaging, urethra, urinary retention

INTRODUCTION

Diverticula of the female urethra are rare lesions occurring predominantly in the distal two thirds of the urethra. They are thought to be derived from the periurethral glands as a result of recurrent infections. Urethral diverticula (UD) have historically been described with the classic triad of three D's e.g. Dysuria, Dysparunia, and Dribbling, which are present only in about one third of cases. They can be asymptomatic and incidentally detected or may present with symptoms like painful vaginal mass, chronic pelvic pain, refractory lower urinary tract symptoms, and recurrent urinary tract infections (UTI).^[1] Because of the varied symptomatology, they pose a challenge to the treating clinician. They predominantly affect

females in third to fifth decade of life with overall incidence of 1–6%.^[1] They tend to be acquired with age; however, rarely they have been described in neonates and children.^[2]

We herein describe a young female with a giant UD measuring 7.3 x 6.2 cm who presented with acute urinary retention (AUR) and had successful outcome after surgery. Female UD presenting with bladder outlet obstruction is very rare and should be kept in mind while evaluating any female with AUR. This case is unique because of its age of occurrence, presentation, and largest size reported till date.

CASE REPORT

A 20-year-old unmarried girl presented to emergency with painful urinary retention since 8 h. She had history of similar episode 2 months back for which she was catheterized for 1 week. She also complained of frequency, poor stream, straining, incomplete voiding, and dysuria for 2 years. She noticed a mass occasionally coming out of vagina on straining. There was no history of hematuria, flank pain, urinary incontinence, menstrual disturbances, or sexual contact. Urinary bladder was palpable on abdominal examination and genital examination revealed a large non-tender cystic mass over anterior vaginal wall. She was catheterized and drained about 800 ml of urine. Routine blood picture and serum chemistries were within normal limits. Urine examination revealed 5-8 pus cells per high power field and sterile culture. Abdominal ultrasonography showed an infravesical mass with no dilatation of upper

For correspondence: Dr. Rakesh Kapoor, Department of Urology and Renal Transplantation, C – Block, Sanjay Gandhi Post Graduate Institute of Medical Sciences, Lucknow – 226 014, Uttar Pradesh, India.

Access this article online

Quick Response Code:	Website:
	www.indianjurol.com
	DOI:
	10.4103/0970-1591.98473

urinary tracts. Transvaginal sonography performed with broadband 9- to 5-MHz tightly curved array probe revealed a hypoechoic cystic structure posterior to urinary bladder and urethra with enhanced through-transmission and a small echogenic structure within it, possibly a stone. Communication with the urethra could not be delineated. A magnetic resonance imaging (MRI) of pelvis was done which showed a well-defined cystic structure posterior to urinary bladder measuring 7.3 x 6.2 cm displacing the uterus superiorly and vagina and cervix posteriorly with no obvious connection with urethra or urinary bladder seen [Figure 1]. Cystourethroscopy was performed using 15F flexible cystoscope with simultaneous digital compression over the bladder neck area and diverticulum. It revealed a large UD opening into the urethra in the right postero-lateral wall of the middle third. A rubber catheter tip measuring about 1 cm was seen inside the diverticulum, a retained foreign body from previous catheterization.

Trans-vaginal excision of diverticulum was done through an inverted U-shaped incision over the anterior vaginal wall. Vaginal flaps were raised with careful preservation of the periurethral fascia and meticulous dissection of the diverticulum up to the neck. Diverticulum was excised and repair was done over 14F catheter in four layers, e.g. urethra, periurethral fascia, Martius flap, and vaginal tissue [Figures 2 a, b]. Suprapubic catheter was not placed and anticholinergics were given in the post-op period for three weeks. The urethral catheter was removed at 3 weeks, after voiding cystourethrogram (VCUG) revealed no extravasation [Figures 2 c, d]. She is presently asymptomatic three years after surgery.

DISCUSSION

Since the first description of UD by William Hey in 1805, increasing number of cases is being reported, especially in last two decades. This is partly because of increased awareness among physicians and increased use of improved radiological investigations.

Corresponding to the location of the periurethral glands, about 90% of UDs open posterolaterally in the middle or distal urethra.^[3] Although usually single, globular, and small, UDs may be multiple, may attain various shapes and grow to large sizes. In our patient, it was extending from the external urethral meatus up to trigone of bladder and displacing adjacent structures. The UD described in our patient is the largest one reported till date [Table 1]. A Medline search revealed the largest female UD reported to be of 6.0 cm.^[4] Female UD is a very rare cause of urinary retention and should always be considered in the differential diagnosis.^[5] About 4% of female UD cause urinary retention.^[6] Groutz *et al* showed that UD contributed to 3% of cases of female bladder outlet obstruction defined as persistent noninvasive maximum flow rate less than 12 ml/s combined

Table 1: Sizes of urethral diverticula in different case series

Series	No. of patients	Max. size (Range) (cm)
Hoffman and Adams ^[9]	60	5 (0.5-5.00)
Pavlica <i>et al</i> ^[4]	47	6.0 (0.5-6.0)
Kim <i>et al</i> ^[10]	16	4.5 (0.9-4.5)
Leach <i>et al</i> ^[11]	61	5.0 (0.2-5.0)
Thomas <i>et al</i> ^[12]	90	5.0 (0.3 - 5.0)
Our case	-	7.3

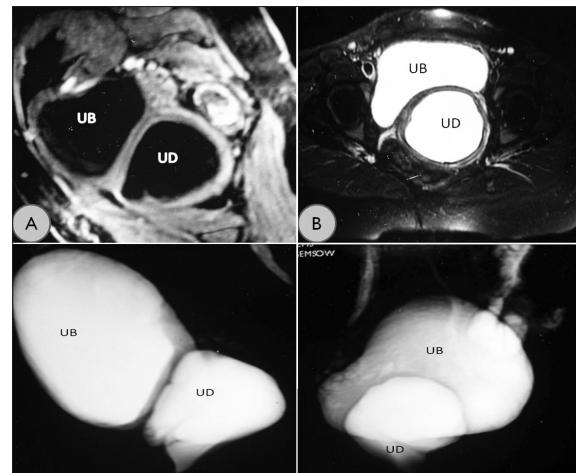


Figure 1: (a) T1-weighted MRI image showing the urethral diverticulum (UD) and urinary bladder (UB) in the sagittal plane. (b) T2-weighted cross-sectional image showing the diverticulum. (c, d) Reconstructed T2-weighted MRI images showing relationship of urethral diverticulum with urinary bladder

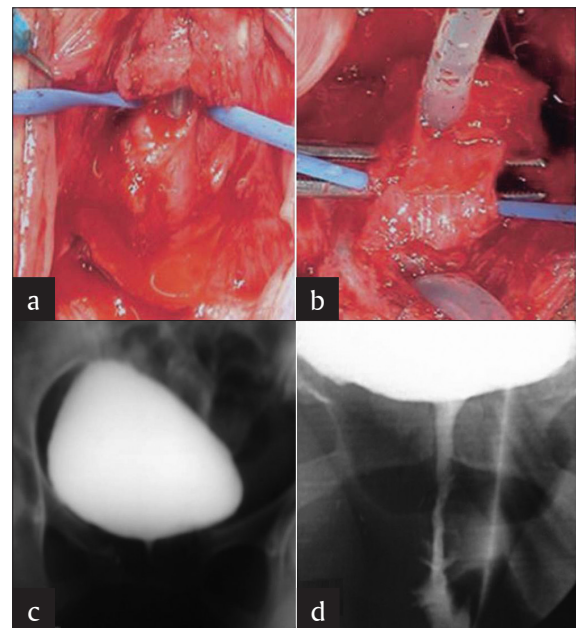


Figure 2: (a, b) Urethral defect after excision of the diverticulum. (c, d) Postoperative voiding cystourethrogram 3 weeks after surgery showing normal urethra

with a detrusor pressure at maximum measured flow rate of more than 20 cm H₂O in a pressure-flow study.^[7]

Strong clinical suspicion based on history, with focussed physical examination and appropriate radiological

investigations is vital for the diagnosis of UD. It should be differentiated from vaginal leiomyoma, Skene's gland cysts, and abscesses, Gartner's duct cysts, vaginal wall cysts, and ectopic ureterocele.^[1] Although transvaginal ultrasonography, VCUG, and positive pressure urethrography have traditionally been used in the diagnosis of UD, MRI is regarded as the investigation of choice by many with 100% reported sensitivity.^[8] Moreover, it is non-invasive, free from ionising radiations, does not depend on voiding of the patient and gives an excellent anatomical picture of the UD and adjacent pelvic structures. UDs appear as areas of decreased signal intensity on T1-weighted images compared with the surrounding soft tissues, and they have high signal intensity on T2-weighted images. Although endoluminal coil modalities have been described, surface coil non-contrast MRI is used in majority of the centers. Pre-operative video urodynamics is required in patients with symptomatic stress urinary incontinence and may delineate the UD under fluoroscopy in many cases.

Although very rare, malignant tumors, calculi and foreign bodies are to be ruled out in all cases of UD. In our patient, a broken catheter tip was recovered from the diverticular cavity.

Surgery is the mainstay of treatment for UD and surgical excision and urethral reconstruction remains the most popular modality though selected patients may be managed by transurethral or open marsupialisation. Total excision of the diverticulum, preservation of periurethral fascia, and watertight and tension-free closure with non-overlapping suture lines are vital for optimal surgical outcome. Simultaneous anti-incontinence surgery may be done in patients with symptomatic stress urinary incontinence.

REFERENCES

1. Rovner ES. Urethral Diverticula. In: Raz S, Rodriguez L, editors. Female Urology. 3rd ed. Philadelphia: Saunders; 2008. p. 815-34.
2. Glassman TA, Weinerth JL, Glenn JF. Neonatal female urethral diverticulum. *Urology* 1975;5:249-51.
3. MacKinnon M, Pratt JH, Pool T. Diverticulum of the female urethra. *Surg Clin North Am* 1959;39:953-62.
4. Pavlica P, Viglietta G, Losinno F, Veneziano S, Dalla Rovere S. I diverticoli dell'uretra femminile: Studio radiologico ed ecografico. *Radiol Med* 1988;75:521-7.
5. Shindo T, Nishida S, Maehana T, Miyamoto S, Muranaka T, Hisasue S, *et al.* Urinary retention caused by female urethral diverticulum. *Hinyokika Kyo* 2007;53:821-3.
6. Ganabathi K, Leach GE, Zimmern PE, Dmochowski R. Experience with the management of urethral diverticulum in 63 women. *J Urol* 1994;152:1445-52.
7. Groutz A, Blaivas JG, Chaikin DC. Bladder outlet obstruction in women: Definition and characteristics. *Neurourol Urodyn* 2000;19:213-20.
8. Ockrim J, Allen D, Shah P, Greenwell TJ. A tertiary experience of urethral diverticulectomy: Diagnosis, imaging and surgical outcomes. *BJU Int* 2009;103:1550-4.
9. Hoffman MJ, Adams WE. Recognition and repair of urethral diverticula: A report of 60 cases. *Am J Obstet Gynecol* 1965;92:106-11.
10. Kim B, Hricak H, Tanagho EA. Diagnosis of urethral diverticula in women: Value of MR imaging. *Am J Roentgenol* 1993;161:809-15.
11. Leach GE, Sirls LT, Ganabathi K, Zimmern PE. L N S C3: A proposed classification system for female urethral diverticula. *Neurourol Urodyn* 1993;12:523-31.
12. Thomas AA, Rackley RR, Lee U, Goldman HB, Vasavada SP, Hansel DE. Urethral Diverticula in 90 Female Patients: A Study with Emphasis on Neoplastic Alterations. *J Urol* 2008;180:2463-7.

How to cite this article: Pradhan MR, Ranjan P, Kapoor R. Female urethral diverticulum presenting with acute urinary retention: Reporting the largest diverticulum with review of literature. *Indian J Urol* 2012;28:216-8.

Source of Support: Nil, **Conflict of Interest:** None declared.