



Original Research

The Effect of Working Time and Application Technique on Cement Penetration into a Tibial Model

Thomas L. Schmicker, MD, MS^a, Akshay Goel, MD^{a,*}, Sarah Davis, MArch^b,
Syed Ali Sina Adil, MD^a, Ali Oliashirazi, MD^a, Matthew Bullock, DO, MPT^a

^a Department of Orthopaedic Surgery, Joan C. Edwards School of Medicine, Marshall University, Huntington, WV, USA

^b Snøhetta, New York, NY, USA

ARTICLE INFO

Article history:

Received 3 February 2022

Accepted 21 April 2022

Available online xxx

Keywords:

Arthroplasty

Loosening

Aseptic

Cement

Technique

Viscosity

ABSTRACT

Background: Aseptic loosening of the cemented tibial component is a source of failure in total knee arthroplasty. This study examined common techniques for cement application by quantifying depth and volume of penetration into tibia models.

Material and methods: Thirty-six composite tibia models were cemented with a tibial component using 3 application techniques (gun, osteotome, and layered) with either early or late cement working time. Computed tomography and 3D-modeling were used to quantify volume and depth of penetration. Statistical analysis was conducted with analysis of variance with Bonferroni correction and Student's *t*-test. **Results:** No difference was found in overall volume of penetration between early and late cement application ($P = .16$). Beneath the baseplate, the layered technique had significantly less penetration and averaged less than 3 mm with early and late cement. The gun technique had the greatest depth of penetration with early cement and averaged greater than 3 mm in all zones regardless of cement working time. The osteotome technique achieved significantly greater depth of penetration around the keel with early and late cement, $P < .01$.

Conclusions: Using a cement gun ensures adequate penetration beneath the baseplate regardless of cement working time while the osteotome technique is effective to increase penetration around the implant keel. According to our study, applying cement early in its working time may not increase volume of penetration. This study raises concern regarding adequate cement penetration using the layered technique for cementing the tibial component in total knee arthroplasty, and future research is warranted.

© 2022 The Authors. Published by Elsevier Inc. on behalf of The American Association of Hip and Knee Surgeons. This is an open access article under the CC BY-NC-ND license (<http://creativecommons.org/licenses/by-nc-nd/4.0/>).

Introduction

Total knee arthroplasty (TKA) is a successful procedure with high patient satisfaction. Studies have demonstrated the need for primary TKA is expected to rise 85% by 2030 [1–3]. Recent technological advances have helped broaden the indications of TKA to include younger and more active populations [4,5].

Despite TKA survival rates of 90% at 10, 15, and 30 years, the number of revision procedures is predicted to rise over the next

decade [1,2,6,7]. TKA failure may occur through several modes; however, studies have demonstrated aseptic loosening of the tibial component to be the most common cause of failure at 2 years, accounting for 29.8% of all revisions [8–13]. While there is ongoing interest in cementless fixation in TKA, so far, cemented fixation remains the gold standard [14]. The tibial component has been found to fail at the bone-cement interface due to shear and tensile forces along a poor cement mantle [9,12]. Cement penetration depth of at least 3 mm is considered optimal to resist micromotion, thus obtaining an adequate cement mantle appears integral for stability [15]. While it is generally accepted that cement should be applied to clean and dry bone, there is no consensus regarding the best cement application technique.

Described cementation techniques for TKAs include applying cement to the bone and implant before impaction (layered

* Corresponding author. Department of Orthopaedic Surgery, Joan C. Edwards School of Medicine, Marshall University, 1600 Medical Center Drive, Huntington, WV 25701, USA. Tel.: +1 304 691 1262.

E-mail address: akshaygimer@gmail.com

technique), finger-packing into the bone, and use of an osteotome or pressurized cement gun to compress and inject cement into the cancellous portion of bone, respectively [16,17–20]. Furthermore, the working viscosity of cement can vary depending on ambient room conditions, method of preparation, and manufacturer [21]. Cementing during the liquid phase improves pull-off strength of the tibial component, but the effect of depth of cement penetration is not clear [22–24].

This study aims to describe which cementation technique provides the most volume and depth of penetration into standardized proximal tibial models while using cement during the early vs late phases of working viscosity.

Material and methods

Thirty-six identical composite open-pore tibia models (Item SKU #1117-131; Sawbones, Malmo, Sweden) validated to mimic the structure of the proximal tibia were utilized for this study [25,26]. All models were prepared by the senior author to receive a size 3 tibial component (PFC Sigma; DePuy-Synthes, Warsaw, IN) using the extramedullary tibial cutting guide. The diaphysis of each model tibia was secured to a surgical table via a metal clamp. The inferior portion of the bone model rested on a supporting surface to ensure the proximal tibia remained perpendicular to the ground

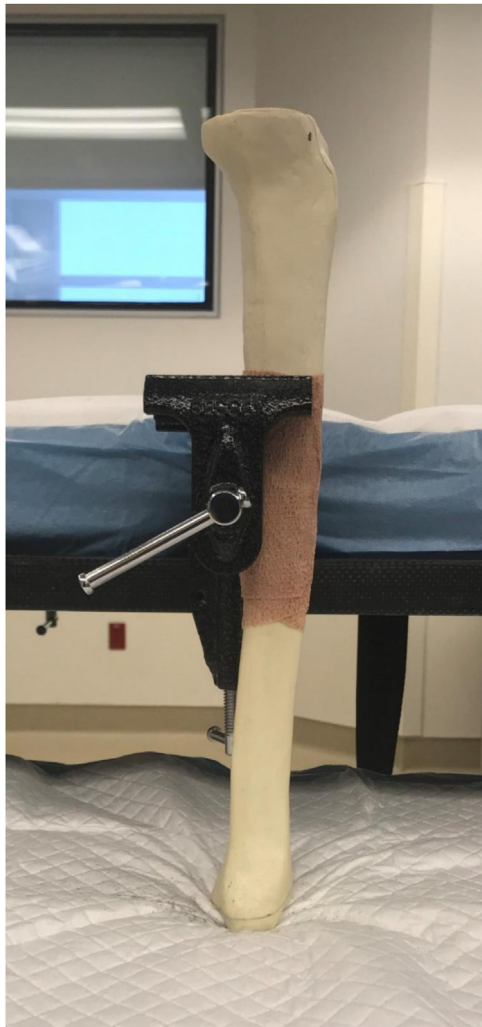

Figure 1. A photograph displaying the setup for cementation of the tibia models.

during testing (Fig. 1). This setup was used for all models during cementation and implantation of the component.

Forty grams of SMARTSET HP Medium Viscosity polymethyl methacrylate bone cement (DePuy Synthes, Warsaw, IN) was utilized for each tibia during this study. All cementation procedures were performed in a controlled environment with room temperature at 65°F and relative humidity at 55%. The cement was vacuum mixed as directed by the manufacturer. All cementation procedures were timed from the moment the activating agent was added to the cement powder until fully cured.

For the early liquid-phase group, the cement was mixed for 35 seconds, loaded into the cement gun, and applied immediately to the proximal tibia. Alternatively, for the late dough-phase group, the cement was mixed for 35 seconds, loaded into the cement gun, and application was then delayed 150 seconds. A thin layer of petroleum jelly was applied on the under surface of the baseplate to facilitate component removal without disturbing the cement mantle. We applied the early phase and late phase cement each to the 3 groups of 6 tibias using the 3 different techniques:

1. Layered: Cement is applied in equal parts to the proximal tibia and tibial component.
2. Osteotome: Cement is applied to the tibia bone, and an osteotome is used to compress the cement into the bone.
3. Gun: Cement is applied to tibia bone using a pressurized cement gun.

After manually placing the tibial component on the tibial surface, the corresponding secondary impactor was used to seat the component using firm mallet blows. Excess peripheral cement was carefully removed with a freer/elevator. Next, a 15-pound weight was placed on the tibial component while the cement cured. Afterwards, the manufacturer's extraction device was attached to the tibial component, and a single axial blow was used to remove the component without disrupting the newly formed cement mantle. Each specimen was then carefully removed from the table clamp and catalogued before being sent for a computed tomography scan. Three-dimensional reconstructions of the cement mantles were obtained and subsequently formatted using a software program (InVesalius; CTI, Brazil) for further analysis. A modelling software program (Rhinoceros; Robert McNeel & Associates, Seattle, WA) was used to characterize depth and volume of penetration (Fig. 2a).

In addition to the total volume of cement penetration for each specimen, 5 volumes of interest adjacent to the tibial baseplate in accordance with the Modern Knee Society Radiographic Evaluation System were evaluated for volume and depth of penetration [27] (Fig. 2b and c). Depth of penetration was defined as cement intrusion from the cut surface of the model into the open-pore composite.

An analysis of variance was used to evaluate all outcome measurements by the study group. The Student's *t*-test was then used to make individual mean comparisons. All *P* values were 2-tailed and considered significant at a *P* value < .05. The Bonferroni method was used to correct the *P* value for multiple comparisons. All analyses were performed using Strata 16.0 (College Station, TX).

Results

Of the 36 specimens used in the study, 35 were included in statistical analysis, with 1 discarded as an outlier from the early cement, layered technique group due to loss of vacuum during mixing.

Technique 1 (layered technique) consisted of equal parts of manual cement application to tibia surface and tibial component. When analyzing the mean cement penetration by different zones,

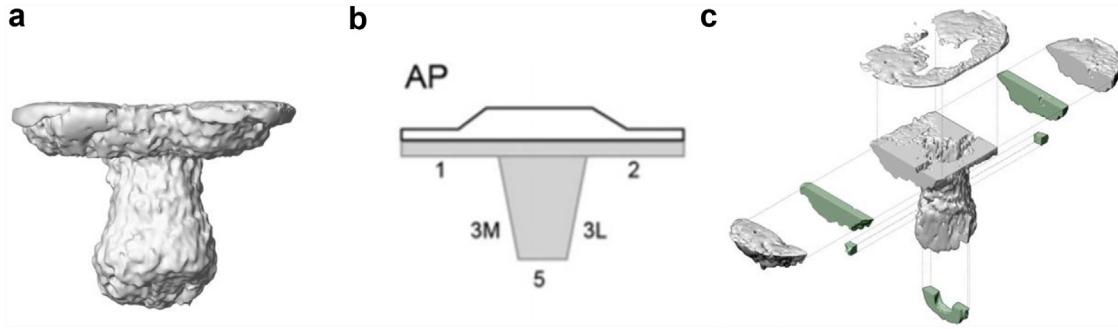


Figure 2. (a) An example of a three-dimensional reconstruction of the cement mantle. (b) Modern Knee Society Radiographic Evaluation system. (c) Exploded axonometric view of the cement mantle and volume of interest selected for evaluation corresponding with the Modern Knee Society Zones.

we found depth of cement penetration was lowest under the tibial base plate. For early cement, the mean values were 2.19 mm and 2.44 mm under the right and left baseplates, respectively. Similar values were also seen with late cement application (1.42 mm and 1.71 mm, respectively). The values averaged <3 mm with both techniques. Highest cement penetration was seen at the keel tip (mean depth of cement penetration of 5.45 mm and 4.31 mm for early and late cement application, respectively).

Technique 2 (osteotome technique) employed an osteotome to help compress the cement into the bone surface. We again found that the depth of penetration was lowest under the tibial baseplate and highest under the keel tip. However, we found higher depth of cement penetration under the right and left baseplates with the use of late cement application than with early cement application (mean depth of cement penetration of 2.19 mm and 2.98 mm, respectively, with early cement vs 3.72 mm and 3.63 mm, respectively, for late cement application).

Technique 3 (gun technique) utilized a pressurized cement gun to inject cement into the tibial surface. This technique showed highest cement penetration under the tibial baseplate. The mean cement penetration was also >3 mm in all zones irrespective of early or late cement application. Early cement application did have higher penetration under the right and left baseplates than late cement application (6.22 mm and 6.29 mm, respectively, with early cement vs 5.72 mm and 4.42 mm, respectively, for late cement application).

We observed no difference in the overall volume of cement penetration between early and late cement, 22,008.86 mm³ vs 19,125.23 mm³, respectively, $P = .16$ (Fig. 3). When comparing all the techniques, the osteotome technique resulted in the greatest overall volume of cement penetration, followed by cement gun and then the layered technique (Fig. 3). Beneath the baseplate, the layered technique achieved significantly less depth of penetration than gun and osteotome and averaged less than 3 mm with both early and late cement (Fig. 4). With early cement, the pressurized gun technique had the greatest depth of penetration from the tibial surface, $P < .05$, and averaged greater than 3 mm in all zones regardless of cement type. The osteotome group had significantly greater depth of penetration around the keel with early and late cement, $P < .01$.

Discussion

TKA is the gold standard for treatment of advanced arthritis of the knee. A projected increase in utilization of primary TKA makes it important to investigate and prevent causes for implant failure. According to studies, aseptic loosening of the tibial component is the number 1 cause for revision arthroplasty [8–12]. Therefore, limiting micromotion through optimal cementation technique may be a key to implant longevity. A minimal depth of 2-3 mm of cement intrusion has been described to reach the first transverse trabeculae and vertical channels to impart greater implant stability. A cement penetration depth >3 mm is thus considered optimal to

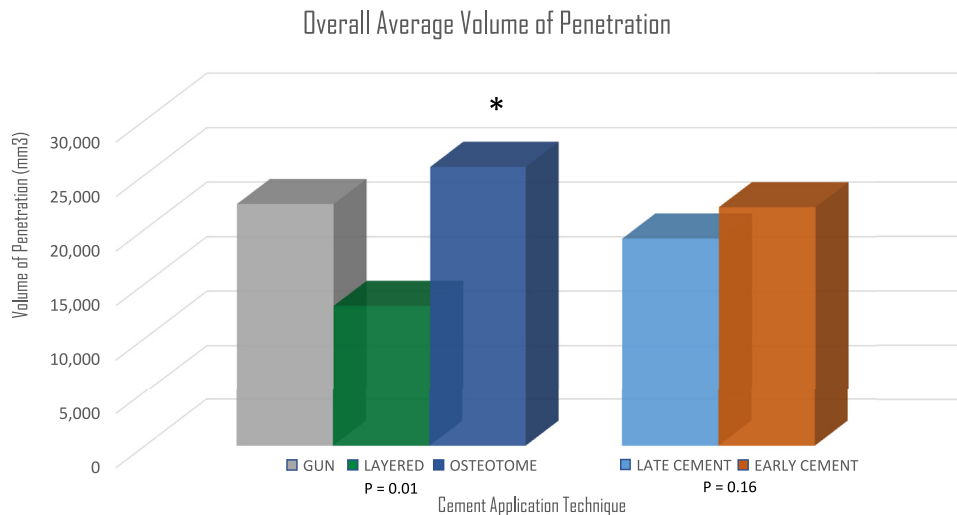


Figure 3. Mean cement penetration of the tibial model by technique and cement type.

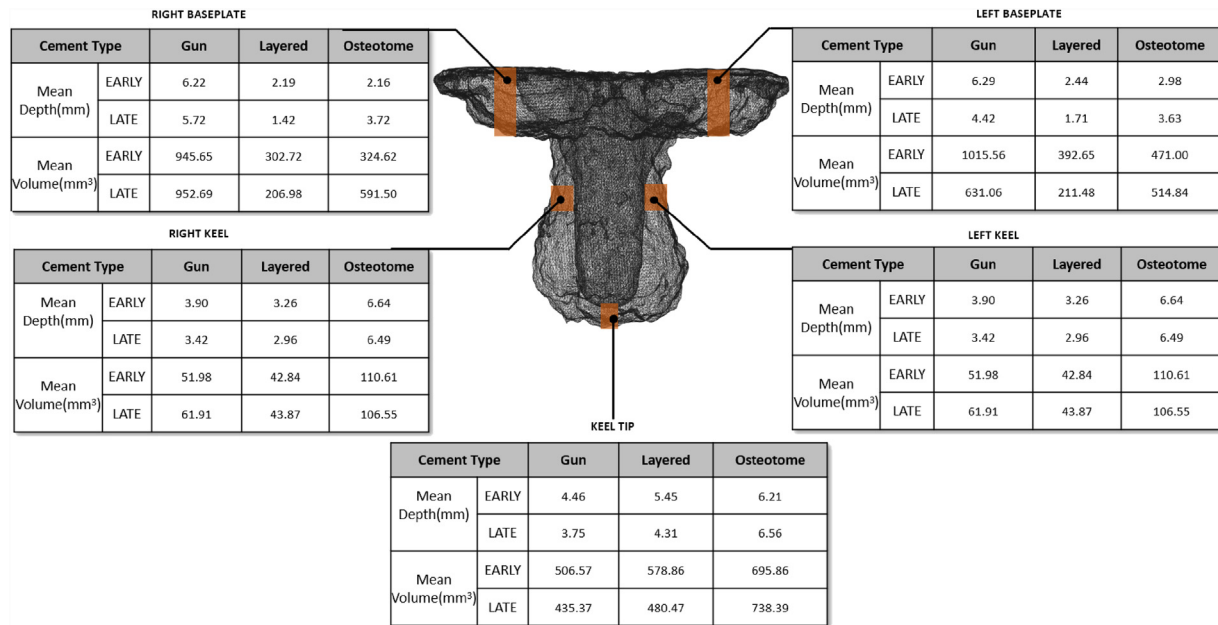


Figure 4. Mean cement volume and depth of penetration by volume of interest corresponding the Modern Knee Society Radiographic Evaluation system.

resist micromotion and appears integral for stability [15]. Meanwhile, penetration beyond 5 mm has been postulated to risk thermal necrosis to the surrounding bone [15,28]. Cement penetration has been previously described as proportional to bone pore diameter and the square root of applied pressure, while inversely proportional to time after initial cement mixing [20]. While bone permeability is nonmodifiable, no consensus exists on managing these other variables.

Studies have shown that liquid phase cement strengthens the bone-cement interface and may improve depth of intrusion [15,22–24]. In our study, the liquid phase early cement did not have significantly greater intrusion although our results did trend in this direction. Studies have described similar findings and have contended that increased intrusion during the liquid phase is secondary to using a closed system not found in vivo. Rather, intrusion may be secondary to the squeeze film effect that is present to a greater degree with higher viscosity cement [22–24]. The squeeze film effect is described as fluid pressure that is created when a viscous fluid is squeezed between 2 flat surfaces [22]. When a more viscous fluid is squeezed, greater pressure is created, thus increasing penetration into tibial bone [22]. In our study, the gun technique approximates a closed pressure system, and accordingly, the greatest depth of penetration beneath the baseplate in this study was achieved with the gun and early cement at greater than 6 mm. While the gun technique reached intrusion greater than the threshold of 5 mm, the osteotome and layered techniques both failed to achieve greater than 3 mm beneath the baseplate with early cement.

The layered technique consists of applying cement to the underside of the component and to the cut surface of the bone before impaction. The utility of this technique hinges on the concept that contamination of the implant-cement interface with marrow fat can decrease bonding strength [29]. The layered technique may limit any contamination to the cement-cement interface which, while still suboptimal, preserves some bond strength [29]. This technique has been examined with surface and full stem cementation. Billi et al. found that cementing the stem provides greater

initial strength of fixation than cementing only the tibial surface [29]. Hoffman et al. advocated that surface cementation is adequate, citing no revisions of the tibial component at 8 years [30]. In our study, the layered technique did not consistently provide 3 mm of penetration beneath the baseplate with either type of cement. Therefore, using only the layered technique may place implants at risk for future loosening.

With regard to cement application by the cement gun, our study showed that the mean penetration depth beneath the baseplate for both early and late phase cement was greater than that of both the osteotome and layered techniques. The cement gun also achieved greater than 3 mm of mean penetration with both early and late cement. Lutz et al. showed a mean depth of cement penetration of 5.0 mm when using a cement gun compared to a mean depth of 2.2 mm when using hand-packing [16]. Vanlommel et al. compared cementation by layer technique, layer with finger packing, and application by cement gun [31]. They demonstrated a mean penetration depth of 5.6 mm with the gun, which was significantly higher than that in other techniques [31].

Another finding of this study was the increased penetration around the stem of the implant when the osteotome technique was employed. Previous authors describe a <1% rate of loosening when employing this technique [32]. This difference existed when compared with both gun and layered techniques and persisted with both early and late cementation. Again, some authors contend that cementation of the stem provides no benefit in resisting micromotion if penetration beneath the implant is adequate at 3–5 mm [30,32,33]. Furthermore, arguments have been made that full cementation may result in greater bone loss at revision and cause stress shielding. On the other hand, advocates of full-cement technique point to evidence of a greater risk of implant loosening when employing a surface technique that begins at the keel and propagates to the entire surface of the tibia [34,19]. We believe that the osteotome technique increased penetration around the keel secondary to pressurizing cement placed in the area prepared for the keel.

This study is limited in that it is not a randomized controlled trial performed in an in vivo setting. The management of marrow fat and blood contamination, paramount in any TKA, cannot be

accurately simulated in a laboratory setting. Consensus dictates that cement should be applied to clean and dry bone, and extensive literature has been devoted to achieving that goal; the use of pulsed lavage, intraosseous suction, and compressed carbon dioxide have been described [14]. In addition, other intraoperative factors such as the use of a tourniquet may also play a role in cement penetration [35,36].

For our study, the cementing was completed in a controlled setting; however, variations in mixing temperature and humidity may have been present during cementation and may vary within the operating theater. Future directions should investigate cement mantles between implant manufacturers including both titanium and cobalt–chromium baseplates as well as different cement types.

While CT has been used to evaluate the cement mantle previously, our study is the first, to our knowledge, that quantifies the volume and depth of penetration at zones around the tibial baseplate [37]. Previous studies have mostly used radiographs and sectioned bones and models which have yielded 2-dimensional results. The use of CT allows improved characterization of the cement mantle.

Conclusions

Contrary to popular belief, the layered cementation technique may not provide the best depth of penetration when cementing the tibial component. According to our tibia model study, employing a pressurized cement gun ensures cement penetration >3 mm beneath the baseplate regardless of cement working time while the osteotome technique ensures increased cement penetration around the keel of the tibial baseplate. Interestingly, based on our study, applying cement early in its working time may not increase volume of penetration. Future studies are needed to investigate differences in cement type, implant designs, and most importantly within the operating room setting.

Acknowledgments

The authors would like to recognize Todd Gress, MD, MPH, Madhav Chowdhry MBBS, and Nicole Oliashirazi for their help during testing, data collection, and analysis.

Funding

This work was supported by funding from DePuy Synthes; Marshall University School of Medicine Appalachian Clinical and Translational Science Institute (ACTSI); National Institute of General Medical Sciences of the National Institutes of Health (NIH) under Award Number P20GM121299-01A1. The content is solely the responsibility of the authors and does not necessarily represent the official views of the NIH or ACTSI.

Conflicts of interest

The authors declare the following financial interests/personal relationships which may be considered as potential competing interests:

A. Oliashirazi is in the speakers' bureau of or gave paid presentations for DePuy Synthes and Zimmer; is a paid consultant for DePuy Synthes and Zimmer; and receives research support as a principal investigator from DePuy Synthes. A. Goel is a member of the OTA Video Library Committee and is a reviewer for *Arthroplasty Today*, not involved in the peer review process for this manuscript. T. L. Schmicker received a grant from DePuy Synthes for this work. M. Bullock is in the speakers' bureau of or gave paid presentations for Smith & Nephew; is a paid consultant for Smith & Nephew; is an

unpaid consultant for Osso VR; has stock or stock options in Stryker; receives educational support from Stryker, Smith & Nephew, Zimmer Biomet, and DePuy; is in the editorial board of *Arthroplasty Today*, not involved in the peer review process for this manuscript; is in the AAHKS Patient Education Committee and in the West Virginia Orthopaedic Society Education Committee.

For full disclosure statements refer to <https://doi.org/10.1016/j.artd.2022.04.011>.

Informed patient consent

The author(s) confirm that informed consent has been obtained from the involved patient(s) or if appropriate from the parent, guardian, power of attorney of the involved patient(s); and, they have given approval for this information to be published in this case report (series).

References

- [1] Abdeen AR, Collen SR, Vince KG. Fifteen-year to 19-year follow-up of the Insall-Burstein-1 total knee arthroplasty. *J Arthroplasty* 2010;25:173–178.
- [2] Abdel MP, Morrey ME, Jensen MR, Morrey BF. Increased long-term survival of posterior cruciate-retaining versus posterior cruciate-stabilizing total knee replacements. *J Bone Joint Surg Am* 2011;93:2072–2078.
- [3] Sloan M, Premkumar A, Sheth NP. Projected volume of primary total joint arthroplasty in the U.S., 2014 to 2030. *J Bone Joint Surg Am* 2018;100:1455–1460.
- [4] Engh GA. Advances in knee arthroplasty for younger patients: traditional knee arthroplasty is prologue, the future for knee arthroplasty is prescient. *Orthopedics* 2007;30(8 Suppl):55–57.
- [5] Heyse TJ, Ries MD, Bellemans J, Goodman SB, Scott RD, Wright TM, et al. Total knee arthroplasty in patients with juvenile idiopathic arthritis. *Clin Orthop Relat Res* 2014;472:147–154.
- [6] Klug A, Gramlich Y, Rudert M, Drees P, Hoffmann R, Weißenberger M, et al. The projected volume of primary and revision total knee arthroplasty will place an immense burden on future health care systems over the next 30 years. *Knee Surg Sports Traumatol Arthrosc* 2021;29:3287–3298.
- [7] Long WJ, Bryce CD, Hollenbeak CS, Benner RW, Scott WN. Total knee replacement in young, active patients: long-term follow-up and functional outcome: a concise follow-up of a previous report. *J Bone Joint Surg Am* 2014;96:e159.
- [8] Sharkey PF, Lichstein PM, Shen C, Tokarski AT, Parvizi J. Why are total knee arthroplasties failing today—has anything changed after 10 years? *J Arthroplasty* 2014;29:1774–1778.
- [9] Postler A, Lutzner C, Beyer F, Tille E, Lutzner J. Analysis of total knee arthroplasty revision causes. *BMC Musculoskelet Disord* 2018;19:55.
- [10] Khan M, Osman K, Green G, Haddad FS. The epidemiology of failure in total knee arthroplasty: avoiding your next revision. *Bone Joint J* 2016;98-B(1 Suppl A):105–112.
- [11] Lombardi AV Jr, Berend KR, Adams JB. Why knee replacements fail in 2013: patient, surgeon, or implant? *Bone Joint J* 2014;96-B(11 Suppl A):101–104.
- [12] Hampton CB, Berliner ZP, Nguyen JT, Mendez L, Smith SS, Joseph AD, et al. Aseptic loosening at the tibia in total knee arthroplasty: a function of cement mantle quality? *J Arthroplasty* 2020;35(6S):S190–S196.
- [13] Thiele K, Perka K, Matziolis G, Mayr H, Sostheim M, Hube R. Current failure mechanisms after knee arthroplasty have changed: polyethylene wear is less common in revision surgery. *J Bone Joint Surg Am* 2015;97:715–720.
- [14] Gandhi R, Tsvetkov D, Davey JR, Mahomed NN. Survival and clinical function of cemented and uncemented prostheses in total knee replacement: a meta-analysis. *J Bone Joint Surg Br* 2009;91:889–895.
- [15] Walker PS, Soudry M, Ewald FC, McVicker H. Control of cement penetration in total knee arthroplasty. *Clin Orthop Relat Res* 1984;185:155–164.
- [16] Lutz MJ, Pincus PF, Whitehouse SL, Halliday BR. The effect of cement gun and cement syringe use on the tibial cement mantle in total knee arthroplasty. *J Arthroplasty* 2009;24:461–467.
- [17] Park SH, Silva M, Park JS, Ebramzadeh E, Schmalzried TP. Cement-cement interface strength: influence of time to apposition. *J Biomed Mater Res* 2001;58:741–746.
- [18] Ko DO, Lee S, Kim KT, Lee JI, Kim JW, Yi SM. Cement mantle thickness at the bone cement interface in total knee arthroplasty: comparison of PS150 RP and LPS-flex knee implants. *Knee Surg Relat Res* 2017;29:115–121.
- [19] Cawley DT, Kelly N, McGarry JP, Shannon FJ. Cementing techniques for the tibial component in primary total knee replacement. *Bone Joint J* 2013;95-B:295–300.
- [20] Kopec M, Milbrandt JC, Duellman T, Mangan D, Allan DG. Effect of hand packing versus cement gun pressurization on cement mantle in total knee arthroplasty. *Can J Surg* 2009;52:490–494.
- [21] Meyer PR Jr, Lautenschlager EP, Moore BK. On the setting properties of acrylic bone cement. *J Bone Joint Surg Am* 1973;55:149–156.

- [22] Silverman EJ, Landy DC, Massel DH, Kaimrajh DN, Latta LL, Robinson RP. The effect of viscosity on cement penetration in total knee arthroplasty, an application of the squeeze film effect. *J Arthroplasty* 2014;29:2039–2042.
- [23] Kopec M, Milbrandt JC, Kohut N, Kern B, Allan DG. Effect of bone cement viscosity and set time on mantle area in total knee arthroplasty. *Am J Orthop (Belle Mead NJ)* 2009;38:519–522.
- [24] Breusch S, Heisel C, Müller J, Borchers T, Mau H. Influence of cement viscosity on cement interdigitation and venous fat content under in vivo conditions: a bilateral study of 13 sheep. *Acta Orthop Scand* 2002;73:409–415.
- [25] Elfar J, Menorca RM, Reed JD, Stanbury S. Composite bone models in orthopaedic surgery research and education. *J Am Acad Orthop Surg* 2014;22:111–120.
- [26] Cristofolini L, Viceconti M. Mechanical validation of whole bone composite tibia models. *J Biomech* 2000;33:279–288.
- [27] Meneghini RM, Mont MA, Backstein DB, Bourne RB, Dennis DA, Scuderi GR. Development of a modern knee society radiographic evaluation system and methodology for total knee arthroplasty. *J Arthroplasty* 2015;30:2311–2314.
- [28] Vertullo CJ, Zbrojkiewicz D, Vizesi F, Walsh WR. Thermal analysis of the tibial cement interface with modern cementing technique. *Open Orthop J* 2016;10:19–25.
- [29] Billi F, Kavanaugh A, Schmalzried H, Schmalzried TP. Techniques for improving the initial strength of the tibial tray-cement interface bond. *Bone Joint J* 2019;101 B(1_Supple_A):53–58.
- [30] Hofmann AA, Goldberg TD, Tanner AM, Cook TM. Surface cementation of stemmed tibial components in primary total knee arthroplasty: minimum 5-year follow-up. *J Arthroplasty* 2006;21:353–357.
- [31] Vanlommel J, Luyckx JP, Labey L, Innocenti B, De Corte R, Bellemans J. Cementing the tibial component in total knee arthroplasty: which technique is the best? *J Arthroplasty* 2011;26:492–496.
- [32] Randall DJ, Anderson MB, Gililland JM, Peters CL, Pelt CE. A potential need for surgeon consensus: cementation techniques for total knee arthroplasty in orthopedic implant manufacturers' guidelines lack consistency. *J Orthop Surg (Hong Kong)* 2019;27: 2309499019878258.
- [33] Peters CL, Craig MA, Mohr RA, Bachus KN. Tibial component fixation with cement: full- versus surface-cementation techniques. *Clin Orthop Relat Res* 2003;409:158–168.
- [34] Lionberger D, Wattenbarger L, Conlon C, Walker TJ. Factors affecting aseptic loosening in primary total knee replacements: an in vitro study. *J Exp Orthop* 2020;7:41.
- [35] Hegde V, Bracey DN, Johnson RM, Dennis DA, Jennings JM. Tourniquet use improves cement penetration and reduces radiolucent line progression at 5 Years after total knee arthroplasty. *J Arthroplasty* 2021;36(7S):S209–S214.
- [36] Matthews JJ, Ball L, Blake SM, Cox PJ. Combined syringe cement pressurisation and intra-osseous suction: an effective technique in total knee arthroplasty. *Acta Orthop Belg* 2009;75:637–641.
- [37] Schlegel UJ, Bishop NE, Püschel K, Morlock MM, Nagel K. Comparison of different cement application techniques for tibial component fixation in TKA. *Int Orthop* 2015;39:47–54.