

Cardiac tamponade during thoracic endovascular aortic repair

Radhouane Bousselmi, Anis Lebbi, Nazih Chaouech¹, Mustapha Ferjani

Department of Anesthesia and Critical Care, ¹Department of Vascular Surgery, Military Hospital, Faculty of Medicine, Tunis, Tunisia

Thoracic endovascular aortic repair (TEVAR) is still associated with complications which include mortality in 7.3% of cases. In this report, we describe the case of a man with a pseudoaneurysm of the aortic isthmus that was scheduled to undergo endovascular repair. During the procedure, the patient had a sudden cardiac arrest due to a compressive hemopericardium caused by perforation of the ascending aorta. The diagnosis was not clear and was made by transthoracic echocardiography after five minutes of resuscitation. In spite of the evacuation of the hemopericardium and suture of the perforation, the patient died. The diagnosis would have been easier and faster if the patient had been monitored continuously by transesophageal echocardiography during the procedure.

Key words: Cardiac arrest, endovascular procedures, hemopericardium, pseudoaneurysm, thoracic aorta

How to cite this article: Bousselmi R, Lebbi A, Chaouech N, Ferjani M. Cardiac tamponade during thoracic endovascular aortic repair. *J Res Med Sci* 2014;19:571-3.

INTRODUCTION

Since its approval by the Food and Drug Administration in 2005, the thoracic endovascular aortic repair (TEVAR) is performed increasingly worldwide. The mid- to long-term outcomes of this technique seem to be encouraging.^[1] Nevertheless, TEVAR is still associated with several major complications that cause death in about 7.3% of cases.^[1] In this report, we describe a case of compressive hemopericardium that occurred during thoracic endovascular aneurysm repair in a 56-year-old patient.

CASE REPORT

A 56-year-old man presented with a post-traumatic pseudoaneurysm of the aortic isthmus. The patient did not have any other medical history. He suffered from mild intermittent chest pain and exertional dyspnea. On physical examination, he did not show any abnormality. The electrocardiogram (ECG) and the transthoracic echocardiography were normal. Computed tomography showed a nonthrombosed pseudoaneurysm of the aortic isthmus with 37 mm of long axis and 10 mm of collar diameter. The vascular surgery team proposed an endovascular repair of the pseudoaneurysm and the patient consented to undergo it.

The TEVAR procedure was performed in the operating room under general anesthesia with tracheal intubation and standard monitoring. The procedure started

with a guidewire insertion from the left brachial artery to localize the left subclavian artery. Then, the right femoral artery was catheterized to insert the aortic endograft. Thus, a guidewire was inserted into the horizontal aorta and a self-expanding covered stent graft was inserted over it (Talent graft; Medtronic World Medical, Sunrise, Florida). The surgeon did not report any resistance during the insertion of the guidewire and endograft. The patient's vital parameters were within normal ranges. Just before the stent graft deployment, the patient had an abrupt cardiac arrest with electromechanical dissociation. There was a jugular turgor but no skin pallor. External cardiac massage was immediately started, and the patient recovered spontaneous cardiac activity five minutes later, after receiving 1 mg epinephrine intravenously. A continuous infusion of epinephrine was started, and a transthoracic echocardiography was immediately performed and it showed an abundant pericardial effusion [Figure 1]. The sternum was incised to evacuate the pericardium. During incision, the patient presented an asystolic cardiac arrest. The hemopericardium was evacuated and internal cardiac massage started. Surgical exploration found a perforation of the ascending aorta and a rupture of the pseudoaneurysm. The internal cardiac massage was maintained and volume expansion was done by colloids and four packed red blood cells. The ascending aorta perforation was sutured, but the surgeons did not succeed in suturing the pseudoaneurysm rupture. After 90 minutes of resuscitation, the patient did not

Address for correspondence: Dr. Radhouane Bousselmi, 15 Avenue de la République, Bardo, 2000, Tunisia. E-mail: rdh.bousselmi@gmail.com

Received: 26-05-2013; **Revised:** 04-07-2013; **Accepted:** 14-07-2013

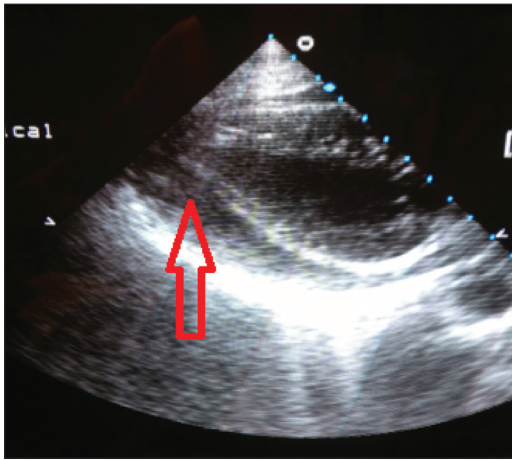


Figure 1: Transthoracic echocardiography showing the pericardial effusion (arrow)

recover spontaneous cardiac activity. Due to lack of the availability of an extracorporeal circulatory support system, resuscitation was discontinued and death was declared.

DISCUSSION

Endovascular surgery for thoracic aorta diseases is emerging as a less invasive approach than open surgery.^[1,2] The effectiveness of this technique in thoracic aortic aneurysms is now well recognized.^[2,3] However, it is still associated with about 25% complications which include mortality, vascular injuries, spinal cord ischemia, and cerebrovascular events.^[1] Perioperative mortality is seen in 2.6% of the patients.^[3] It is mostly related to thoracic aorta rupture.^[3]

In our patient, cardiac arrest was related to a compressive hemopericardium that occurred after the perforation of the ascending aorta. This perforation was probably caused by the guidewire inserted from the right femoral artery and pushed into the horizontal aorta. This guidewire was probably pushed into the ascending aorta during the insertion of the stent graft and caused its perforation. At first, the patient recovered spontaneous cardiac activity after five minutes of resuscitation. The diagnosis of hemopericardium was made by echocardiography a few minutes later and sternotomy was immediately performed to evacuate the pericardial effusion and treat the perforation. Unfortunately, pseudoaneurysm rupture occurred and it was probably induced by external cardiac massage. The patient had a second cardiac arrest and resuscitation failed to retrieve a spontaneous cardiac activity.

A search for 'TEVAR' and 'hemopericardium' in the Medline database did not reveal any previous report of

compressive hemopericardium after thoracic endovascular aneurysm repair. However, there were eight reports of compressive hemopericardium during percutaneous coronary interventions.^[4-11] The clinical presentation was mostly a hemodynamic instability. There were no cases of abrupt cardiac arrest. The diagnosis of compressive hemopericardium was made by echocardiography in all the cases. Surgical evacuation was performed in four cases and pericardiocentesis in three other cases. Death was reported only in one patient.^[8]

The present case is, to our knowledge, the first case report of compressive hemopericardium after TEVAR. This potential complication should be kept in mind during thoracic endovascular procedures. It should be immediately suspected in case of hemodynamic instability or cardiac arrest during TEVAR procedures, especially if associated with jugular turgor or electromechanical dissociation. The absence of skin pallor strengthens the suspicion and eliminates the diagnosis of hemorrhagic shock. Finally, periprocedural monitoring with transesophageal echocardiography should be considered during TEVAR to timely detect such complications and take suitable action.^[12] In fact, in our case, if the diagnosis was made immediately after the first cardiac arrest, external cardiac massage could have been avoided and sternotomy performed first. This would have avoided the pseudoaneurysm rupture.

AUTHOR'S CONTRIBUTIONS

Bousselmi R, Lebbi A and Chaouech N: Data acquisition, analysis and interpretation. Bousselmi R, Lebbi A and Chaouech N: Manuscript drafting. Ferjani M: Manuscript revision. Bousselmi R, Lebbi A, Chaouech N and Ferjani M: Final approval of the version to be published. All authors (Bousselmi R, Lebbi A, Chaouech N and Ferjani M) agree to be accountable for all aspects of the work in ensuring that questions related to the accuracy or integrity of any part of the work are appropriately investigated and resolved.

REFERENCES

1. Bhamidipati CM, LaPar DJ, Mehta GS, Kern JA, Kron IL, Upchurch GR Jr, *et al.* Have thoracic endografting outcomes improved since US Food and Drug Administration approval. *Ann Thorac Surg* 2011;91:1314-22.
2. Wiedemann D, Mahr S, Vadehra A, Schoder M, Funovics M, Löwe C, *et al.* Thoracic endovascular aortic repair in 300 patients: Long-term results. *Ann Thorac Surg* 2013;95:1577-83.
3. Desai ND, Burtch K, Moser W, Moeller P, Szeto WY, Pochettino A, *et al.* Long-term comparison of thoracic endovascular aortic repair (TEVAR) to open surgery for the treatment of thoracic aortic aneurysms. *J Thorac Cardiovasc Surg* 2012;144:604-9.
4. Dardas PS, Tsikaderis DD, Makriganakis K, Saripoulos P, Toumbouras M. Complete left atrial obliteration due to localized

- tamponade after coronary artery perforation during PTCA. *Cathet Cardiovasc Diagn* 1998;45:61-3.
5. Kadner A, Chen RH, Collard CD, Adams DH. Isolated left atrial tamponade following circumflex artery angioplasty. *Heart* 2000;84:514.
 6. Steiner MA, Marshall JJ. Coronary sinus compression as a sign of cardiac tamponade. *Catheter Cardiovasc Interv* 2000;49:455-8.
 7. Kawase Y, Hayase M, Ito S, Ojio S, Tahara H, Ehara M, *et al.* Compression of right ventricular out-flow due to localized hematoma after coronary perforation during PCI. *Catheter Cardiovasc Interv* 2003;58:202-6.
 8. Quan VH, Stone JR, Couper GS, Rogers C. Coronary artery perforation by cutting balloon resulting in dissecting subepicardial hematoma and avulsion of the vasculature. *Catheter Cardiovasc Interv* 2005;64:163-8.
 9. Barbeau GR, Senechal M, Voisine P. Delayed abrupt tamponade by isolated left atrial compression following coronary artery perforation during coronary angioplasty. *Catheter Cardiovasc Interv* 2005;66:562-5.
 10. Koch KC, Graf J, Hanrath P. Images in cardiology. Left atrial obliteration after coronary artery perforation. *Heart* 2006;92:238.
 11. Tavano D, Carlino M, Pisani M, Colombo A. Images in cardiovascular medicine. Conservative treatment of a left atrial hematoma and a localized tamponade occurring during treatment of coronary total occlusion. *Circulation* 2007;115:e603-6.
 12. Sullivan B, Puskas F, Fernandez-Bustamante A. Transesophageal echocardiography in noncardiac thoracic surgery. *Anesthesiol Clin* 2012;30:657-69.

Source of Support: Nil, **Conflict of Interest:** None declared.