

[ CASE REPORT ]

## Negative-pressure pulmonary Hemorrhaging Due to Severe Obstructive Sleep Apnea

Kenya Kuramoto<sup>1</sup>, Masashi Matsuyama<sup>1</sup>, Mizu Nonaka<sup>1</sup>, Takahiro Takeishi<sup>1</sup>, Hisayuki Oshima<sup>1</sup>, Sosuke Matsumura<sup>1</sup>, Masayuki Nakajima<sup>1</sup>, Chio Sakai<sup>1</sup>, Toshihiro Shiozawa<sup>1</sup>, Takumi Kiwamoto<sup>1</sup>, Yuko Tsukahara<sup>2</sup>, Norio Takayashiki<sup>3</sup>, Ryoko Ogawa<sup>1</sup>, Yuko Morishima<sup>1</sup>, Masayuki Noguchi<sup>3</sup> and Nobuyuki Hizawa<sup>1</sup>

### Abstract:

A 24-year-old man with a history of bloody sputum for 6 months was referred to our hospital with suspected alveolar hemorrhaging due to vasculitis. Chest computed tomography showed ground-glass opacities in both lungs, and an examination of his bronchoalveolar lavage fluid showed alveolar hemorrhaging. However, no evidence of vasculitis was found, and subsequent polysomnographic testing confirmed that he had severe obstructive sleep apnea (OSA). Since the alveolar hemorrhaging improved after the initiation of continuous positive airway pressure treatment, the diagnosis was negative-pressure alveolar hemorrhaging due to severe OSA.

**Key words:** negative-pressure pulmonary edema (NPPE), negative-pressure pulmonary hemorrhaging (NPPH), obstructive sleep apnea (OSA), continuous positive airway pressure (CPAP) treatment, polysomnography

(Intern Med 60: 2291-2296, 2021)

(DOI: 10.2169/internalmedicine.6206-20)

### Introduction

Negative-pressure pulmonary edema (NPPE) is a form of noncardiogenic pulmonary edema that results from the generation of high negative intrathoracic pressure to overcome upper airway obstruction, such as choking and laryngospasm after extubation or in the postoperative period after anesthesia (1-5). However, only a few reports have shown NPPE as a result of upper airway obstruction due to obstructive sleep apnea (OSA) (6-8).

In addition, pulmonary hemorrhaging associated with NPPE, called negative-pressure pulmonary hemorrhaging (NPPH), also occurs very rarely (1, 9-11). The etiology of NPPH is thought to be stress failure, which is the mechanical disruption of the alveolar-capillary membrane due to high negative intrathoracic pressure (1, 12).

We herein report an adult who developed alveolar hemor-

rhaging following severe OSA. To our knowledge, this is the first case of NPPH due to severe OSA. A device for electronically predicting pleural pressure from pulse wave signals, which was developed as a sleep evaluation device in Japan, was useful for measuring the intrathoracic pressure and making a definite diagnosis of NPPH in this case.

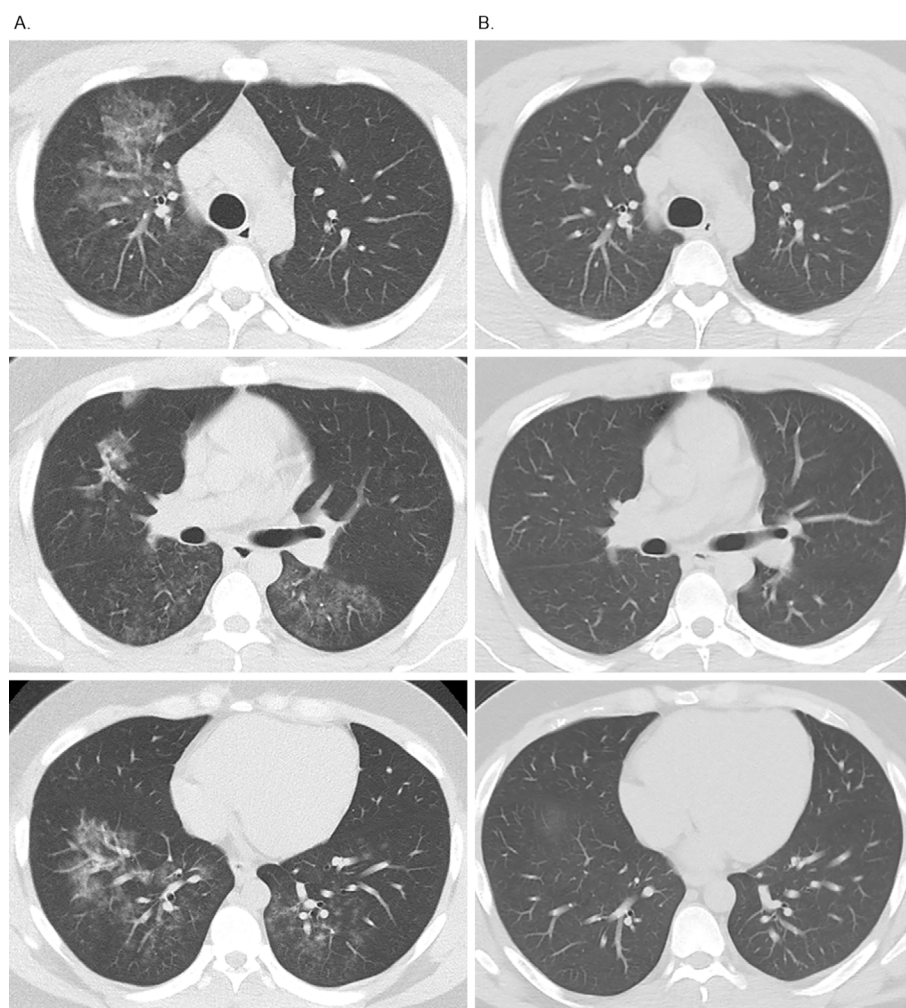
### Case Report

A 24-year-old man was referred to our hospital with a 6-month history of bloody sputum. Bloody sputum was particularly obvious at the time of awakening, and it decreased during the day. A local physician suspected alveolar hemorrhaging due to vasculitis because of an infiltrative shadow in the lower right lung field on chest X-ray and proteinuria. There was no significant medical history, with no bronchial asthma or coagulation disorder and no relevant family history. He was a social drinker and a never smoker. In addi-

<sup>1</sup>Department of Respiratory Medicine, Institute of Clinical Medicine, University of Tsukuba, Japan, <sup>2</sup>Fukuda Life Tech Joyo Co., Ltd., Japan and <sup>3</sup>Department of Pathology, Faculty of Medicine, University of Tsukuba, Japan

Received: September 2, 2020; Accepted: January 6, 2021; Advance Publication by J-STAGE: February 22, 2021

Correspondence to Dr. Masashi Matsuyama, mmatsuyama@md.tsukuba.ac.jp



**Figure 1.** (A) High-resolution computed tomography (CT) of the chest before starting treatment for OSA with continuous positive airway pressure (CPAP) shows bilateral ground-glass opacities (right>left). (B) High-resolution CT of the chest shows that bilateral ground-glass opacities had disappeared by two months after CPAP treatment.

tion, he had never been prescribed an anticoagulant.

A physical examination showed obesity, with a high body mass index (BMI) of 34 kg/m<sup>2</sup>, a short chin, and a thick neck. Blood tests showed slight liver dysfunction with an increased level of aspartate transaminase (AST) at 40 U/L and alanine transaminase (ALT) at 80 U/L. Abdominal computed tomography (CT) showed fatty liver. Blood tests did not show any coagulation abnormality (PT: 10.5 s, PT-INR: 0.88, APTT: 30.8 s, fibrinogen: 257 mg/dL, FDP: 1.7 µg/mL). Antinuclear antibodies were negative. A work-up for vasculitis, including proteinase-3 anti-neutrophil cytoplasmic antibody (PR3-ANCA), myeloperoxidase anti-neutrophil cytoplasmic antibody (MPO-ANCA), and glomerular basement membrane (GPM) antibody was negative. Serum levels of Krebs von den Lungen 6 (KL-6) and N-terminal pro-B-type natriuretic peptide (NT-proBNP) were 558 U/mL and 10.7 pg/mL, respectively. A urinalysis on admission showed no abnormalities. The pulmonary function test findings were %VC 83.3% and FEV1.0% 86.3%, indicating a slight decrease in VC, probably due to obesity.

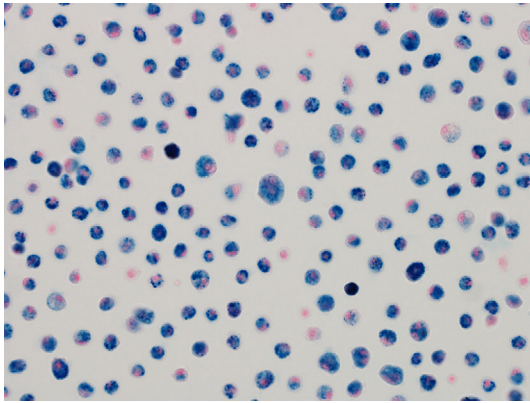
High-resolution chest CT showed bilateral ground-glass

opacities (right>left) (Fig. 1A), indicating the presence of alveolar hemorrhaging or inhalation of bloody sputum. Bronchoscopy was performed, which showed no abnormal findings in the bronchial lumen, whereas bronchoalveolar lavage fluid (BALF) recovered from the right middle lobe was mildly bloody. A cytopathological evaluation of the BALF sample showed numerous hemosiderin pigment-laden macrophages (Fig. 2). Gram stain and culture results, including those for mycobacterial infection, were negative, and there were no malignant cells on cytology. Echocardiography showed a normal heart function.

The patient had bloody sputum only in the morning, especially when he woke up, and he also had daytime sleepiness and severe snoring during sleep. Therefore, suspecting negative-pressure pulmonary alveolar hemorrhaging due to OSA, polysomnography was performed, which showed severe OSA with an apnea hypopnea index (AHI) of 93.8, as shown in Table.

When continuous positive airway pressure (CPAP) treatment was started, both the bloody sputum and daytime sleepiness gradually disappeared. The Epworth sleepiness

scale scores before and one month after CPAP treatment were 15 and 3, respectively. Chest radiography one month after CPAP treatment showed remarkable improvement (Fig. 3). On chest CT two months after starting CPAP treatment, bilateral ground-glass opacities (right>left) had also totally disappeared (Fig. 1B). A portable device for sleep apnea syndrome testing (type-3 out-of-center sleep test) in which a specific technology (US Patent No. 6,669,632 B2) had been installed showed that the respiratory event index



**Figure 2.** Hemosiderin-laden macrophages with positive staining for iron (Berlin blue) in the bronchoalveolar lavage fluid ( $\times 400$ ).

(REI) was 77.5 without CPAP treatment and 1.4 with CPAP treatment (Fig. 4, 5). The approximate intrathoracic pressure was also estimated using this portable device to electronically predict the pleural pressure from pulse wave signals (Fig. 5). Results from the device showed that changes in the intrathoracic pressure were significantly larger without CPAP treatment, but the changes decreased dramatically with CPAP treatment (closed arrow in Fig. 5).

Given the above, a diagnosis of NPPH due to severe OSA was made.

## Discussion

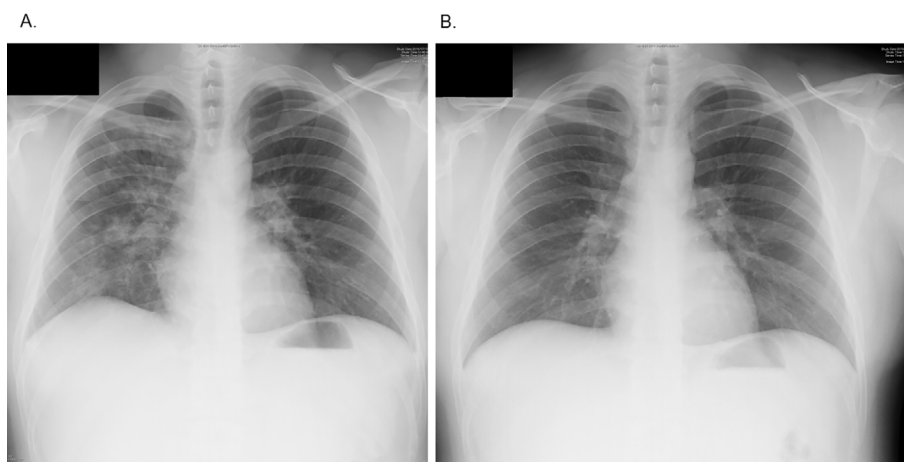
The first case of a patient with NPPH due to severe OSA was reported. NPPE is caused by excessive negative pleural pressure due to inspiratory effort during upper airway obstruction. The most common cause of NPPE is laryngeal spasm after extubation (2, 3), epilepsy, and choking due to aspiration (4, 12, 13), but few cases of NPPE caused by sleep apnea have been reported.

Alveolar hemorrhaging due to rupture of the alveoli-capillary membrane secondary to NPPE is called NPPH, and it is known to occur in 5% of NPPE cases (2). The present patient was a young, athletic man (he used to play baseball), which is a description similar to a previously reported case of NPPH (12), indicating that strong respiratory muscle

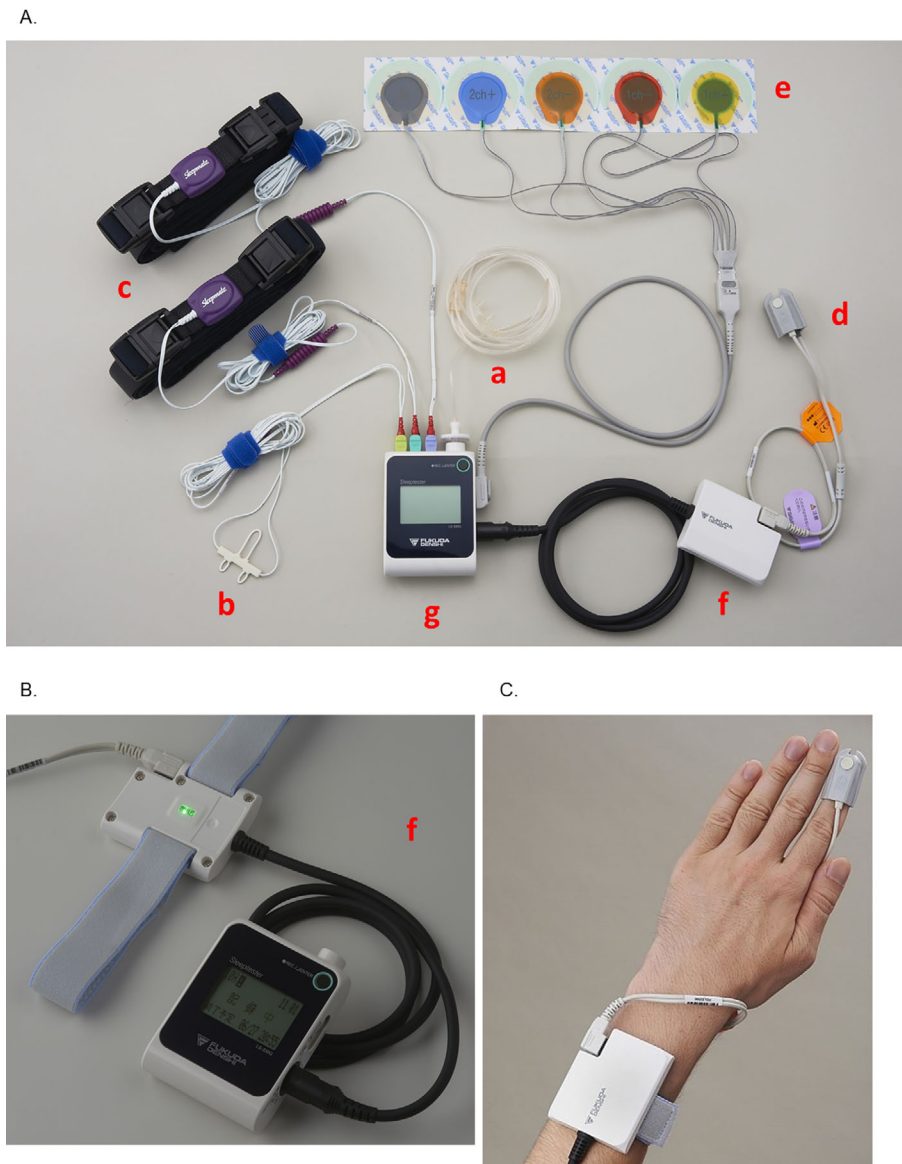
**Table.** Sleep Study Data of This Case before CPAP Treatment.

AHI (h)	AI (h)	CA (h)	OA (h)	MA (h)	Arousal index (h)	NREM stage 1 (%)	NREM stage 2 (%)	NREM stage 3 (%)	REM sleep (%)	3% ODI (h)	SpO <sub>2</sub> <90 % time (min)	Total recording time (min)	lowest oxygen saturation (%)
93.8	88.9	0.3	81.7	6.9	81.7	56.1	26.9	5.0	12.0	93.5	227.9	487.0	53

AHI: apnea-hypopnea index, AI: apnea index, CA: central apnea, OA: obstructive apnea, MA: mixed apnea, REM: rapid eye movement, NREM: non-rapid eye movement, CPAP: continuous positive airway pressure, ODI: oxygen desaturation index



**Figure 3.** (A) A chest radiograph obtained before continuous positive airway pressure (CPAP) treatment shows the presence of central patchy infiltrates and diffuse ground-glass opacity in bilateral lung fields (right>left). (B) The chest radiograph obtained one month after CPAP treatment shows the disappearance of these abnormal shadows.



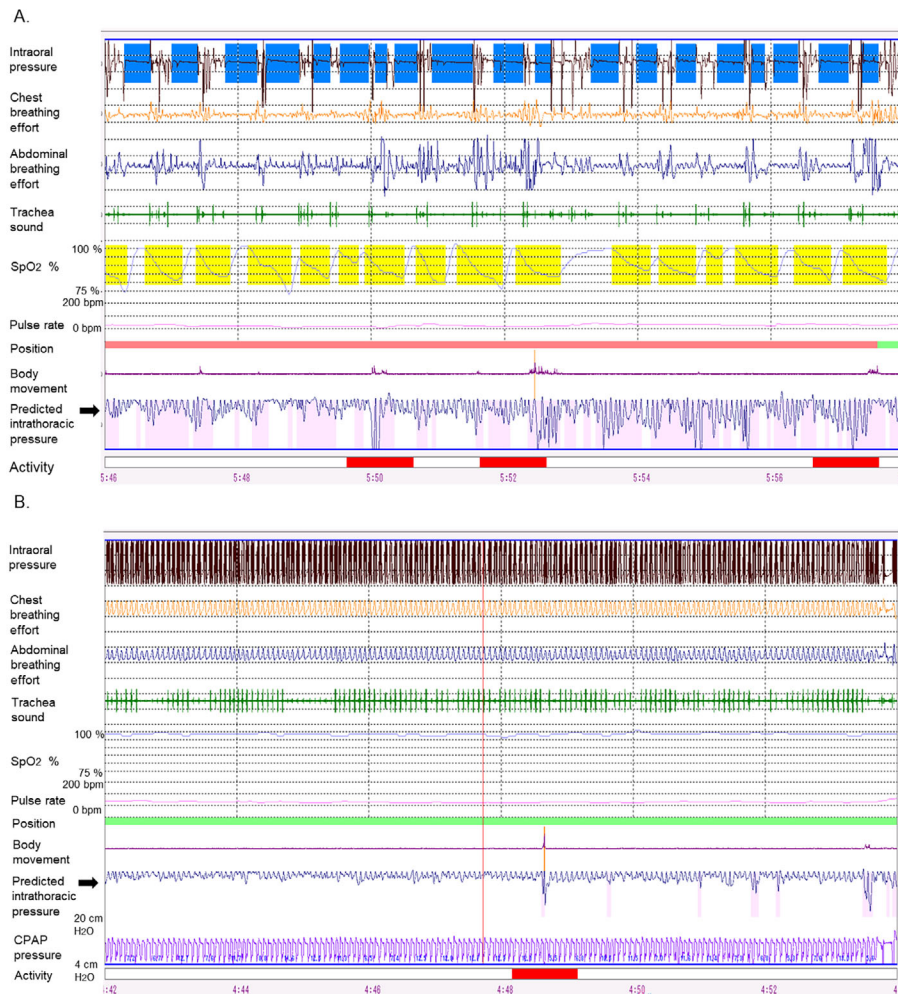
**Figure 4.** A device for electronically predicting pleural pressure from pulse wave signals. (A) A nasal pressure sensor (a), mouth and nose sensors (b), respiratory effort sensors (chest/abdomen) (c), an SpO<sub>2</sub> sensor (d), electrocardiogram electrodes (e), and a green light-emitting diode (LED) pulse wave sensor (f) are connected to the main unit (g). (B) The estimated intrathoracic pressure is measured by obtaining the pulse wave signals using a percutaneous green LED pulse wave sensor (f). (C) The green LED pulse wave sensor is placed on the wrist.

strength and high compliance of the respiratory system, including the lung and thorax, might have enhanced the development of NPPH in these cases. Furthermore, as a strong decrease in the thoracic pressure during inspiration due to upper airway obstruction caused by severe OSA occurred only during sleep, the prominent hemoptysis in the morning reported by this patient was also consistent with the diagnosis of NPPH.

Regarding the mechanism underlying NPPE/NPPH (2, 12, 14), a strong decrease in the thoracic pressure during inspiration due to upper airway obstruction may cause an increase in pulmonary blood flow and an increase in the intracapillary pressure, resulting in pulmonary edema. The normal pleural inspiratory pressure ranges from -2 to -5

cm H<sub>2</sub>O, with negative pressures as extreme as -100 cm H<sub>2</sub>O reported in cases of severe acute upper airway obstruction, especially in athletic patients (15). In addition, the resulting hypoxemia due to pulmonary edema decreases myocardial contractility and increases pulmonary arterial resistance, which further exacerbates pulmonary edema (2). Altogether, the increased transmural capillary pressure likely causes stress failure of the alveolar-capillary membrane, leading to pulmonary edema or, in severe cases, alveolar flooding hemorrhaging (12). Therefore, the incredibly large changes in intrathoracic pressure of this case may have caused blood vessel damage and alveolar hemorrhaging.

It is practically difficult to measure pleural pressure. In addition, measurements of esophageal pressure, which may



**Figure 5.** (A) Results from a device for electronically predicting pleural pressure from pulse wave signals before continuous positive airway pressure (CPAP) treatment. (B) Results from the device two months after CPAP treatment. For position, the green color means the supine position, and the red color means the left lateral decubitus position. For intraoral pressure, the blue color means the existence of obstructive sleep apnea. The yellow color in the area for SpO<sub>2</sub> means oxygen desaturation of 3% or more. The red color in the area for activity means activity detected by the body position sensor. The result for the predicted intrathoracic pressure is indicated by the closed arrow. bpm: beats per minute

substitute for pleural pressure measurements, cannot be easily carried out, since sensors need to be inserted from the nose into the esophagus, which can cause severe discomfort to patients. In the current case, to obtain an approximate estimate of pleural pressure, a device for electronically predicting pleural pressure from pulse wave signals was used. This is a portable device for sleep apnea syndrome testing, which is classified as a type-3 out-of-center sleep test, equipped with a technology that can display the estimated intrathoracic pressure (US Patent No. 6,669,632 B2) (16). Predicted pleural pressures are continuously produced and selected as a time sequence (16). Data obtained before and after CPAP treatment in this patient helped arrive at the diagnosis of alveolar hemorrhaging due to severe OSA.

In conclusion, a case of alveolar hemorrhaging due to severe OSA was described. It is important to consider occult severe OSA in the differential diagnosis of patients with al-

veolar hemorrhaging of unknown cause.

The authors state that they have no Conflict of Interest (COI).

## References

- Schwartz DR, Maroo A, Malhotra A, Kesselman H. Negative pressure pulmonary hemorrhage. *Chest* **115**: 1194-1197, 1999.
- Lemyze M, Mallat J. Understanding negative pressure pulmonary edema. *Intensive Care Med* **40**: 1140-1143, 2014.
- McConkey PP. Postobstructive pulmonary oedema—a case series and review. *Anaesth Intensive Care* **28**: 72-76, 2000.
- Loneragan B, Morgan C, Al-Raweshidy Y, Singh R. Choking as a cause of negative pressure pulmonary oedema (NPPE) in an older adult. *Age Ageing*. Forthcoming.
- Zhang Q, Vayalumkal J, Ricely J, Elrod S, Raza A. The awareness of negative pressure pulmonary edema in the medical intensive care unit. *Cureus* **12**: e10251, 2020.

6. Medford ARL. Negative pressure pulmonary edema: consider undiagnosed obstructive sleep apnea too. *Chest* **141**: 1365, 2012.
7. Chaudhary BA, Nadimi M, Chaudhary TK, Speir WA. Pulmonary edema due to obstructive sleep apnea. *South Med J* **77**: 499-501, 1984.
8. Chaudhary BA, Ferguson DS, Speir WA Jr. Pulmonary edema as a presenting feature of sleep apnea syndrome. *Chest* **82**: 122-124, 1982.
9. Dolinski SY, MacGregor DA, Scuderi PE. Pulmonary hemorrhage associated with negative-pressure pulmonary edema. *Anesthesiology* **93**: 888-890, 2000.
10. Patel AR, Bersten AD. Pulmonary haemorrhage associated with negative-pressure pulmonary oedema: a case report. *Crit Care Resusc* **8**: 115-116, 2006.
11. Hao D, Basnet S, Melnick S, Kim J. Negative pressure pulmonary edema-related diffuse alveolar hemorrhage associated with Sevoflurane and cigarette smoking. *J Community Hospital Internal Med Perspectives* **9**: 247-251, 2019.
12. Contou D, Voiriot G, Djibre M, Labbe V, Fartoukh M, Parrot A. Clinical features of patients with diffuse alveolar hemorrhage due to negative-pressure pulmonary edema. *Lung* **195**: 477-487, 2017.
13. Casoni GL, Tomassetti S, Coffa A, Ravaglia C, Poletti V. Negative pressure pulmonary hemorrhage induced by a candy. *Am J Emerg Med* **28**: 112.e3-112.e5, 2010.
14. Bhattacharya M, Kallet RH, Ware LB, Matthay MA. Negative-pressure pulmonary edema. *Chest* **150**: 927-933, 2016.
15. Rahn H, Otis AB, et al. The pressure-volume diagram of the thorax and lung. *Am J Physiol* **146**: 161-178, 1946.
16. Namba S, Ohsaki R, Shiomi T. United States Patent. Patent No.: US 6,669,632 B2. Apparatus and method for electronically predicting pleural pressure from pulse wave signals [Internet]. [cited 2020 May 26]. Available from: <https://patentimages.storage.googleapis.com/7c/85/9c/0766c7aa6c956a/US6669632.pdf>

The Internal Medicine is an Open Access journal distributed under the Creative Commons Attribution-NonCommercial-NoDerivatives 4.0 International License. To view the details of this license, please visit (<https://creativecommons.org/licenses/by-nc-nd/4.0/>).