

Intrathoracic Goiter Visualized on iodine-123 and technetium-99m Single-Photon Emission Computed Tomography/Computed Tomography

ABSTRACT

Goiter with an intrathoracic component is relatively common; however, it is less common to see extent outside the anterior or posterior mediastinum. We present a case of intrathoracic goiter of significant size and abnormal placement which is examined using both ^{99m}Tc-pertechnetate and iodine-123 single-photon emission computed tomography/computed tomography.

Keywords: Iodine-123, single-photon emission computed tomography/computed tomography, substernal goiter, ^{99m}Tc-pertechnetate, thyroid scintigraphy

INTRODUCTION

Thyroid tissue outside the normal position in the anterior part of the neck is not uncommon. Often the thyroid tissue can be located in the anterior or posterior mediastinum. We present here a case with unusually located thyroid tissue.

CASE REPORT

Twenty years ago, a 66-year-old woman underwent thyroidectomy due to pressure symptoms. Over the next decade she developed thyrotoxicosis and an intrathoracic goiter measuring 5 cm × 8 cm × 8.5 cm was identified and later verified thyroid tissue through computed tomography (CT)-guided biopsy. Thyrotoxicosis was successfully managed with antithyroid therapy. However, moderate thoracic discomfort arose leading to further investigation of the goiter using ¹²³I single-photon emission computed tomography (SPECT) combined with CT to estimate the efficacy of potential radioiodine therapy. This treatment was, however, refrained from because of spontaneous relief from pressure symptoms. Nine years later, the patient was re-examined using ^{99m}Tc-pertechnetate SPECT/CT due to return of the pressure symptoms.

Images show ¹²³I iodine on SPECT/CT [Figure 1], and Tc-99m pertechnetate on SPECT/CT acquisitions [Figure 2]. Uptake of both tracers is similar corresponding to activated sodium-iodine transporters in a state of thyrotoxicosis.

DISCUSSION

Goiter with an intrathoracic component is relatively common.^[1] However, it is less common to see extent outside the anterior or posterior mediastinum.^[2] When

MATTIAS HEDEGAARD KRISTENSEN, JAN ABRAHAMSEN, HENRIK HOLM THOMSEN^{1,2}

Department of Clinical Physiology, Viborg Regional Hospital, ¹Department of Internal Medicine, Clinic for Endocrinology and Diabetes, Viborg Regional Hospital, ²Research Unit for Multimorbidity, Viborg Regional Hospital, Viborg, Denmark


Address for correspondence: Dr. Mattias Hedegaard Kristensen, Department of Clinical Physiology, Viborg Regional Hospital, Banevejen 7C, DK-8800 Viborg, Denmark.
E-mail: mattkr@rm.dk

Submitted: 23-Jul-2021 **Accepted:** 17-Aug-2021
Published: 01-Nov-2021

This is an open access journal, and articles are distributed under the terms of the Creative Commons Attribution-NonCommercial-ShareAlike 4.0 License, which allows others to remix, tweak, and build upon the work non-commercially, as long as appropriate credit is given and the new creations are licensed under the identical terms.

For reprints contact: WKHLRPMedknow_reprints@wolterskluwer.com

How to cite this article: Kristensen MH, Abrahamson J, Thomsen HH. Intrathoracic Goiter Visualized on iodine-123 and technetium-99m Single-Photon Emission Computed Tomography/Computed Tomography. World J Nucl Med 2021;20:377-8.

Access this article online	
Website: www.wjnm.org	Quick Response Code 
DOI: 10.4103/wjnm.wjnm_90_21	

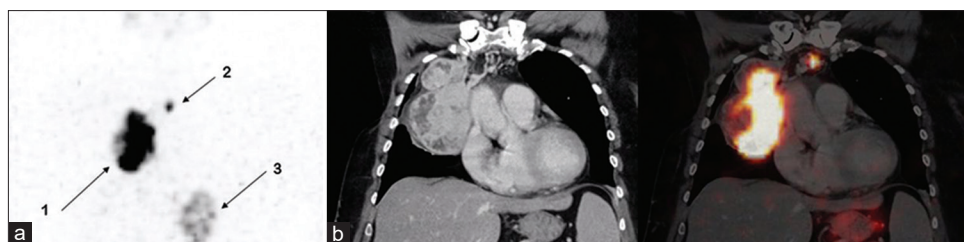


Figure 1: Images using 37 MBq (1 mCi) ^{123}I . (a) Maximum intensity projection visualizes accumulated activity in the intrathoracic thyroid tissue (arrow 1), in the smaller left-sided intrathoracic goiter (arrow 2) and in the stomach (arrow 3). (b) Computed tomography with intravenous contrast and fused images demonstrating significant tracer accumulation in the intrathoracic thyroid tissue

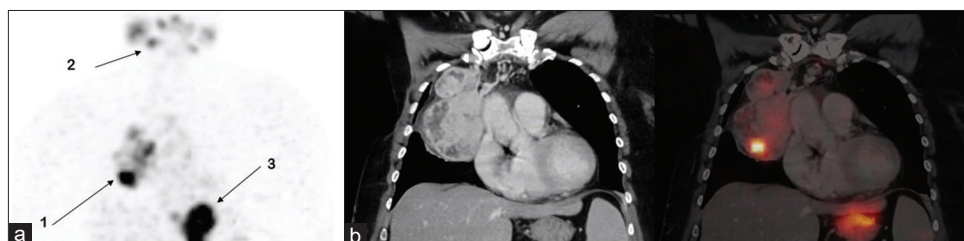

Figure 2: Images using 83 MBq (2,2 mCi) $^{99\text{m}}\text{Tc}$ sodium pertechnetate. (a) Maximum intensity projection visualizes accumulated activity in the intrathoracic thyroid tissue (arrow 1), in the salivary glands (arrow 2) and in the stomach (arrow 3). (b) Computed tomography with intravenous contrast and fused images as in Figure 1

the goiter extends further into the thorax the path of least resistance is towards the right.^[3] Thyroid masses found after thyroidectomies are not common, and are most often the result of incomplete removal of a descending goiter or, more rarely, isolated congenital mediastinal thyroid tissue unconnected to the cervical portion that becomes hypertrophic after removal of functioning cervical thyroid tissue.^[4] Such a condition is suspected when Thyroid Stimulating Hormone remains suppressed after surgery.^[5] When presenting with obstructive symptoms, surgery is the first-choice treatment. Alternatively, radioiodine ablation can be used.^[6] It has been reported that intrathoracic goiter does not always show on planar imaging.^[7-9] Our images show strong consistency between activity distribution of both radiotracers in the intrathoracic thyroid tissue in as well SPECT imaging and planar imaging (image not shown). Considerations regarding the choice of the radiotracer have also been made and the ^{123}I has been preferred over $^{99\text{m}}\text{Tc}$ for intrathoracic goiter due to its higher target-to-background activity, greater tissue specificity, and lower blood pool activity.^[10] The ^{123}I imaging is, however, often unavailable and more costly, and therefore not performed. Furthermore, as presented here, $^{99\text{m}}\text{Tc}$ imaging is usually sufficient, particularly in patients presenting with thyrotoxicosis.

Declaration of patient consent

The authors certify that they have obtained all appropriate patient consent forms. In the form the patient(s) has/have given his/her/their consent for his/her/their images and other clinical information to be reported in the journal. The patients

understand that their names and initials will not be published and due efforts will be made to conceal their identity, but anonymity cannot be guaranteed.

Financial support and sponsorship

Nil.

Conflicts of interest

There are no conflicts of interest.

REFERENCES

1. Doulaptsi M, Karatzanis A, Prokopakis E, Velegarakis S, Loutsidi A, Trachalaki A, *et al.* Substernal goiter: Treatment and challenges. Twenty-two years of experience in diagnosis and management of substernal goiters. *Auris Nasus Larynx* 2019;46:246-51.
2. Madjar S, Weissberg D. Retrosternal goiter. *Chest* 1995;108:78-82.
3. De Andrade MA. A review of 128 cases of posterior mediastinal goiter. *World J Surg* 1977;1:789-97.
4. Polistena A, Sanguinetti A, Lucchini R, Galasse S, Monacelli M, Avenia S, *et al.* Surgical approach to mediastinal goiter: An update based on a retrospective cohort study. *Int J Surg* 2016;28 Suppl 1:S42-6.
5. Patel KM, Parsons CC. Forgotten goiter: Diagnosis and management. A case report and literature review. *Int J Surg Case Rep* 2016;27:192-4.
6. Knobel M. An overview of retrosternal goiter. *J Endocrinol Invest* 2021;44:679-91.
7. Kahara T, Ichikawa T, Taniguchi H, Shinnou H, Sumiya H, Uchiyama A, *et al.* Mediastinal thyroid goiter with no accumulation on scintigraphy. *Intern Med* 2013;52:2159.
8. Kim CY, Jeong SY, Lee SW, Lee J, Ahn BC. Scintigraphic demonstrations of a retrosternal goiter. *Rev Esp Med Nucl Imagen Mol* 2014;33:183-4.
9. Ahn BC. Retrosternal goiter visualized on $^{99\text{m}}\text{Tc}$ pertechnetate SPECT/CT, but not on planar scintigraphy. *Clin Nucl Med* 2016;41:e169-70.
10. Smith JR, Oates E. Radionuclide imaging of the thyroid gland: Patterns, pearls, and pitfalls. *Clin Nucl Med* 2004;29:181-93.