



Acute Paraplegia Caused by Spinal Epidural Empyema Following Infectious Cellulitis of the Hand: Case Report and Literature Review

Breno Nery¹ Cláudio Brandão Filho^{1,2} Lucas Nunes¹ Eduardo Quaggio¹ Fred Bernardes Filho¹
Joaquim Alencar Neto¹ Layssa Rhossana Melo¹ Anna Carolyne Oliveira¹ Rafael Rabello¹
Victoria Rodrigues Durand¹ Rayssa Rocha Silva¹ Rafael Emmanuel Costa¹ José Alencar Segundo¹

¹Department of Neurosurgery, Hospital Beneficência Portuguesa de Ribeirão Preto, Ribeirão Preto, SP, Brazil

²Department of Neurosurgery, University Center Unifacisa, Campina Grande, Paraíba, Brazil

Address for correspondence Cláudio Brandão Filho, Rua Francisco Alves Ramalho 997, Campina Grande, Paraíba 58408-308, Brazil (e-mail: claudiobrandao1@hotmail.com).

J Neurol Surg Rep 2024;85:e29–e38.

Abstract

Background Spinal epidural abscess is a rare but serious condition that can cause spinal cord compression and neurological deficits.

Case Description and Methods The article reports a case of a 31-year-old patient who presented with an infectious cellulitis in the left hand, which progressed to a spinal epidural abscess. The diagnosis was confirmed by clinical examination and magnetic resonance imaging. Treatment involved laminectomy, after which the patient had complete recovery of neurological deficits. This article is a case report with a literature review. Patient data and images were collected by the researchers who participated in the patient's care. The literature was reviewed by one of the researchers based on the search for articles in the PubMed database. For the research, the following keywords were inserted: "Spinal epidural empyema," "Spinal epidural abscess."

Conclusion Spinal epidural abscess is often underdiagnosed, which can lead to delays in treatment and serious complications. The relationship between cellulitis and spinal epidural abscess may be related to the spread of infection through the lymphatic or blood system.

Keywords

- ▶ infectious cellulitis
- ▶ spinal epidural abscess
- ▶ paraplegia
- ▶ case report
- ▶ review

Introduction

Spinal epidural abscess (SEA) was first described in the medical literature in 1761 and represents a severe, generally pyogenic infection of the epidural space requiring emergent neurosurgical intervention to avoid permanent neurologic deficits.¹ The incidence of SEA is around 0.2 to 1.2 cases per 10,000 people per year,^{1–4} with a mortality rate of around 1 and 16%.¹ In recent years, there has been a significant increase in the incidence of SEA worldwide,^{5,6} possibly due

to the increasing incidence of diseases such as acquired immune deficiency syndrome and the increased use of invasive devices in medical practice.^{1,7}

Young adults and elderly are the most commonly affected populations by SEA, with risk factors including diabetes, intravenous drug use, use of invasive devices, autoimmune diseases, cancer, and other conditions that affect the immune system.^{1,7–9} *Staphylococcus aureus* is the most common germ found in patients with SEA with methicillin-sensitive *S.*

received

July 4, 2023

accepted after revision

January 14, 2024

accepted manuscript online

February 13, 2024

DOI <https://doi.org/>

10.1055/a-2267-1810.

ISSN 2193-6358.

© 2024. The Author(s).

This is an open access article published by Thieme under the terms of the Creative Commons Attribution-NonDerivative-NonCommercial-License, permitting copying and reproduction so long as the original work is given appropriate credit. Contents may not be used for commercial purposes, or adapted, remixed, transformed or built upon. (<https://creativecommons.org/licenses/by-nc-nd/4.0/>)

Georg Thieme Verlag KG, Rüdigerstraße 14, 70469 Stuttgart, Germany

aureus more often identified than methicillin-resistant strains.^{10,11}

Common symptoms of SEA include back pain, fever, muscle weakness, and numbness in the limbs.^{7,12} It is considered a neurological emergency, as compression of the spinal cord can lead to serious neurological complications, including paraplegia and loss of limb function.^{7,12} Early diagnosis and immediate treatment may include antibiotics, surgical drainage, and treatment of the underlying cause of the infection and are essential to prevent permanent damage.^{1,7}

We present a case report of a young adult patient who developed SEA after presenting with an infectious cellulitis in the left hand. The patient subsequently developed fever, back pain, muscle weakness, sensory dysfunction, urinary and bowel dysfunction, and was diagnosed with SEA. This case report can contribute to the medical literature by adding another example of how infectious cellulitis can lead to the development of SEA. This may help physicians to quickly identify this complication in patients with severe skin infections, enabling earlier diagnosis and treatment.

Methods

This article is a case report with a literature review. Patient data and images were collected by the researchers who participated in the patient's care. The literature was reviewed by one of the researchers based on the search for articles in the PubMed database. For the research, the following keywords were inserted: "Spinal epidural empyema," "Spinal epidural abscess." The "Boolean Operator" "OR" was used to maximize the number of articles published. Inclusion criteria reached articles published in the 2020 to 2023, case reports, English, and humans. Thus, 41 articles were found based on the ones, of which 33 met the defined analysis criteria.

Case Description

A 31-year-old previously healthy man presented on September 25, 2018 flu symptoms and sought emergency care for initial treatment. At that time the initiated treatment included intravenous dexamethasone, subsequently leading to the development of cardiac arrhythmia. Intravenous amiodarone was administered following dexamethasone, with both medications given in the hand, as depicted in a picture. After the resolution of arrhythmia, the patient was discharged with outpatient follow-up. Three days after, the patient underwent a cardiology evaluation, ruling out cardiac causes for the arrhythmia, attributing it to intravenous medication. On the same night, the patient developed erythema and inflammatory signs at the venipuncture site (–Fig. 1). Due to erythema, the patient returned to the emergency room on the fifth day with high fever, worsening erythema on the hand and forearm, and the onset of back pain. Laboratory analysis on this day showed mild leukocytosis of 12,500 with neutrophilia of 87.9%. Oral ciprofloxacin 500 mg twice a day was initiated. At this point, a vascular

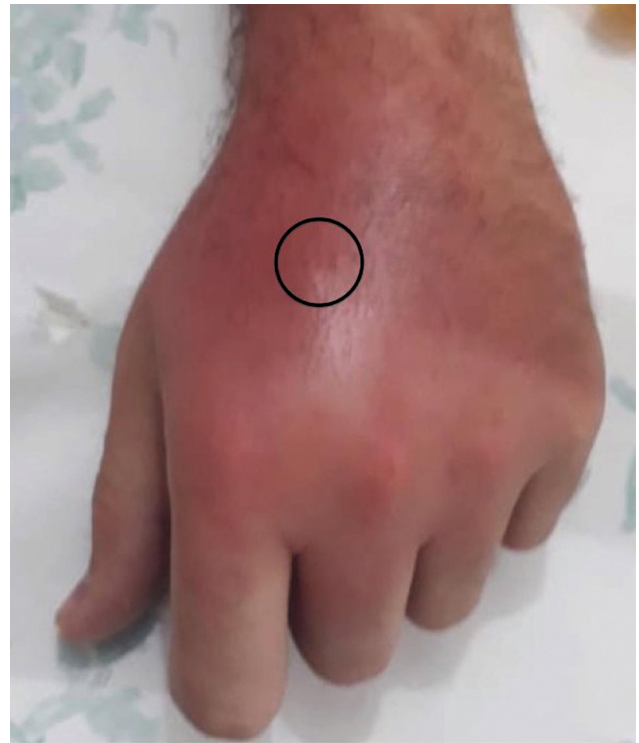

Fig. 1 Left dorsal hand is erythematous, swollen, and tender. Dorsal metacarpal vein (circle) was the local of vein puncture for administration of amiodarone.

doctor performed local drainage of the abscess in the hand, and the patient was referred for outpatient follow-up with oral antibiotics. On the eighth day, the patient sought an orthopaedic doctor due to the onset of acute back pain, and analgesia and physical therapy were indicated. No imaging tests were requested at this time. On the ninth day, it was reported that after a physical therapy session, paresthesia began in the lower limbs without a defined territory, and the low back pain worsened in the early hours of the morning. Urinary incontinence and crural paraparesis started, progressing to paraplegia over the next 12 hours. The patient was in a secondary hospital and was transferred to our hospital for evaluation by the Neurosurgery service. Upon admission, the patient presented with a fever of 40 degrees, crural paraplegia, anesthesia with a dermatomal territory at T7, erythrocyte sedimentation rate (ESR) of 55 mm in the first hour, and 116 mm in the second hour, C-reactive protein (CRP) of 172.35 mm, urea of 48, creatinine of 1.5, worsening of leukocytosis to 14,100 with neutrophilia, lymphopenia, and the presence of toxic granulations. Spinal magnetic resonance imaging (MRI) showed the presence of a posterior abscess extending from the level of T4 to T8, causing anterior displacement of the spinal cord (–Figs. 2 and 3). Surgery was performed urgently after the results of the MRI. Previous doctors did not order cultures. In surgery performed urgently, blood culture and swabs were collected from the site of the surgical wound. The patient underwent emergent spinal decompression with laminectomies from T4 to T8, and frank purulent fluid was drained. He started treatment empirically with meropenem 1 g 8/8 h and vancomycin 15 mg/kg 8/8 h,

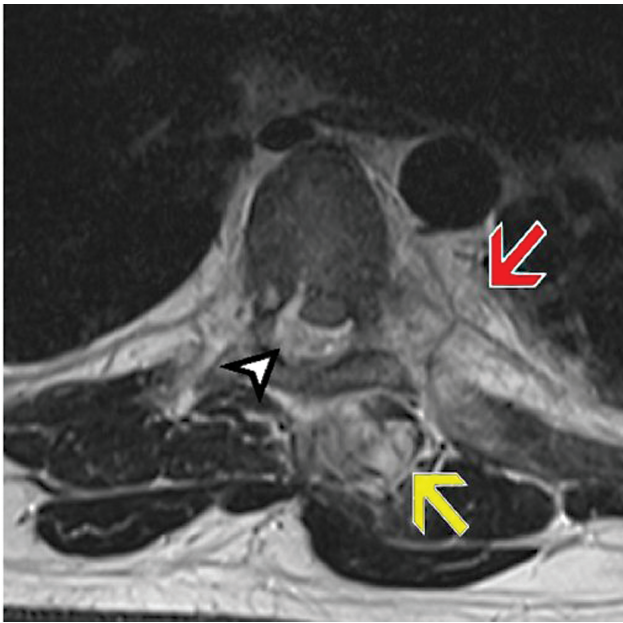


Fig. 2 A thoracic spine T2-weighted axial MRI showing a fluid collection with hypersignal in the epidural space (arrowhead), displacing the spinal cord anteriorly, and also other discrete fluid collections with hypersignal on the intrathoracic paravertebral (red arrow) and extra-thoracic paraspinous (yellow arrow) areas. MRI, magnetic resonance imaging.

that were exchanged for ampicillin 1 g 6/6h because the culture revealed *Streptococcus pyogenes* strain sensitive to ampicillin in blood and on the empyema material. Hematogenous spread from hand infectious cellulitis probably causes

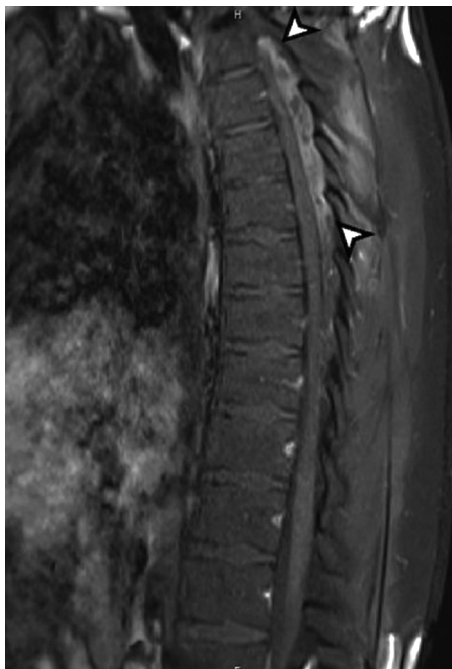

Fig. 3 A thoracic spine T1-weighted sagittal MRI with fat saturation, obtained after the intravenous application of a Gd-containing contrast agent, shows intense marginal contrast enhancement of the epidural fluid collection in the vertebral canal (arrowhead). MRI, magnetic resonance imaging.

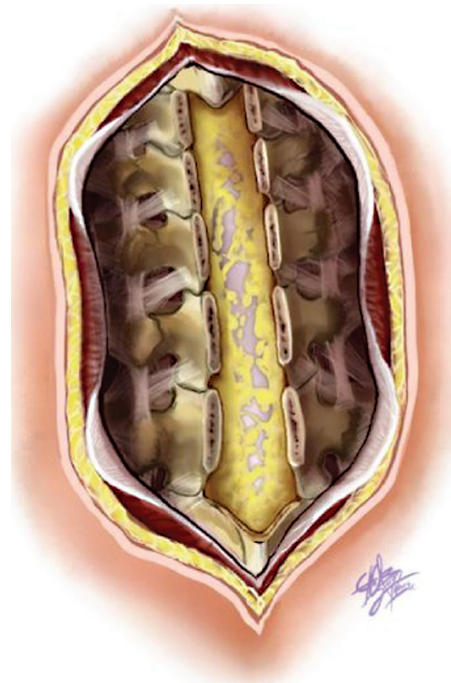


Fig. 4 Schematic representation of the posterior view of the spinal column, indicating a purulent collection in the epidural space between T4 and T8 vertebrae, which is characteristic of spinal epidural abscess in this location.

the SEA (►Figs. 4 and 5). At the first hospital, an emergency physician initially considered hypotheses of Guillain-Barré syndrome and transverse myelitis. However, after a more in-depth evaluation, these conditions were ruled out. The hypothesis of SEA was strengthened based on the clinical presentation and imaging results, emphasizing the importance of a comprehensive and careful approach in identifying and discarding differential diagnoses. At a 6-week follow-up, the patient underwent a new MRI which did not show evidence of SEA, indicating that the abscess was completely drained by the surgical procedure and the patient had responded well to the antibiotic treatment (►Fig. 6). The

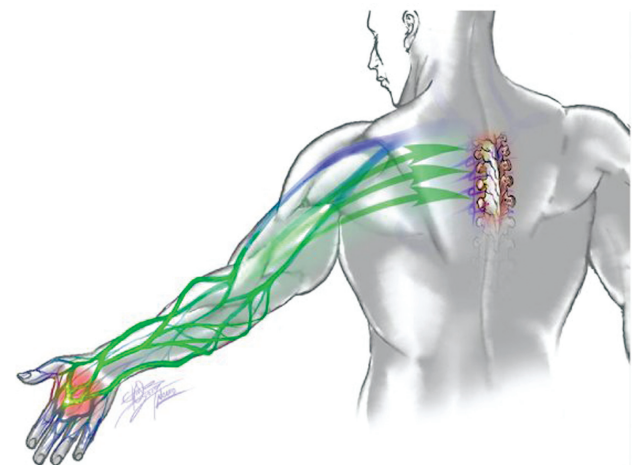


Fig. 5 Schematic drawing showing the route taken by the infectious process.

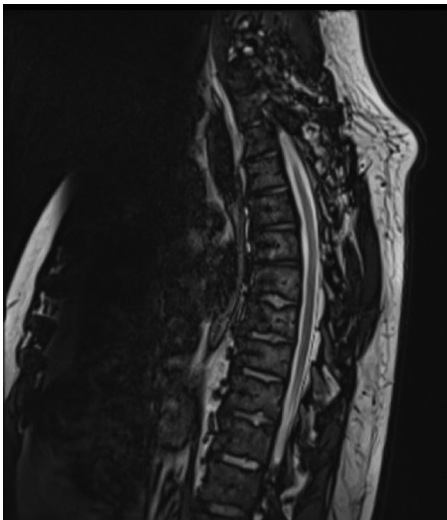


Fig. 6 Sagittal T2-weighted magnetic resonance image showing the patient’s spinal column after laminectomy and antibiotic treatment. No further evidence of SEA is detected, indicating successful treatment. SEA, spinal epidural abscess.

patient had no signs of infection and had fully recovered from neurological deficits.

Discussion

SEA is a rare, but extremely serious condition, due to the potential for lethality and functional disability. There is a correlation between incidence and an increase in risk factors, with emphasis on aging, immunosuppressive conditions, intravenous drugs, spinal procedures.¹³ It is rarely observed in individuals under 20 years of age (0.3 per 100,000 people), with incidence levels 20 times higher in older patients (6.5 per 100,000 people over 70 years of age), with relevance in the fifth to seventh decades of life and male.⁶

The diagnosis of SEA, when there is a classic triad of symptoms, fever, low back pain, and neurological deficit, raises the suspicion of this condition, which requires surgical intervention and early antibiotic therapy.^{14–17} Many studies report the classic triad of symptoms in SEA, as described in **Table 1**. Of the reported cases, 38.88% had the triad of symptoms. However, it was observed that the main challenge is the diagnosis, since most do not present in the classic way.¹⁸ Some symptoms vary according to the site affected by SAE (for example, cases with cervical involvement may have dysphagia, while cases with thoracic involvement may have sphincter dysregulation).¹⁹

An increased level of spinal cord compression is strongly correlated with a higher likelihood of experiencing neurological symptoms, which can lead to poor outcomes for the affected individual.²⁰ Abdelhakim et al developed a classification system for spinal cord compression and its association with neurological deficit in SEA. Grade 4 and 5 abscesses characterized by overt spinal cord compression have a significant correlation with motor weakness during initial presentation. Abscesses classified as Grade 5, which exhibit severe cord compression without visible cerebrospinal fluid

Table 1 Review of case reports about Spinal Epidural Abscess in the year 2020–2023

Author, year	Age, sex	Infectious source, cause	Clinical presentation	Laboratory test	Image exam	Treatment	Culture, ATB therapy empirical	Outcome
Agrawal et al, 2022 ¹²	Woman, 70	DM2	Fever, altered sensorium, back pain and upper limbs; hypertonia, exaggerated deep tendon reflexes; paraparesis	Not specified	MRI T10–L1 epidural abscess	Laminectomy and drainage	<i>Streptococcus gallolyticus</i> ; ceftriaxone, doxycycline, and ampicillin	Recovery sensorium, power lower limbs partially improved; progressively debilitating condition; died
Scalia et al, 2022 ³⁹	Female, 54	Acute pyelonephritis	Lumbar pain, paraparesis spastic	Not specified	MRI T2–L5 anterior epidural abscess	Laminectomy and drainage	No specified culture; after drainage, local vancomycin powder.	Improved; MRI postoperative documented adequate canal decompression.
Kharbat et al, 2022 ⁴⁴	Male, 53	Cellulitis right hand; DM	Fever, back pain, urinary dysfunction	Elevated WBC	MRI T5–T9 epidural abscess	Laminectomy and drainage	Methicillin-resistant <i>Staphylococcus aureus</i> (MRSA); vancomycin powder	The patient was thereafter managed with daptomycin. Partially improved
Ammar et al, 2022 ⁴⁵	11 month, boy	Upper lobe pneumonia	Fever	Not specified	MRI C7–L2 posterior abscess epidural	Percutaneous drainage	MRSA	MRI postoperative showed adequate canal decompression; antibiotic therapy 1 month
Cao et al, 2022 ³	Male, 58	Fistula between the cervical abscess and the epidural abscess of the spinal canal	Neck pain, upper limbs and shoulders; fever, decrease muscle strength of the limbs	Not specified	MRI C1–C7 epidural abscess	Cervical decompression and drainage	<i>S. aureus</i> ; vancomycin	Ceftriaxone for 5 weeks. Improved muscle strength. MRI postoperative showed adequate canal decompression

Table 1 (Continued)

Author, year	Age, sex	Infectious source, cause	Clinical presentation	Laboratory test	Image exam	Treatment	Culture, ATB therapy empirical	Outcome
Rashid et al, 2022 ²²	Female, 58	Not specified	Intermittent low back pain, spastic paraparesis, fever, and weight loss	Negative for leukocytosis or anemia; ERS 75 mm/h	MRI T11–T12 epidural abscess, and vertebral osteomyelitis	T11–T12 laminectomy and tissue removal	Histopathology showed <i>Aspergillus</i> spp; antifungal	Patient progressed well
Papaetis et al, 2022 ⁴⁷	Male, 63	Osteomyelitis	Fever, altered level of consciousness, pain mid-back	WBC 16, 170/mm ³ , ERS 95 mm/h, CRP 16.8 mg/dL	MRI septic spondylodiscitis T6–T7; osteomyelitis T6–T7; anterior epidural abscess T6–T7	Laminectomy and drainage; foraminotomy and facetectomy.	<i>Bacteroides fragilis</i> ; meropenem and teicoplanin	Ertapenem and metronidazole for 12 weeks. The patient improved consciousness and mobility
Göre et al, 2022 ³⁰	Male, 56	COVID-19 infection	Fever, back pain, lower extremity muscle weakness, IgA nephropathy	WBC 8, 100–11,600/mm ³ , CRP (0.01–0.177 g/L)	MRI epidural abscess C7–T1 and T10–T11	Teicoplanin and ciprofloxacin. Neurosurgery not considered.	Coagulase negative <i>S. aureus</i> .	Clinic and symptoms improved. Control MRI showed regression of the formation of abscess.
Fujita et al, 2022 ⁴⁸	Male, 71	Thoracoplasty for tuberculosis	Fever, back pain, lower extremity muscle weakness, tendon reflexes, reduced bilateral, Guillain-Barré syndrome	WBC 13,600 cell/μL, CRP 14.24 mg/dL, anti-ganglioside antibodies	MRI epidural abscess L5–S1	Surgical decompression and drainage	<i>Campylobacter coli</i> ; levofloxacin	Immunoglobulin therapy attenuated the progression of the paralysis.
Xu et al, 2022 ²⁷	Male, 56	Not specified	Fever, lower back, and extremity pain	WBC 12,200 cell/μL, CRP 89.2 mg/dL, ERS 61 mm/h	MRI epidural abscess T1–T2 and L3–L4	Laminectomies T1–T2 and L2–L3; drainage	Methicillin-resistant <i>S. aureus</i> ; vancomycin empirically	Vancomycin 6 weeks; lower limb weakness not significantly improved.
Shin et al, 2022 ¹⁸	Male, 85	Diabetes mellitus, chronic kidney disease; infectious urinary tract; fracture lumbar vertebra	Fever, lower back pain	WBC 14, 100 cell/μL, CRP 24.4 mg/dL, ERS 61 mm/h	MRI epidural abscess anterior L3–S1.	Laminectomy L4–S1 and drainage	<i>E. coli</i> ; cefotaxime	Continuation 6 months antimicrobial. Improved.
Mor et al, 2021 ³⁴	Female, 56	Not specified	Fever, back pain, paraplegia, confusion, and urinary incontinence	Not specified	MRI epidural abscess between L2 and the distal-most thecal sac	L3–L5 laminectomy	<i>Pasteurella multocida</i> ; vancomycin and cefepime.	Ampicillin-sulbactam; full recovery paraplegia.
Sati et al, 2021 ¹⁷	Male, 23	Not specified	Fever, back pain, weakness of the left upper limb, and spastic paraplegia	Not specified	MRI epidural abscess C5/C6–T2/T3	C7–T1 hemilaminectomy	<i>S. aureus</i>	Muscle tone and power of the upper limb were recovered
Kim et al, 2021 ²¹	Female, 75	Not specified	Back pain, pulmonary edema, dyspnea	WBC 6700 cell/μL, PCR 7.718 mg/dL, ERS 59 mm/h	MRI epidural abscess L5 seconds	L15–S1 laminectomy; second surgery: lumbar corpectomy	<i>S. hominis</i> (blood culture) and <i>S. epidermis</i> (abscess culture); vancomycin 9 weeks; second surgery plus <i>M. tuberculosis</i> in the abscess culture.	Recovered completely
Kim et al, 2021 ²¹	Female, 79	Rheumatoid arthritis and DM2	Back pain, fever, weak legs.	WBC 14,360 cell/μL, PCR 7.57 mg/dL, ERS 83 mm/h	MRI epidural abscess T3-L5	Laminotomy t8 and t12 levels; 5-Fr pediatric.	Methicillin-resistant <i>S. aureus</i> ; vancomycin	Motor strength improved
Nitmal et al, 2021 ⁵⁰	Male, 71	Chemoradiation therapy, DM2.	Fever, neck pain	WBC 21,000 cell/μL, CRP 7.57 mg/dL, ERS 83 mm/h	MRI anterior epidural abscess C2–C7	Conservative therapy	<i>Klebsiella pneumoniae</i> ; ceftriaxone	Progressively debilitating condition; died
Horiya et al, 2021 ⁵¹	Female, 62	Type 2 diabetes mellitus	Coma	WBC 9,600/μL (neutrophil 94.0%), CRP 29.76 mg/dL, and procalcitonin 19.48 ng/mL	CT L4–L5 fat-saturated T2-weighted imaging MRI L4–L5 left pyogenic psoas abscess and spontaneous discitis	Percutaneous drainage	Methicillin-susceptible <i>S. aureus</i> broad-spectrum (meropenem and daptomycin) >> others antibiotics	Recovery, but with severe bone destruction
Munasinghe et al, 2021 ³⁶	Female, 67	Subarachnoid block (anesthesia)	Back pain	Not specified	Urgent MRI SEA with cauda equina compression	Bilateral L4 laminectomy and drainage	Methicillin-resistant <i>S. aureus</i> >> meropenem	Complete recovery after 6 weeks

(Continued)

Table 1 (Continued)

Author, year	Age, sex	Infectious source, cause	Clinical presentation	Laboratory test	Image exam	Treatment	Culture, ATB therapy empirical	Outcome
Vig et al, 2021 ³⁸	Female, 22 month old	Presumptive diagnosis of nonspecific viral illness	Fever, dry cough, back pain, and recusal food	WBC 7,500 mm ³ (68% neutrophils, 22% lymphocytes, 9% monocytes on differential); ESR 73 mm/h; CRP 92.5 mg/L	T2 STIR and T1 fat-suppression MRI with gadolinium contrast SEA T5–T11	T10–T11 decompressive laminotomy and evacuation of abscess	Group A <i>Streptococcus pyogenes</i> empiric antibiotic (Ceftriaxone)	Total recovery with no neurological symptoms discharged on oral clindamycin.
Spennato et al, 2020 ²⁰	Female, 9	Glycogen storage disease type 3b	Axial dorsal pain, fever, paraplegia, urinary and fecal incontinence	Elevated ERS	MRI posterior epidural mass at levels D5–D11 with hypointense signal in T1 and T2	T5–T11 laminotomy	<i>Staphylococcus aureus</i> methicillin sensitive. Broad-spectrum antibiotic (cefazidime and vancomycin) >> ceftriaxone and vancomycin	Total recovery, but motor deficits did not recover.
Spennato et al, 2020 ²⁰	Female, 14	Paronychia and skin abscess in the knee	Back pain Pain at the mobilization of the neck and torticollis	Elevated C-reactive protein (357.7 mg/L), procalcitonin and WBC normal	MRI hyperintense signal in T2-weighted C4 to L1	T1–T12 laminotomy	<i>Staphylococcus aureus</i> methicillin sensitive. Broad-spectrum antibiotic (clindamycin, rifampicin, gentamicin, and ciprofloxacin)	She fully recovered from her symptoms. Postoperative MRI at 3 months did not show recurrence
Lodhi et al, 2020 ⁵³	Male, 66	Cat bit	Unrelenting back pain, fever, chills, and severe back spasms	WBC 19,600 cells/mL, elevated CRP 5.3 mg/L, and elevated procalcitonin (1.43 mg/ml)	MRI with and without contrast SEA L3–L4	Nonsurgical	<i>P. multocida</i> broad-spectrum IV antimicrobials. (ampicillin-sulbactam >> ceftriaxone)	Total recovery
Altdorfer et al, 2020 ⁵⁴	Woman, 76	Not specified	Back pain, lower limb, and loss of sphincter control	CRP 322mg/L; WBC 16,700/ml (neutrophilic)	MRI with contrast (full spine) SEA T4–T6	Laminectomy with surgical drainage	<i>Aggregatibacter aphrophilus</i> (HACEK group) broad spectrum (cefazidime and vancomycin) >> ceftriaxone (2 g twice daily)	Total recovery with no pain or sensorimotor deficits
Hirai et al, 2020 ³³	Male, 52	Not specified	Acute back pain and fever,	WBC 5,800 cells/mL (band cells 27%, segmented cells 58%, lymphocytes 10%, monocytes 4.5%); CPR: 29.0 mg/dL;	MRI SEA L2–L4	Laminectomy drainage abscess and antibiotic	<i>Salmonella altona</i> ; broad-spectrum (meropenem 1 g 8/8 h) >> ceftriaxone 2 g 24/24 h >> ceftriaxone 2 g 12/12 h and ciprofloxacin 400 mg 8/8 h >> oral ciprofloxacin for another 2 weeks	Discharged without signs of neurological dysfunction (neurological status improved)
Mallik et al, 2020 ⁵²	Female, 20	Spinal anesthesia [cesarean]	Lower limb weakness, urinary retention, lower back pain	WBC 27,000, (90% neutrophils), CRP 13	MRI with contrast SEA T2–S1	L3 laminectomy with drainage of pus	<i>Staphylococcus aureus</i> Broad-spectrum antibiotics (ceftriaxone + amikacin) >> (meropenem + linezolid)	Recovery after 3 weeks
Brunasso et al, 2020 ⁵⁵	Female, 45	Therapeutic epidural spinal injections (ESIs) of steroids.	Constipation, leg pain, inability to walk, acute urinary retention, perineal hypoesthesia	WBC 19,790/ml	Lumbar MRI without gadolinium SEA L4–L5–S1	Laminectomy for debridement/ decompression	Methicillin-resistant <i>Staphylococcus aureus</i> and <i>Streptococcus parv sanguinis</i> ; broad-spectrum (vancomycin and ceftazidime) >> clindamycin and gentamicin	Partial recovery with 4/5 motor function without any residual sphincter dysfunction

Table 1 (Continued)

Author, year	Age, sex	Infectious source, cause	Clinical presentation	Laboratory test	Image exam	Treatment	Culture, ATB therapy empirical	Outcome
Van baarsel et al, 2020 ⁵	Female, 77	Not specified	Lumbar back pain, fever	CRP 3.25 mg/L	MRI SEA L2-L3 with osteomyelitis spanning L2-L4	Expectant	<i>E. coli</i> (ertapenem) >>> oral ciprofloxacin	Complete recovery with no neurological deficits
Van baarsel et al, 2020 ⁴³	Male, 51	Not specified	Neck pain and stiffness	WBC 10,900/mL, lactate 2.14 U/L	CT head without contrast, no acute abnormalities; MRI SEA C5-C7	Urgent laminectomy by orthopaedic surgery	<i>E. cloacae</i> (cefepime)	Permanent paraplegia and decreased hand strength bilaterally.
Van baarsel et al, 2020 ⁵	Female, 63	Not specified	Bilateral lower extremity weakness and tingling, urinary and fecal incontinence	ESR 101 mm/h and CRP 12 mg/L	Spinal epidural abscess spanning T6-T9	T6-T9 laminectomy and decompression	<i>B. fragilis</i> (ertapenem)	Permanent paraplegia
Plancha da Silva et al, 2020 ⁵⁶	Female, 53	Not specified	Dorsal persistent pain, fever, loss of bowel and bladder control, and progressive paraparesis	WBC with left deviation (11,820/mL with 85.3% neutrophils)	CT T4-T9; MRI T2-T9, with greater thickness at levels T4-T6	Urgent laminectomy and drainage of the abscess	Methicillin-susceptible <i>S. aureus</i> ; empiric antibiotic therapy (ceftriaxone and metronidazole) >>>> flucloxacillin.	Improvements in some motor and sensory deficits after physical therapy
Sahu and Chastain, 2020 ⁵⁴	Female, 80	Neurostimulator implant	Back pain with different characteristics	Not specified	MRI epidural abscess C2-T8	Urgent neurosurgical evacuation	Group B streptococcus	Not specified
Maiese et al, 2020 ⁵⁷	Male, 44	Mesotherapeutic	Lumbar pain, fever, and vomiting >>> paraplegia and urinary incontinence	WBC and elevated PCR	MRI intramedullary lesion extended between multiple cervical and dorsal metamers	Start a rehabilitation program	Methicillin-sensitive <i>S. aureus</i> >> vancomycin and meropenem	Paraplegia with walking allowed only in a wheelchair.
Polsky et al, 2020 ³⁷	Male, 65	Not specified	Unable to ambulate, perineal anesthesia, and urinary retention.	No data	MRI thoracic spinal epidural abscess.	Surgical decompression for his spinal epidural abscess	Multi-week course of antibiotics	Continued to progress with physical therapy and was able to regain strength and ambulate independently
Usuda et al, 2020 ¹³	Woman, 33	Not specified	Fever, back pain, and numbness	WBC increases CRP and ESR	MRI spinal epidural fluid L5 to S2 vertebral body level region	CT-guided percutaneous needle aspiration of the abscess	Piperacillin-tazobactam >>> oral levofloxacin	MRI scan > improvements > discharged
Shikano et al, 2020 ²⁸	Male, 70	Airway stent	Lower limb muscle weakness and numbness of the left hand	High levels of inflammatory markers	MRI epidural abscess	Hemilaminectomy for C7 and laminectomy for T1-T4.	Antibiotic therapy was made, but not specified	Muscle weakness gradually progressed.

Abbreviations: CRP, C-reactive protein; CT, computed tomography; DM2, Type 2 diabetes mellitus; ESR, erythrocyte sedimentation rate; IgA, immunoglobulin A; MRI, magnetic resonance imaging; SEA, spinal epidural abscess; WBC, white blood cell.

around the cord, are more prone to have concurrent sensory deficit or paresthesias and are significantly linked with bladder dysfunction.¹ However, in some cases, the occurrence of deficits disproportionate to the degree of compression observed on imaging suggests a role of vascular compromise of the cord secondary to vascular thrombosis or thrombophlebitis, which may be classified as grade 1, 2, or 3 depending on the deformation of the thecal sac.²¹ In our article, the patient had a grade 5 compression, resulting in motor weakness, paresthesia, urinary and bowel dysfunction.

Prompt diagnosis and treatment of SEA is essential as delay can result in paralysis or death.^{1,6,17,22-24} Due to its low incidence and nonspecific presentation, accurately diagnosing SEA can be challenging with up to 75% of cases being misdiagnosed, misdiagnosis is alarmingly common.^{1,18,23,25,26} There is a significant reduction in diagnostic delays by implementing a novel decision guideline using risk factor assessment followed by ESR and CRP testing before obtaining definitive imaging for suspected SEA.²⁷ In the analysis of ►Table 1, despite the small amount of data collected, of the 24 (66.6%) articles that specified laboratory analysis of inflammatory markers, ESR was elevated in 13 cases (54.16%) and CRP in 20 (83.3%). The white cell count also showed leukocytosis in 17 (70.83%) of cases.

Considering that with the research of risk factors, which can be more sensitive than the classic triad, associated with markers of inflammatory activity and white cell count, an imaging exam can be used to confirm the diagnosis of SEA.²⁸ Definitive diagnosis of SEA is best achieved with gadolinium-enhanced MRI, with a sensitivity and specificity greater than 90%.²³ Enhanced MRI is still considered the preferred imaging study for confirming the diagnosis of SEA, which is most commonly found in the thoracic region (48%), followed by the lumbar region (31%) and the cervical region.²⁹⁻³³ As evidenced in ►Table 1, the SEA involved multiple vertebral levels; the region of the thoracic vertebrae was affected in 50%, the lumbar region in 50%, and the cervical region in 27.7%.

Empiric antibiotic treatment is started in nearly all patients and is narrowed if speciation is possible. The most common causative organism, *S. aureus*, is present in 50 to 70% of cases. This *S. aureus* is followed by aerobic and anaerobic streptococcus species in 7% of the cases.²² Despite little data collected, ►Table 1 reveals *Staphylococcus* and *Streptococcus* are the most recurrent, although other genres and even fungi can be found. In this article, it was found, when analyzing the studies found, that the most prevalent microorganisms in epidural abscesses were 11 (33.33%) cases of methicillin-sensitive *S. aureus*, 6 (18.18%) cases of methicillin-resistant *S. aureus*, 4 (12.12%) cases of *Streptococcus*. Bacteria of the gastrointestinal tract, for example, *Escherichia coli*, are also related to the formation of such abscesses, despite a lower prevalence when compared with *Staphylococcus* and *Streptococcus*.

When there is suspicion of SEA, prompt treatment is crucial. Empirical antibiotic therapy is typically initiated in almost all patients, and if the causative agent can be identified, the treatment is then narrowed down to a more specific spectrum.³⁴ Patients who present with a focal motor deficit are more likely to experience neurological improvement with surgical intervention.²⁸ Laminectomy alone has the

benefit of being less expensive and having a relatively lower risk profile when compared with laminectomy combined with fusion.¹ However, nonoperative management may be appropriate in patients with intact neurologic status, multiple medical comorbidities that preclude safe surgery, pan spinal involvement, or paralysis for 0.48 hours.²³ In most of the reviewed case reports, shown in ►Table 1, the treatment involved surgical intervention in 83.3%, with only 3 cases undergoing percutaneous drainage of the SEA. In addition, 16.6% were treated with antibiotics alone. Two cases resulted in death (5.5%), with one undergoing surgical intervention and the other managed with antibiotics.

The single most important predictor of residual neurologic outcome is the patient's neurologic status before intervention.^{13,35,36} More severe preoperative neurologic deficits are associated with worse outcomes.¹ In our case, despite the severe neurological condition, there was complete recovery of the deficits presented. As shown in ►Table 1, out of the six cases that had paraplegia, two had complete recovery.

Cellulitis is an inflammatory condition, sometimes of infectious origin, where various tissues are affected, which can lead to pain, swelling, and functional loss. Risk factors include diabetes mellitus, intravenous drug use, alcohol consumption, steroids, gout, rheumatoid arthritis, peripheral vascular disease, and renal failure.^{37,38} *Streptococcus pyogenes*, in its invasive form, can have several listed etiologies, notably for cellulitis (39%).²² Linked to this condition, several microorganisms can be disseminated via hematogenous or lymphatic routes, perpetuating the proliferation of bacteria in unusual places. Possible manifestations are SEAs, which, despite having a rare epidemiology, is extremely serious.³⁹

The etiology in this case remains unknown, although we suggest dissemination through the venous plexus. The spinal epidural space is a potential space located between the dura mater and vertebral bone that contains adipose tissue and a rich venous plexus. Venous drainage of the spinal column and epidural space communicates with the systemic circulation via the Batson plexus, a valveless venous network that allows bidirectional flow and potential spread of infection from local or distant sources.^{1,40-42} The most likely pathway would be through the veins of the left upper extremity, which join the thoracic veins and then the superior vena cava, which carries blood to the heart. From there, the infection can spread to the thoracic vertebral column via the ascending lumbar veins and the posterior intercostal veins.³⁹

Another possibility would be lymphatic spread. The lymphatics on the medial side of the hand follow the basilic vein and drain into the supratrochlear lymph nodes. The supratrochlear lymph nodes are located above the medial epicondyle of the humerus. The supratrochlear lymph nodes will eventually drain into the axillary lymph nodes, which will then travel to the heart through the thoracic duct, and may subsequently access the Batson plexus.⁴³⁻⁵⁷

Conclusion

SEA is a rare condition, but extremely relevant due to morbidity and mortality sequelae. Early interpretation of

the patient's signs and symptoms is a diagnostic challenge due to the absence of a suggestive clinical picture in most cases. That said, cellulitis has been shown to be one of the most relevant causes for the development of empyema.

The doctor's suspicion should take into account the risk factors and symptoms, whether nonspecific or specific, in addition to a targeted anamnesis, so that the correct conduct is directed.

It is also important to point out that even making the correct diagnosis, the doctor should not delay his conduct, under the risk of permanent damage or even an unfavorable outcome, death. Thus, the indication of surgical or conservative management, combined with antibiotic therapy, must be carefully analyzed so that there is a favorable result.

Conflict of Interest

None declared.

References

- Reihsaus E, Waldbaur H, Seeling W. Spinal epidural abscess: a meta-analysis of 915 patients. *Neurosurg Rev* 2000;23(04):175–204, discussion 205
- Aycan A, Aktas OY, Guzey FK, et al. Rapidly progressive spontaneous spinal epidural abscess. *Case Rep Infect Dis* 2016;2016:7958291
- Cao J, Fang J, Shao X, Shen J, Jiang X. Case Report: a case of cervical spinal epidural abscess combined with cervical paravertebral soft tissue abscess. *Front Surg* 2022;9:967806
- Houshian S, Seyedipour S, Wedderkopp N. Epidemiology of bacterial hand infections. *Int J Infect Dis* 2006;10(04):315–319
- Abdelhakim K, Bakir MS, Fargen KM, Raper DM. A classification system for spinal cord compression and its association with neurological deficit in spinal epidural abscess. *J Neurosurg Spine* 2017;26(05):573–578
- Rosc-Bereza K, Arkuszewski M, Ciach-Wysocka E, Boczarska-Jedynak M. Spinal epidural abscess: common symptoms of an emergency condition. A case report. *Neuroradiol J* 2013;26(04):464–468
- Zhang JH, Wang ZL, Wan L. Cervical epidural analgesia complicated by epidural abscess: a case report and literature review. *Medicine (Baltimore)* 2017;96(40):e7789
- Darouiche RO. Spinal epidural abscess. *N Engl J Med* 2006;355(19):2012–2020
- Khanna RK, Malik GM, Rock JP, Rosenblum ML. Spinal epidural abscess: evaluation of factors influencing outcome. *Neurosurgery* 1996;39(05):958–964
- Centers for Disease Control Prevention. Active bacterial core surveillance (ABCs) report. Emerging infections program net-work. Group A Streptococcus—2015. Accessed October 1, 2017 at: <https://www.cdc.gov/abcs/reports-findings/survreports/gas15.pdf>.
- Shah AA, Ogink PT, Harris MB, Schwab JH. Development of predictive algorithms for pre-treatment motor deficit and 90-day mortality in spinal epidural abscess. *J Bone Joint Surg Am* 2018;100(12):1030–1038
- Agrawal V, Viswanathan S, Selvaraj J, Pillai V. *Streptococcus gallolyticus*-related spinal epidural abscess. *BMJ Case Rep* 2022;15(08):e250733
- Usuda D, Taki Y, Izumida T, et al. Disseminated spinal epidural abscess in an immunocompetent individual: a case report and review of the literature. *J Med Cases* 2020;11(12):417–425
- Chenoweth CE, Bassin BS, Mack MR, et al. Vertebral Osteomyelitis, Discitis, and Spinal Epidural Abscess in Adults. Ann Arbor, MI: Michigan State University; 2018
- Connor DE Jr, Chittiboina P, Caldito G, Nanda A. Comparison of operative and nonoperative management of spinal epidural abscess: a retrospective review of clinical and laboratory predictors of neurological outcome. *J Neurosurg Spine* 2013;19(01):119–127
- Darouiche RO, Hamill RJ, Greenberg SB, Weathers SW, Musher DM. Bacterial spinal epidural abscess. Review of 43 cases and literature survey. *Medicine (Baltimore)* 1992;71(06):369–385
- Sati WO, Haddad M, Anjum S. A case of spinal epidural abscess presenting with horner syndrome. *Cureus* 2021;13(04):e14541
- Shin W, Oh JH, Cho AY, et al. A rare case of spinal epidural abscess following urinary tract infection caused by escherichia coli in a patient with pre-existing stress fractures of the lumbar spine. *Korean J Fam Med* 2022;43(02):147–149
- Ameer MA, Knorr TL, Mesfin FB. Spinal Epidural Abscess. Mar 31, 2020. In: StatPearls [Internet]. Treasure Island, FL:: StatPearls Publishing;; 2020
- Spennato P, Renedo D, Cascone D, et al. Spinal epidural abscess in children: a case-based review. *Childs Nerv Syst* 2020;36(07):1385–1392
- Kim C, Lee S, Kim J. Spinal epidural abscess due to coinfection of bacteria and tuberculosis: a case report. *World J Clin Cases* 2021;9(16):4072–4080
- Rashid MH, Hossain MN, Ahmed N, et al. *Aspergillus* spinal epidural abscess: a case report and review of the literature. *J Craniovertebr Junction Spine* 2022;13(02):204–211
- Rigamonti D, Liem L, Sampath P, et al. Spinal epidural abscess: contemporary trends in etiology, evaluation, and management. *Surg Neurol* 1999;52(02):189–196, discussion 197
- Sahu KK, Chastain I. A rare case of holocord spinal epidural abscess. *QJM* 2020;113(04):302–303
- Davis DP, Salazar A, Chan TC, Vilke GM. Prospective evaluation of a clinical decision guideline to diagnose spinal epidural abscess in patients who present to the emergency department with spine pain. *J Neurosurg Spine* 2011;14(06):765–770
- Davis DP, Wold RM, Patel RJ, et al. The clinical presentation and impact of diagnostic delays on emergency department patients with spinal epidural abscess. *J Emerg Med* 2004;26(03):285–291
- Xu T, Du Y, Guo J, et al. Extensive spinal epidural abscess resulting in complete paraplegia treated by selective laminectomies and irrigation. *Orthop Surg* 2022;14(09):2380–2385
- Shikano K, Ishii D, Umimura T, et al. Spondylodiscitis and spinal epidural abscess related to long-term placement of an airway stent for malignant central airway obstruction. *Thorac Cancer* 2020;11(08):2343–2346
- Arko L IV, Quach E, Nguyen V, Chang D, Sukul V, Kim BS. Medical and surgical management of spinal epidural abscess: a systematic review. *Neurosurg Focus* 2014;37(02):E4
- Göre B, Yenigün EC, Cevher ŞK, Çankaya E, Aydın N, Dede F. IGA nephropathy and spinal epidural abscess after COVID-19 infection: a case report. *Future Virol* 2022;17(09):611–615
- Gupta KM, Tay KY. Spinal epidural abscess in an infant presenting as fever and respiratory distress. *Pediatr Emerg Care* 2020;36(11):e649–e650
- Heusner AP. Nontuberculous spinal epidural infections. *N Engl J Med* 1948;239(23):845–854
- Hirai N, Kasahara K, Yoshihara S, et al. Spinal epidural abscess caused by non-typhoidal Salmonella: a case report and literature review. *J Infect Chem/other* 2020;26(10):1073–1077
- Mor YS, Rizwan A, Frank A. Paraplegia from a spinal epidural abscess caused by pasteurilla multocida. *Cureus* 2021;13(06):e15477
- Baker AS, Ojemann RG, Swartz MN, Richardson EP Jr. Spinal epidural abscess. *N Engl J Med* 1975;293(10):463–468
- Munasinghe BM, Pathirage N, Hameed MS, Hapuarachchi CT. Pus in spinal needle: diagnosis and management of a long-segment spinal epidural abscess. *Case Rep Infect Dis* 2021;2021:9989847 (

- Erratum in: Case Rep Infect Dis. 2021 Aug 11;2021:9893619. PMID: 34007497; PMCID: PMC8100421)
- 37 Polsky Z, Dowling SK, Jacobs WB. Just the facts: risk stratifying non-traumatic back pain for spinal epidural abscess in the emergency department. *CJEM* 2020;22(06):753–755
 - 38 Vig KS, Amarante M, Hutchinson I, Lawrence JP. Pediatric Group A streptococcal spinal epidural abscess presenting with recurrent symptoms of viral illness: an operative case report. *N Am Spine Soc J* 2021;6:100067
 - 39 Scalia G, Marrone S, Paolini F, et al. Spinal epidural abscess due to acute pyelonephritis. *Surg Neurol Int* 2022;13:159
 - 40 Last's Anatomy. 12th edition. England: Churchill Livingstone. 2011. ISBN:0702033944
 - 41 Ma CX, Pan WR, Liu ZA, Zeng FQ, Qiu ZQ, Liu MY. Anatomia linfática profunda do membro superior: estudo anatômico e implicações clínicas. *Ana Anat* 2019;223:32–42
 - 42 Radkowski CA, Richards RS, Pietrobon R, Moorman CT. Estudo anatômico da veia cefálica na abordagem do ombro deltopeitoral. *Clin Orthop Relat Res* 2006;442:139–142
 - 43 Van Baarsel ED, Kesbeh Y, Kahf HA, Patel V, Weng B, Sutjita M. Spinal epidural abscess secondary to gram-negative bacteria: case report and literature review. *J Community Hosp Intern Med Perspect* 2020;10(01):60–64
 - 44 Kharbat AF, Cox CT, Purcell A, MacKay BJ. Methicillin-resistant *Staphylococcus aureus* spinal epidural abscess: local and systemic case management. *Cureus* 2022;14(03):e22831
 - 45 Ammar AA, Hamad MK, Obeidallah MS, Kobets AJ, Lee SK, Abbott IR. Successful treatment of pediatric holo-spinal epidural abscess with percutaneous drainage. *Cureus* 2022;14(05):e24735
 - 46 Chaker AN, Bhimani AD, Esfahani DR, et al. Epidural abscess: a propensity analysis of surgical treatment strategies. *Spine* 2018; 43(24):E1479–E1485
 - 47 Papaetis GS, Petridis TA, Karvounaris SA, Demetriou T, Lykoudis S. *Bacteroides fragilis* bacteremia complicated by spondylodiscitis, spinal epidural abscess, and sepsis: a case report. *Am J Case Rep* 2022;23:e936179
 - 48 Fujita M, Ueno T, Horiuchi M, et al. *Campylobacter coli* infection causes spinal epidural abscess with Guillain-Barré syndrome: a case report. *BMC Neurol* 2022;22(01):9
 - 49 Davis DP, Wold RM, Patel RJ, et al. Spinal epidural abscess: diagnosis, management, and outcomes. *West J Emerg Med* 2014;15(01):1–8
 - 50 Nitinai N, Punnichet M, Nasomsong W. Fatal cervical spinal epidural abscess and spondylodiscitis complicated with rhombencephalitis caused by *klebsiella pneumoniae*: a case report and literature review. *Cureus* 2021;13(12):e20100
 - 51 Horiya M, Anno T, Kawada M, et al. Pyogenic psoas abscess on the dorsal side, and bacterial meningitis and spinal epidural abscess on the ventral side, both of which were induced by spontaneous discitis in a patient with diabetes mellitus: a case report. *J Diabetes Investig* 2021;12(07):1301–1305
 - 52 Mallik J, Motiani V, Pai MG. Spinal epidural abscess post spinal anesthesia: an uncommon complication of a common procedure. *Asian J Neurosurg* 2020;15(03):730–732
 - 53 Lodhi FAK, Shogren SL, Haque N, Ishaq M, Rehman A. Spinal epidural abscess due to *Pasteurella multocida* infection. *IDCases* 2020;21:e00801
 - 54 Altdorfer A, Gavage P, Moerman F. *Aggregatibacter aphrophilus* spinal epidural abscess. *BMJ Case Rep* 2020;13(07):e235320
 - 55 Brunasso L, Basile L, Gerardo Iacopino D, et al. All that glitters is not gold: a spinal epidural empyema following epidural steroid injection. *Surg Neurol Int* 2020;11:240
 - 56 Plancha da Silva T, Amaral Silva M, Santos Boaventura S, Castro Martins M, Teixeira Duro S, Carvalho F. Spinal cord disorder due to spinal epidural abscess secondary to thoracic facet joint septic arthritis—a rare case with a surprising evolution. *Spinal Cord Ser Cases* 2020;6(01):102
 - 57 Maiese A, Volonnino G, Viola RV, et al. A rare case of Spinal Epidural Abscess following mesotherapy: a challenging diagnosis and the importance of clinical risk management. Considerations concerning uncommon risk factor for development of Spinal Epidural Abscess and its prevention. *Clin Ter* 2020;170(01):e15–e18