


# Use of 3-D navigation to target the site of autologous blood installation for lung volume reduction in bullous emphysema

Chronic Respiratory Disease  
Volume 17: 1–4  
© The Author(s) 2020  
Article reuse guidelines:  
sagepub.com/journals-permissions  
DOI: 10.1177/1479973120903556  
journals.sagepub.com/home/crd  


Juergen Hetzel<sup>1</sup>, Michael Boeckeler<sup>1</sup>, Richard A Lewis<sup>2</sup>,  
Marius Horger<sup>3</sup> and Maik Haentschel<sup>1</sup> 

## Abstract

Bronchoscopic lung volume reduction (BLVR) using intrabullous autologous blood instillation has been reported in single cases where other techniques are not possible. We present the use of three-dimensional navigation to instill autologous blood into emphysematous bullae for BLVR. A 62-year-old man presented with increasing dyspnea, due to emphysema with a conglomerate of giant bullae with two particularly large bullae. Surgical treatment was refused, so bronchoscopic autologous blood instillation into the bronchial segment leading to the large bullae was attempted, but was unsuccessful; blood failed to penetrate into the bullous cavity. Dyspnea worsened over the following year. We therefore performed another bronchoscopy and punctured a large bulla with a needle and created a tunnel from the central airways. Puncture position and direction were determined using a prototype of an electromagnetic navigation system. Under fluoroscopic guidance, a catheter was placed via the tunnel into the bulla and blood was instilled. This resulted in an almost complete shrinkage of the bullae, reduction of residual volume, and marked improvement in dyspnea within 4 months. To our knowledge, this is the first reported case of successful BLVR by navigated bronchoscopy with transbronchial puncture, dilatation, and autologous blood instillation into a giant bulla.

## Keywords

Lung volume reduction, lung emphysema, 3-D navigation, bronchoscopic technique, hyperinflation

Date received: 11 October 2019; accepted: 3 January 2020

## Introduction

Lung volume reduction is an emerging technique to improve breathing mechanics by reducing hyperinflation in patients with severe lung emphysema. For giant bullae, surgical bullectomy represents the current standard. Bronchoscopic intrabullous autologous blood instillation under fluoroscopy guidance has been described in case reports.<sup>1,2</sup> We present the first case of this technique using three-dimensional (3-D)-navigated puncture and dilatation of the bronchial wall orifice to gain direct access to the cavity of the giant bulla.

<sup>1</sup> Department of Medical Oncology and Pneumology, University Hospital of Tuebingen, Tuebingen, Germany

<sup>2</sup> NPARU, University of Worcester, Worcester, UK

<sup>3</sup> Department of Diagnostic and Interventional Radiology, University Hospital of Tuebingen, Tuebingen, Germany

### Corresponding author:

Juergen Hetzel, Department of Medical Oncology and Pneumology, University Hospital of Tuebingen, Otfried-Mueller-Str, 1472076, Tuebingen, Germany.

Email: juergen.hetzel@med.uni-tuebingen.de



**Table 1.** Course of lung function before, after the first (calculated), and after the second (3-D-navigated) bronchoscopic blood instillation.

Lung function testing	Before first LVR	Before 3-D-LVR	Three months after 3-D-LVR
FEV1—liters—(% of pred. value)	0.72 (19.9)	0.55 (17.4)	0.66 (20.6)
ITGV—liters—(% of pred. value)	6.97 (188)	8.61 (245)	7.02 (199)
RV—liters—(% of pred. value)	6.28 (256)	8.25 (347)	6.81 (283)
DLCOC SB—mmol/min/kPa—(% of pred. value)	1.89 (18.3)	n.m.	n.m.
CAT—points	26	32	28 (after 1 month) <sup>o</sup>

LVR: lung volume reduction; FEV1: forced expiratory volume in 1 s; ITGV: intrathoracic gas volume; RV: residual volume; pred. value: predicted value; 3-D-LVR: 3-D-navigated lung volume reduction; DLCOC SB: diffusion capacity for carbon monoxide; CAT: COPD assessment test; n.m.: not measurable; COPD: chronic obstructive pulmonary disease.

<sup>o</sup>CAT value 3 month after 3-D-LVR not measured.

## Case report

A 62-year-old ex-smoker with chronic obstructive pulmonary disease (COPD), Global initiative for chronic Obstructive Lung Disease (GOLD) stage 4/D, had increasing dyspnea. Imaging showed heterogeneous centrilobular emphysema with two large bullae in the right lower lobe (Table 1). The patient was on maximal conservative therapy.

Interdisciplinary discussion rated surgical lung volume reduction as technically possible but associated with a high periprocedural risk with regard to patient's lung morphology and function. Other lung volume reduction techniques such as coiling (not applicable in bullae), vapor (limited to upper lobe disease), or valves (incomplete interlobar fissure) were not suitable. The patient refused a surgical approach but consented to an individualized medical treatment with intrabullous autologous blood instillation. This approach is in accordance with the Professional Code for Physicians in Germany. Therefore, no additional approval by the ethics committee was necessary.

We performed flexible bronchoscopy and selectively intubated the bronchus leading to the bullous area as identified by CT imaging; 150 ml of autologous blood was instilled without prior air aspiration to reduce the risk for pneumothorax. No complications occurred. Follow-up CT showed that the instilled blood had not entered the bullae but had accumulated in adjacent lung tissues.

Over the course of the next 9 months, the patient's dyspnea had worsened with increasing hyperinflation (Figure 1(a) and Table 1). The patient again refused a surgical bullectomy, other bronchoscopic approaches were still not possible and the patient gave informed consent to an individualized medical treatment.

We repeated the procedure using CT and a combined electromagnetic and visual navigation

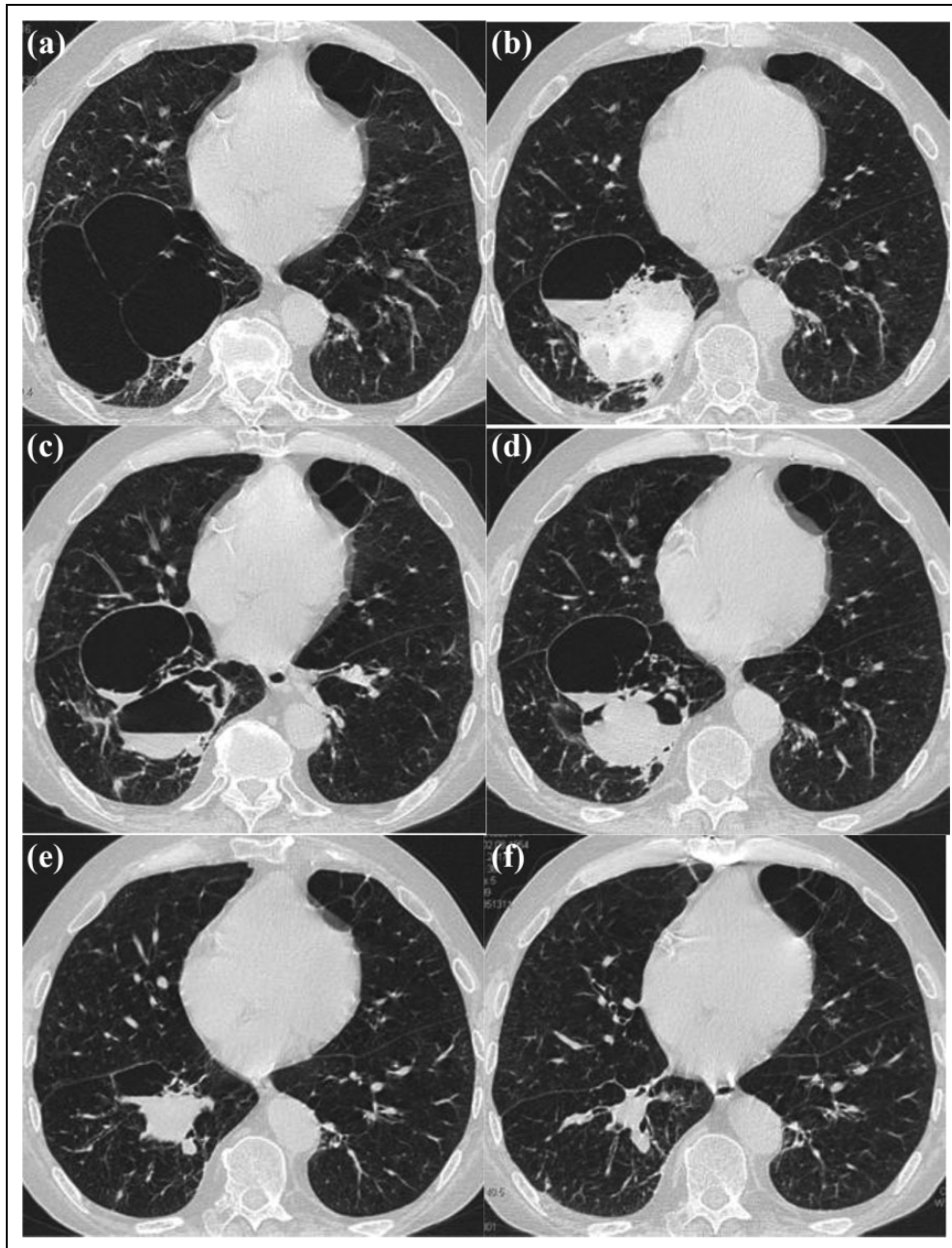
guidance system (XBASE<sup>®</sup>; Richard Wolf, Germany) to target an appropriate puncture site on the bronchial wall. Flexible bronchoscopy was performed, and the predetermined bronchial site was successfully reached (Figure 2).

The navigation probe was then removed from the bronchoscope and a 19 g needle (eXcelon 19ga; Boston Scientific, Marlborough, MA, USA) was used to penetrate through the bronchial wall into the bulla. Intrabullous needle positioning was confirmed fluoroscopically by the use of radiocontrast. The needle sheath was pushed into the bulla to dilate the transbronchial orifice. The needle was then removed and a 5.2F catheter (SuperTorque Plus; Cordis, Santa Clara, CA, USA) was placed into the bulla via the transbronchial route. Three 50-ml aliquots of autologous blood were injected into the bulla under fluoroscopic control without prior air aspiration, assuming that tunneling between the bulla and the central airways allowed pressure equalization. The catheter was removed without any significant leakage of blood back into the bronchus and without any further complication (Figure 1(b)).

The patient recovered within a few days with a slightly elevated temperature. Dyspnea rapidly decreased with an immediate four-point drop in the COPD assessment test (Table 1). Over the following 3 months, this improvement of dyspnea was maintained, lung function improved (Table 1), and the bullae almost completely shrunk (Figure 1). Unfortunately, the patient died of an influenza infection 136 days after the procedure, which was considered unrelated to the procedure.

## Discussion

This is the first report of 3-D-navigated bronchoscopic transbronchial puncture of a pulmonary bulla via the central airways and intrabullous instillation of



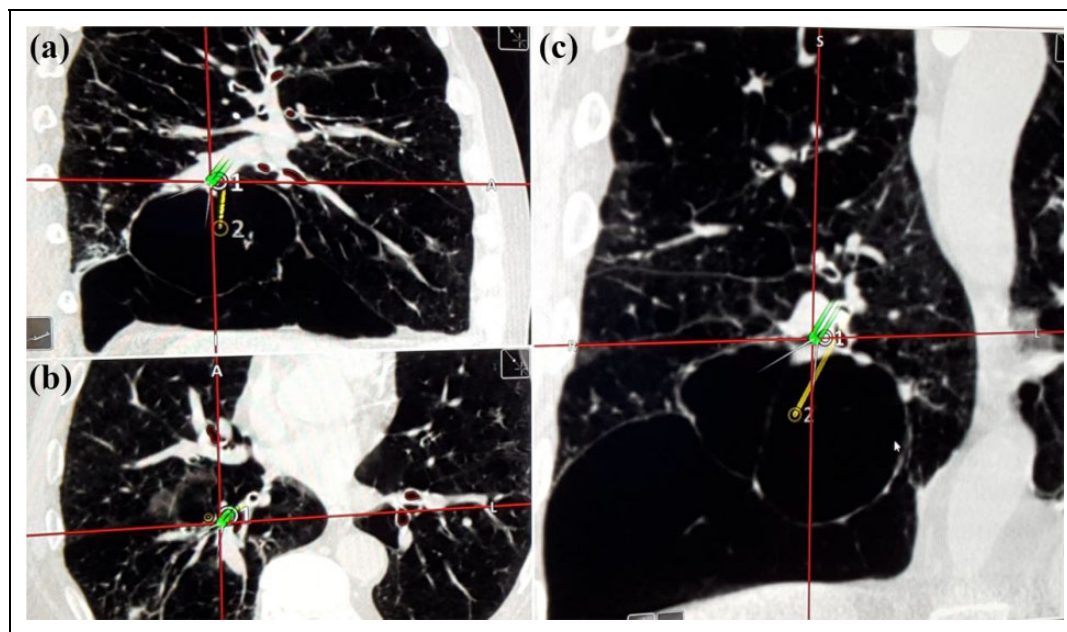
**Figure 1.** Thoracic CT on the same level pre-interventional (a) and 2 h (b), 7 days (c), 17 days (d), 38 days (e), and 126 days (f) after intervention, demonstrating the shrinkage of the three bullae ( $11 \times 12 \text{ cm}^2$ ).

autologous blood, resulting in significant lung volume reduction and improvement of dyspnea.

Bullous emphysema is a challenging problem in COPD patients. Current therapeutic approaches include surgical bullectomy and endoscopic lung volume reduction using valves. Bronchoscopic lung volume reduction following instillation of autologous blood has been demonstrated in case reports<sup>1–3</sup> or small case series.<sup>4</sup> Our case describes a new approach

taken when transbronchial autologous blood instillation had failed to deposit the blood within the bullae.

This new technique is clearly less invasive than surgery and should be considered in patients with large bullae who are unsuitable for current standard techniques. Especially, the combination with a 3-D controlled navigation, which allows a targeted transparenchymal instillation of the blood into the bulla, even if access via the bronchial system is not possible,



**Figure 2.** HRCT-based 3-D navigation for bulla puncture. Based on a previous HRCT, target areas for the bulla puncture (marked as 1) and the center of the largest bulla (marked as 2) were predefined. The light green double line presents tip of the navigation probe in its actual position in the coronal (a), transverse (b), and sagittal (c) plane reaching the predefined puncture point of the bronchus (1). The yellow line marks the shortest track to the target area (2)—the center of the bulla. HRCT: high-resolution computed tomography.

could significantly expand the application spectrum of blood instillation for lung volume reduction. In principle, any 3-D navigation system could be used for targeted puncture of a bulla. Whether the different systems differ in their success rate is currently unclear. In our opinion, important requirements for a successful navigation are a high-quality contrast enhanced chest CT (layer thickness maximum 1 mm), precise knowledge of the anatomy, and competence in handling the navigation system.

However, procedural aspects are debatable. While we did not aspirate air after tunneling due to the concern that a pneumothorax may develop due to the rapid volume change other colleagues performed an air aspiration and instilled only 5 ml of blood while we instilled 150 ml.

Certainly, this promising result requires further evaluation addressing technical aspects and the overall success and complication rate.


#### Declaration of conflicting interests

The author(s) declared the following potential conflicts of interest with respect to the research, authorship, and/or publication of this article: JH reports grants from Richard and Annemarie Wolf Foundation, during the conduct of the study, the other authors have nothing to disclose.

#### Funding

The author(s) received no financial support for the research, authorship, and/or publication of this article.

#### ORCID iD

Marius Horger Maik Haentschel  <https://orcid.org/0000-0002-0610-1959>

#### References

1. Kanoh S, Kobayashi H, and Motoyoshi K. Intrabullous blood injection for lung volume reduction. *Thorax* 2008; 63(6): 564–565.
2. Kemp SV, Zoumot Z, and Shah PL. Three-year follow-up of a patient with a giant bulla treated by bronchoscopic intrabullous autologous blood instillation. *Respiration* 2016; 92(4): 283–284.
3. Hetzel J, Spengler W, Horger M, et al. Incidental lung volume reduction following fulminant pulmonary hemorrhage in a patient with severe emphysema. *Lung* 2015; 193(3): 429–432.
4. Zoumot Z, Kemp SV, Caneja C, et al. Bronchoscopic intrabullous autologous blood instillation: a novel approach for the treatment of giant bullae. *Ann Thorac Surg* 2013; 96(4): 1488–1491.