

# The application of Integra in a challenging context

Fabio Nicoli<sup>1,2</sup>, Ivonne Rampinelli<sup>1,3</sup> and Yvette Godwin<sup>1,2</sup>

## Abstract

Integra dermal regeneration template is commonly used in the developed world. This case history documents the application of Integra for the first time in Gaza, Palestine. This single case history illustrates how a tried and tested technique can be imported to a more challenging environment. The emphasis in this case history is not to recount a well-known technique of Integra application but to outline how the environment has to be prepared and the surgeon adapt to minimise risk and maximise the chances of success. This first application of Integra in Gaza illustrates the importance of starting with simple cases when a technique is being piloted in an austere environment. Patient selection, local theatre set up, staff and surgical technique, as well as patient follow-up facilities, all need consideration before doing the first trial of even this most established of products in a new environment.

## Keywords

Integra, dermal substitute, dermal replacement, burns reconstruction, Gaza, conflict zone

## Lay Summary

Integra dermal regeneration template is a material that can be applied to resurface areas of scarring and burns contracture. The template consists of two layers: the upper layer is a Silone sheet that acts to protect the deeper layer that consists of a protein matrix. Once an area of troublesome scar has been surgically removed, it leaves a gap, or defect. The Integra can be applied to the defect and, providing the areas has a good blood supply, is free of bacteria and immobilised, a new blood supply enters the protein matrix. This allows the migration of cells, called fibroblasts, into the matrix. The fibroblasts will use the matrix as scaffolding to lay down new protein and eventually replace the matrix.

The resultant structure is called a 'neodermis'. The protective silicone sheet can then be removed and replaced by a conventional, very thin skin graft. The advantage to applying this Integra two-stage reconstruction technique to a scarred area is that the reconstruction will be elastic and expand. In children, this allows for growth without recurrence of contractures across joints.

The application of Integra is a tried and tested technique. This case explains how, and with due care, it can be used for severe scarred cases in a challenging environment provided careful technique and follow-up are respected.

<sup>1</sup>Médecins Sans Frontières, Gaza Clinic, Thaoura Street, Gaza City, Palestine

<sup>2</sup>Consultant Plastic Reconstructive surgeon, Italy

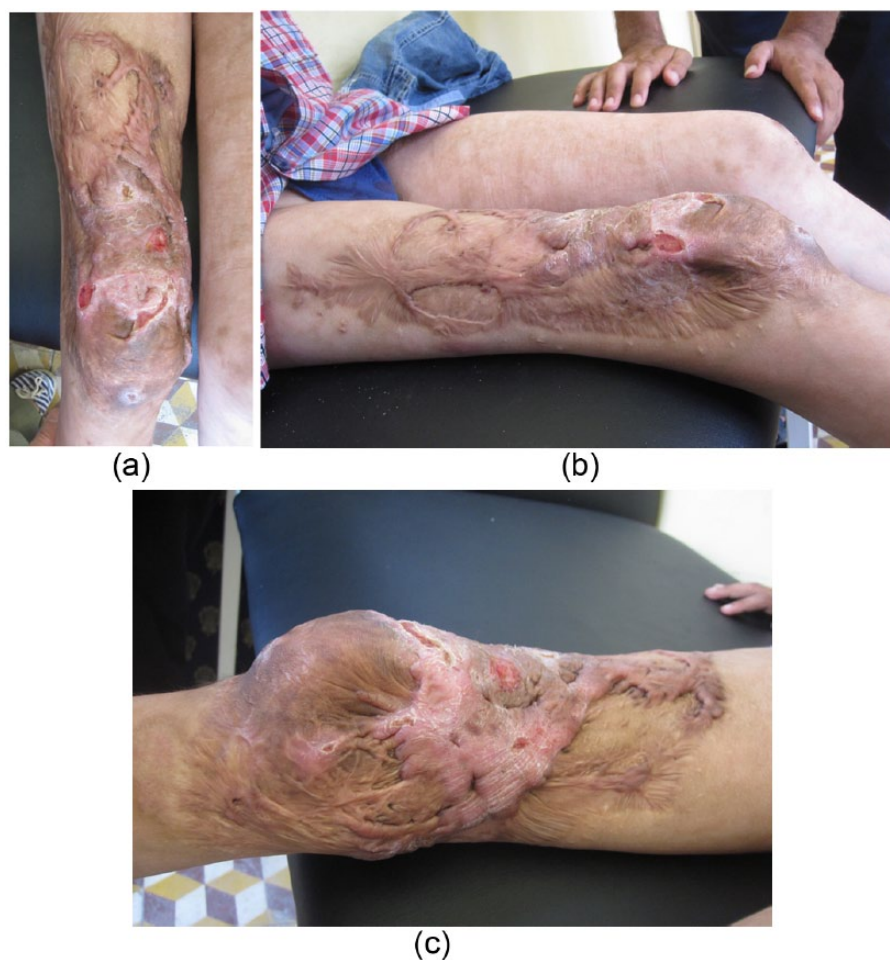<sup>3</sup>Consultant Anaesthetist, Chile

## Corresponding author:

Yvette Godwin, Médecins Sans Frontières, Gaza, Palestine.

Email: ygodwin@hotmail.com





**Figure 1.** (a) Anterior, (b) lateral and (c) medial views of scarred right thigh and peri-patellar region 18 months after a de-gloving injury and partial take of a SSG reconstruction. Multiple unstable, open areas and crypts are seen within the scar tissue.

## Introduction

The following case history outlines what we believe to be the first application of Integra dermal regeneration template in Gaza, Palestine. We outline the logistics of introducing this product in this challenging environment.

## Case history

Four sheets of Integra dermal regeneration template (Integra, LifeSciences Corporation, USA)<sup>1,2</sup> were generously donated to the senior author in July 2015 for reconstruction of burns and trauma patients of the Gaza strip. This product had not been applied locally in the country before due to logistic reasons as well as product cost.

Logistic challenges were as follows: (1) hygiene: the product needs to be applied in a

unit with sufficient standards to decrease the risk of infection; (2) outpatient care: monitoring and follow-up after application of the dermal regeneration template; (3) patient compliance: acceptance of a timed, two-stage procedure, to return for regular dressings and accept the immobilisation for 14–21 days. After four years of regular mission deployment in Gaza, it was considered that the environment was right for us to attempt using the dermal regeneration template.

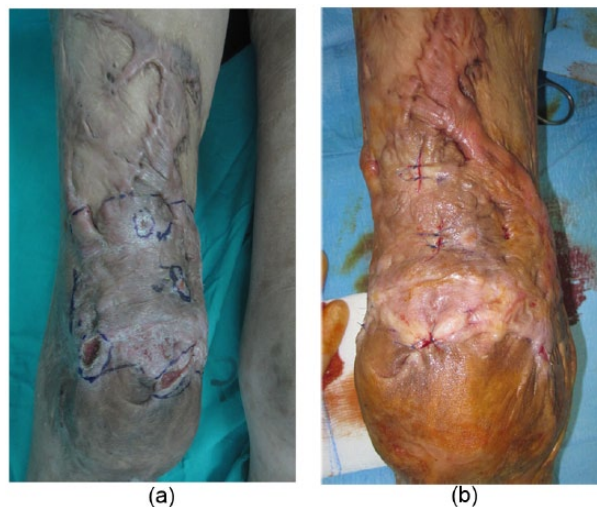
The options were to use Integra for reconstruction following release of a contracture or for a defect created after excision of scar tissue. In the mission setting, it is imperative to manage and resolve any surgical complications before you leave. The defect created therefore had to be a graftable bed to allow a simple ‘plan B’ reconstruction should the Integra fail.

The patient chosen was an 8-year-old boy involved in a road traffic accident. Figure 1a–c

illustrates scar tissue on the right thigh and peripatellar areas 18 months after a severe de-gloving injury. The patient did receive acute local treatment (debridement and split thickness graft [SSG]) but following partial loss of the graft, most of the wound had healed by secondary intention. Despite the application of pressure garments, the resultant area demonstrated hypertrophic scarring with some areas being painful and extending beyond the site of injury consistent with keloid scarring. The child had a history of repeated episodes of purulent discharge from crypts within the scar tissue and reports of local hospital admission for drainage of crypt abscesses and antibiotic therapy. The patient presented to our clinic with open, unstable areas within the scar that were contaminated with swab-proven staphylococcus aureus, sensitive to co-amoxiclav. The rationale for the application of Integra in this case was to remove unstable scar and crypts that were causing ongoing issues, minimise further donor site morbidity, improve cosmesis and provide a reconstruction with superior elasticity to accommodate growth.

The first surgical goal was to create a clean surgical field in preparation for Integra application. Visible crypts were excised and open areas debrided, removing potential foci of contamination/infection (Figure 2a, b). Once the area was clean, and bacterial swab negative, the remaining unstable, unaesthetic scar would be excised and resurfaced with a two-stage, standard, Integra application. This would be done as an outpatient with regular review.

Despite our careful planning to decrease the risk of Integra loss, one factor not bargained for was the weather! Gaza had the warmest summer on record for 80 years with temperatures topping 45°C during the day. Manufacturer instructions state that the dermal regeneration template must be kept between 2°C and 30°C. During this period in Gaza, electricity was rationed with households receiving a supply of 4 hours per day. Fortunately, our pharmacy had air-conditioning with a 24 hours back-up generator supply. Although this allowed us to store the product, the ambient temperature during transfer of the product and application would have been well above the recommended storage temperature. For this reason, the surgical plan was changed to cleaning up the boy's open areas within the scar tissue at one mission and two months later, on the following mission, a second surgeon (first author), would attempt application of the dermal regeneration matrix.



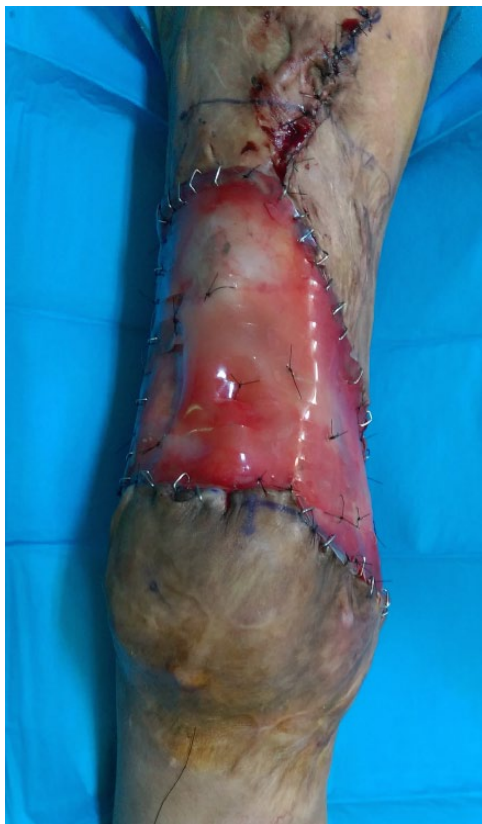**Figure 2.** (a) Zone marked out where patient has experienced previous episodes of infection and crypt abscesses formation. Visible patches of unstable scar with open wounds. (b) Immediate postoperative view after excision of unstable areas.

## Method

The Integra was applied in accordance with the manufacturer guidelines<sup>1</sup> while also bearing in mind a future realistic protocol for the unit that was in keeping with facilities available (materials, staff and inpatient and outpatient hospital care). To maximise success, the following five features of Integra application needed to be respected: (1) preparation of clean, well debrided vascular recipient bed and meticulous haemostasis; (2) postoperative immobilisation; (3) adequate timescale to allow neovascularisation prior to skin grafting; (4) some form of antibacterial dressing; and (5) regular review and two theatre episodes.

The scar was excised above and medial to the patella. After meticulous haemostasis, a single sheet of unmeshed, Integra dermal matrix was applied. In the absence of 0.5% silver nitrate solution or topical sulfamylon, gauze dressings were soaked in 10% aqueous povidone iodine solution, squeezed out well and applied as an antiseptic dressing layer. Dry, fluffed gauze and an above-knee plaster of Paris back-slab were applied. Both preoperative and intraoperative swabs were free of bacterial growth. Five days of prophylactic co-amoxiclav was prescribed in view of the risk related to the previous history of staphylococcus aureus contamination and the risk of infection in the postoperative outpatient environment. The





**Figure 3.** The appearance of Integra dermal regeneration template two weeks after placement. The Integra is unmeshed and applied with peripheral staples Central quilting sutures of 50 nylon to conform the matrix to the peri-patellar region.

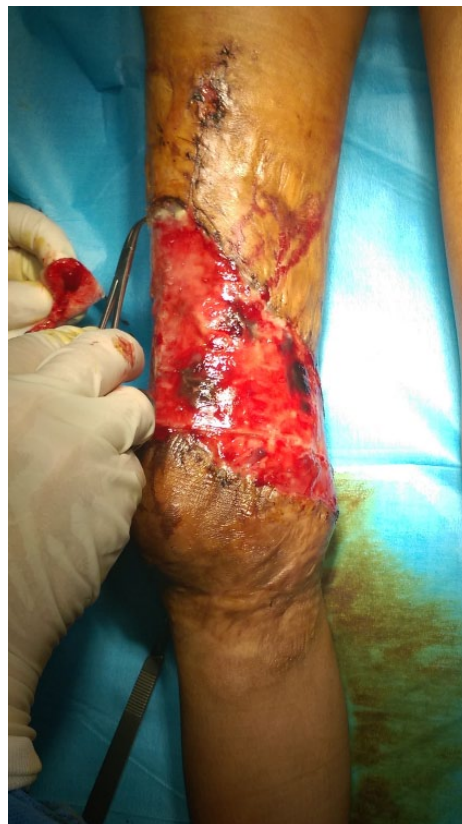patient was kept on strict bed rest at home and brought to clinic every fourth day for change of dressings and review.

### Result

Figure 3 illustrates the appearance of the Integra at two weeks. Three weeks from the placement of the Integra, the silicone membrane was removed (Figure 4) and a hand-meshed, thin split thickness graft (0.2 mm) applied to the surface of the neodermis. The plaster back-slab was maintained for a further ten days and then the knee mobilized as soon as the split thickness graft was considered stable. Figure 5a–d illustrates the patient appearance, the elasticity of the reconstruction and ease of leg movement six months after the Integra application.

### Conclusion

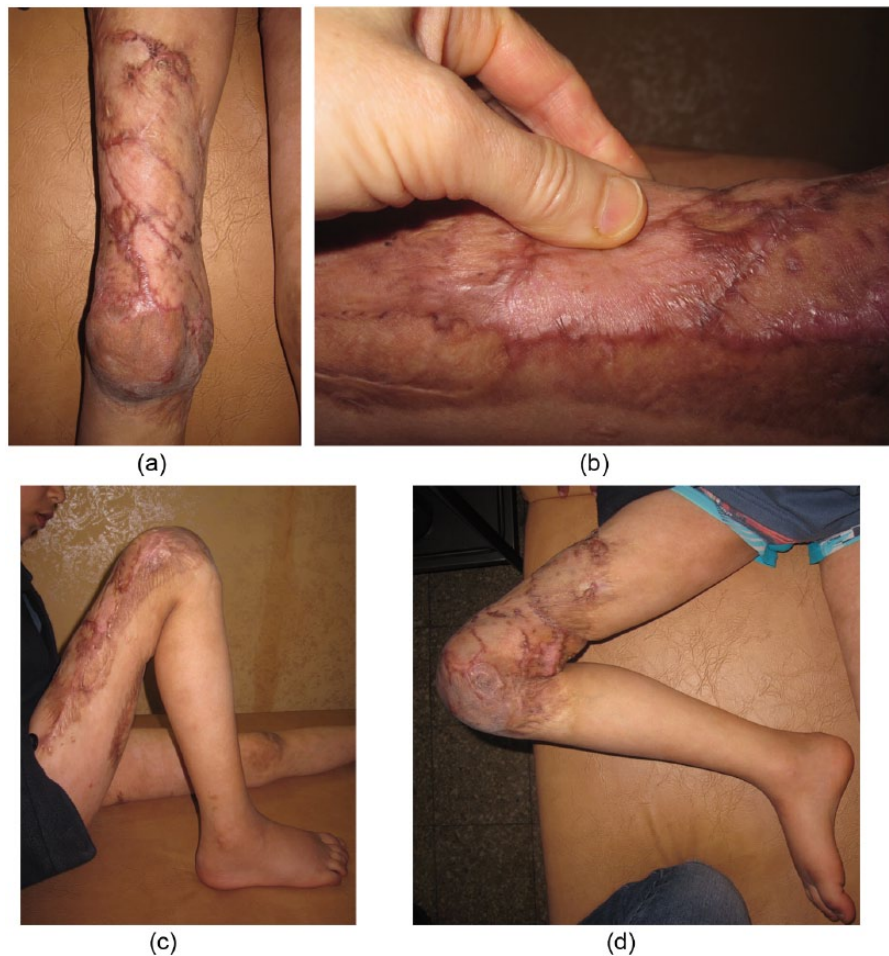The above report outlines our first application of Integra with Médecins Sans Frontières (MSF) in



**Figure 4.** At three weeks the silicone membrane is removed to expose the peach-coloured, vascularized neodermis. Note two small anterior areas that have not vascularized anteriorly and remain deep purple.

Gaza. Additional features, that are now regularly used with the Integra application, such as mechanically meshing the Integra<sup>3</sup> or the application of vacuum assisted dressings<sup>4</sup>, are not considered at this early point in the evolution of a clinical protocol. The priority was getting Integra to work in the context we find ourselves in at present, using the equipment we currently have available. Integra has been shown to be applicable both for complex wounds<sup>3</sup> and in the military context.<sup>4</sup> Previous publications can supply us with future technical tips that can be taken forward for future applications but this was our first trial of the product.

In addition to the safe application of the product, cost and supply need to be considered for the future. At least at this point, we can optimistically say, if available, we can make this work in our current context and on an outpatient basis. The advantage for the patient is a quality reconstruction that confers elasticity and some improved cosmesis. The long-term advantage to both the charity and the patient would be fewer recurrent hospital episodes



**Figure 5.** Six months post surgery: (a) the appearance of the reconstruction; (b) the elasticity and (c, d) the ease of movement of the limb.

and therefore reduction of overall inpatient length of stay and cost.<sup>5</sup>

Following this case, we feel confident to apply this material in the context of the Gaza mission. Integra is clearly a robust product.<sup>3,4,6</sup> With the backing of a good clinical team, regular dressing, compliance at home and good physiotherapy follow-up, this technique is applicable with outpatient follow-up in Gaza. Summer season planning is best avoided. Three further cases were performed with good results later that autumn. We can add Integra to our reconstructive options for this patient population that can present with severe injuries and a paucity of good donor sites.

### Patient consent

Written informed consent was obtained from the patient's guardian for publication of this case report and any accompanying images. A copy of

the written consent is available for review by the Editor-in-Chief of this journal.

### Acknowledgements

Many thanks to all the MSF Gaza team; the nursing staff run the theatres, as well as conduct the preoperative and postoperative clinics. The Physiotherapy department performs rehabilitation to the highest standard. The hygienists maintain our instruments and give us the clean theatre environment. All my medical colleagues are local staff. None of this reconstructive work is possible without their dedicated care and the support of the MSF in providing the Gaza mission facility.

### Declaration of conflicting interests

The authors declared no potential conflicts of interest with respect to the research, authorship, and/or publication of this article.

### Funding

This research received no specific grant from any funding agency in the public, commercial, or not-for-profit sectors.

## References

1. Integra. *Integra Dermal Regeneration template: Instruction booklet*. Plainsboro, NJ: Integra LifeSciences Corporation, 2011.
2. Burke JF, Yannas IV, Quinby WC Jr, et al. Successful use of a physiologically acceptable artificial skin in the treatment of extensive burn injury. *Ann Surg* 1981; 194: 413–428.
3. Muangman P, Engrav LH, Heimbach DM, et al. Complex wound management utilizing an artificial dermal matrix. *Ann Plast Surg* 2006; 57: 199–202.
4. Helgeson M, Potter BK, Evans KN, et al. Bioartificial dermal substitute: A preliminary report on its use for the management of complex combat-related soft tissue wounds. *J Orthop Trauma* 2007; 21: 394–399.
5. Ryan C, Schoenfeld DA, Malloy M, et al. Use of Integra artificial skin is associated with decreased length of stay for severely injured adult burn survivors. *J Burn Care Rehabil* 2002; 23: 511–517.
6. Heimbach DM, Warden GD, Luterman A, et al. Multicenter postapproval clinical trial of Integra dermal regeneration template for burn treatment. *J Burn Care Rehabil* 2003; 24: 42–48.

### How to cite this article

Nicoli F, Rampinelli I and Godwin Y. The application of Integra in a challenging context. *Scars, Burns & Healing*, 2016. DOI: 10.1177/2059513116672789.