

Asymptomatic Penetration of Oculomotor Nerve by Internal Carotid-Posterior Communicating Artery Aneurysm Presenting Pure Acute Subdural Hematoma: A Case Report

Ryota SASAKI,¹ Yasushi MOTOYAMA,¹ Ichiro NAKAGAWA,¹ Young-Su PARK,¹
and Hiroyuki NAKASE¹

¹Department of Neurosurgery, Nara Medical University, Kashihara, Nara, Japan

Abstract

To present a unique case of the internal carotid artery-posterior communicating artery (ICA-PcomA) aneurysm penetrating the oculomotor nerve presenting a pure acute subdural hematoma (ASDH) without any oculomotor dysfunction. A 71-year-old woman presented with a sudden headache and drowsiness. She had no history of head trauma and did not manifest any neurological deficits including oculomotor nerve palsy. Computed tomography (CT) of her head revealed left ASDH. Subsequent CT angiography showed an aneurysm originating from the left ICA with an inferior projection having continuity with the hematoma. Intraoperative inspection revealed ASDH observed mainly in middle fossa and no subarachnoid hemorrhage, while the aneurysm was confirmed to split the oculomotor nerve and to be fixed with the middle fossa. The aneurysm was obliterated by direct clip application and the patient's postoperative course was uneventful. Oculomotor nerve palsy is an important warning sign of imminent rupture of ICA-PcomA aneurysm. However, we should consider that the ICA-PcomA aneurysm could rupture causing ASDH without any oculomotor nerve palsy, even though the aneurysm penetrated the oculomotor nerve.

Key words: internal carotid artery-posterior communicating artery aneurysm, oculomotor nerve, pure acute subdural hematoma

Introduction

Oculomotor nerve palsy is a typical sign to warn the risk of imminent rupture of internal carotid-posterior communicating artery (ICA-PcomA) aneurysm. High incidence of oculomotor nerve palsy associated with ICA-PcomA aneurysms relates to the close proximity of the artery and nerve in the subarachnoid space of the basal cistern, where the oculomotor nerve is susceptible to compression just before it enters the dural coverings of the cavernous sinus. Although it is extremely rare, ICA-PcomA aneurysm has been reported to penetrate oculomotor nerve. We herein present a rare case of ICA-PcomA aneurysm penetrating oculomotor nerve, in which the patient did not present with oculomotor nerve palsy, even though the aneurysm was ruptured and demonstrated acute subdural hematoma (ASDH). ASDH is rarely found in association with a ruptured cerebral aneurysm,

occurring in 0.5–7.9% of cases.¹⁾ Interestingly, in this case, intraoperative findings demonstrated that there were not only subarachnoid hemorrhage (SAH) but also subdural hematoma. We discuss the mechanism of pure ASDH formation caused by ICA-PcomA aneurysm penetrating oculomotor nerve.

Case Report

The patient was a 71-year-old woman with a past history of hypertension and a dural arteriovenous fistula in the cervical spine, which was treated and cured with endovascular coil embolization 21 years earlier. She presented with sudden onset of a severe headache and consciousness disturbance. She had no history of head trauma, coagulation deficiency, and current use of illicit drugs, but magnetic resonance imaging (MRI) of the head that she underwent because of dizziness demonstrated a saccular aneurysm of 5.5 mm × 4.5 mm in the left internal carotid artery (ICA) 1 month before the ictus. On admission, her consciousness was mildly disturbed (Glasgow Coma Scale: eye opening 3, verbal response 5, motor response 6), but no neurological deficits,

Received July 5, 2017; Accepted December 15, 2017

Copyright© 2018 by The Japan Neurosurgical Society
This work is licensed under a Creative Commons Attribution-NonCommercial-NoDerivatives International License.

including no oculomotor palsy, were observed. She had no meningeal irritation signs. Initial CT of the head showed an ASDH in the left middle fossa and convexity without SAH or intracerebral hemorrhage (ICH) (Figs. 1A and B). Three-dimensional CT angiography (3DCTA) demonstrated the aneurysm in the left ICA-PcomA that was previously detected, but no vascular malformation was indicated. There was no other evidence of causative pathology for the ASDH (Figs. 1C and D).

Because rupture of the aneurysm was expected, neck clipping of the aneurysm was performed via the left pterional approach on the same day. Craniotomy and dural incision showed the ASDH located mainly in the left middle fossa. After evacuation of the hematoma, the Sylvian fissure was dissected to approach the ICA-PcomA aneurysm. However, no blood clot was observed in any of the subarachnoid spaces. Dissection of arachnoid adhesions around

the aneurysm showed the left oculomotor nerve, which was split and penetrated by the fundus of the aneurysm (Fig. 2). The oculomotor nerve appeared flattened at the point of penetration, as it passed toward the superior orbital fissure. The aneurysmal dome had a thin wall and was pulsatile in nature. Turbulent blood flow inside the aneurysm could be seen. The rupture point of the dome could not be identified; nevertheless, it probably existed beyond the oculomotor nerve. The aneurysm was successfully obliterated by clip application to the neck. The patient's postoperative course was uneventful, with a little neurological deficit. She was transferred to the rehabilitation hospital 41 days postoperatively.

Discussion

Non-traumatic ASDHs are uncommon. Arteriovenous malformations, cocaine abuse, and coagulation

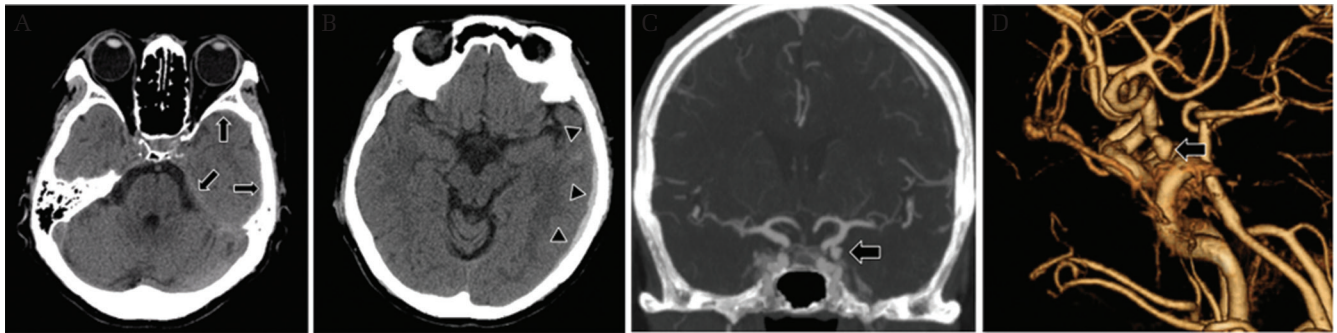


Fig. 1 Computed tomography (CT) scans showing acute subdural hematoma tomography (ASDH) along the tentorium (*arrows*) and the convexity (*arrow heads*) on the left side (A), but no evidence of subarachnoid hemorrhage (SAH) or intracerebral hemorrhage (ICH) (B). Three-dimensional CT angiography (3DCTA) on admission demonstrates a left internal carotid-posterior communicating artery (ICA-PcomA) aneurysm projecting inferiorly (C; multiplanar reconstruction). The aneurysm is located near the temporal base and has a small bleb in the lateral aspect of the sac (D; volume rendering image).

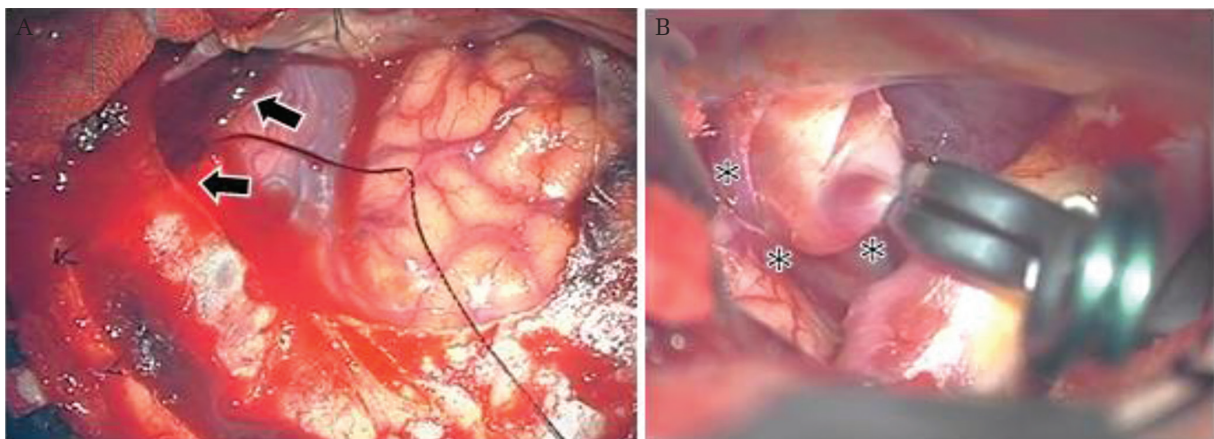


Fig. 2 Intraoperative view shows that the subdural hematoma has accumulated mainly in the middle fossa (*arrows*) (A), and the aneurysm penetrates the oculomotor nerve (B; *asterisks*).

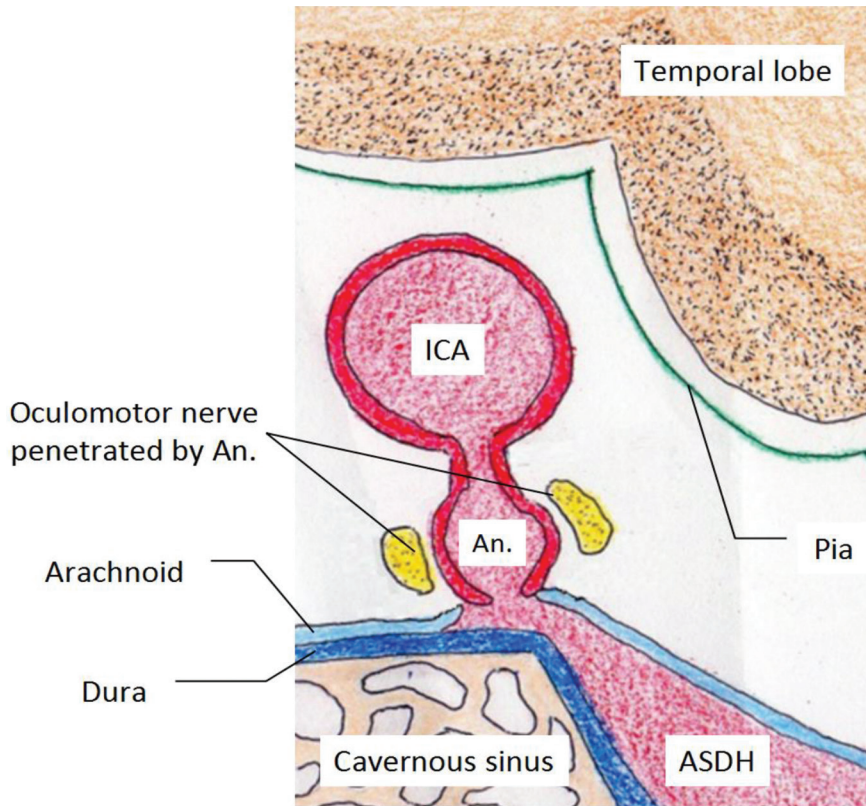


Fig. 3 Schematic illustration showing the aneurysm (An.) penetrating the oculomotor nerve. ICA: internal carotid artery, ASDH: acute subdural hematoma.

deficiency can cause this pathology.^{2,3)} A pure ASDH without SAH due to a ruptured intracranial aneurysm is exceedingly rare; only 43 cases of pure ASDH caused by intracranial aneurysm have been reported since 1981.^{1,4,5)} The mechanisms underlying pure ASDH due to rupture of a cerebral aneurysm remain unclear, but several hypotheses have been proposed, including: (1) repeated minor bleeding from the aneurysm could cause local adhesions of the aneurysm with the superficial arachnoid membrane, and if the aneurysm ruptured, the arachnoid would tear and lead to formation of hematoma in the subdural space; and (2) increased intracranial pressure due to a ruptured aneurysm that might tear the fragile part of the superficial arachnoid membrane has been suggested as a cause of subdural hematoma.^{6,7)}

ICA-PcomA aneurysms frequently originate with posterior and inferior projection. Aneurysms with a size exceeding approximately 4–5 mm may come in contact with the oculomotor nerve and lead to paresis.^{8–10)} Nevertheless, in the present case, the aneurysm developed to 6 mm in diameter posterolaterally, which split and penetrated the oculomotor nerve. We consider that the tip of the dome of the aneurysm reached the superficial arachnoid membrane lining the dura mater across the oculomotor nerve. Therefore, the rupture point of the aneurysm did

not have any direct contact with the fibers of the oculomotor nerve, but with the arachnoid membrane. As a result, the dome of the aneurysm adhered to the arachnoid membrane and ruptured and bled into the subdural space without SAH and oculomotor palsy (Fig. 3).

In the present case, the aneurysm was seen penetrating the oculomotor nerve. Although penetration of the oculomotor nerve by an ICA-PcomA aneurysm is extremely rare, six similar cases have been reported since 1984 (Table 1).^{11–16)} The mechanism is presumed to involve the ICA-PcomA aneurysm coming into contact with and compressing part of the oculomotor nerve just before it enters the cavernous sinus, which has low mobility, for a long time. Finally, the oculomotor nerve is split and penetrated by the ICA-PcomA aneurysm as it grows.¹⁷⁾ Acute dilation of an unruptured aneurysmal sac causing mechanical distortion, pressure changes, and edema of the nerve can result in oculomotor nerve palsy.^{8,9,18)} A possible explanation for the absence of palsy in the oculomotor nerve penetrated by the aneurysm is that the aneurysm in contact with the oculomotor nerve enlarged gradually, with the functional integrity kept under physiological limits for nerve fiber injury.^{13–15,19,20)} It is very difficult to evaluate whether the aneurysm is penetrating

Table 1 Summary of previously published cases of split oculomotor nerve by cerebral aneurysm

Author(s)	Year of publication	Age Sex	Location of aneurysm	Oculomotor palsy	
				Preoperative	Postoperative
Yasargil ¹¹⁾	1984	Not described	Rt. ICA-PcomA	None	Not described
Horiuchi et al. ¹²⁾	1997	48 F	Rt. ICA-PcomA	Partial	Complete
Binning et al. ¹³⁾	2009	63 M	Rt. aberrant PCA	None	Partial (transient)
Maekawa et al. ¹⁴⁾	2010	71 F	Lt. ICA-PcomA	None	None
Hee Sup Shin et al. ¹⁵⁾	2014	70 F	Lt. supraclinoid ICA	None	None
Toyota et al. ¹⁶⁾	2014	42 M	Lt. ICA-PcomA	Complete	Improved
Present case	2017	71 F	Lt. ICA-PcomA	None	None

ICA-PcomA: internal carotid artery-posterior communicating artery, PCA: posterior cerebral artery, ICA: internal carotid artery, M: male, F: female.

oculomotor nerve or not before surgery. There is some possibility that MR cisternography investigates the spatial relationship between the aneurysm and the oculomotor nerve.²¹⁾ Regarding operative technique, we need to do surgical procedures, such as peeling perianeurysmal structures and clipping carefully in order not to develop oculomotor nerve palsy. If there is enough space between the oculomotor nerve and the aneurysmal neck, it is easy to apply clip. We should otherwise detach the aneurysm from the oculomotor nerve to make space for insertion of the clip blade. Especially, if it was ruptured aneurysm with clot in the subarachnoid space, in which dissection around the aneurysm requires gentle procedure, appropriate clip application would be difficult and consequently, the risk of oculomotor nerve palsy might be increased. In such situation, endovascular surgery could be considered as the alternative for the repairment of asymptomatic aneurysm penetrating oculomotor nerve. In this case, endovascular surgery can also be the one of therapeutic strategy due to no oculomotor nerve palsy before surgery.

Conclusion

We report a unique case with a ruptured ICA-PcomA aneurysm presenting pure ASDH without SAH. The intraoperative inspection revealed the aneurysm penetrated oculomotor nerve, even though not an oculomotor nerve palsy was seen before surgery. The dome of the aneurysm adhered to the arachnoid membrane across the oculomotor nerve was thought to rupture and bleed into the subdural space without SAH.

Conflicts of Interest Disclosure

There are no conflicts of interest.

References

- 1) Gong J, Sun H, Shi XY, Liu WX, Shen Z: Pure subdural haematoma caused by rupture of middle cerebral artery aneurysm: case report and literature review. *J Int Med Res* 42: 870–878, 2014
- 2) Depreitere B, Van Calenbergh F, van Loon J: A clinical comparison of non-traumatic acute subdural haematomas either related to coagulopathy or of arterial origin without coagulopathy. *Acta Neurochir (Wien)* 145: 541–546; discussion 546, 2003
- 3) Alves OL, Gomes O: Cocaine-related acute subdural hematoma: an emergent cause of cerebrovascular accident. *Acta Neurochir (Wien)* 142: 819–821, 2000
- 4) Mansour O, Hassen T, Fathy S: Acute aneurysmal bilateral subdural haematoma without subarachnoid haemorrhage: a case report and review of the literature. *Case Rep Neurol Med* 2014: 260853, 2014
- 5) Song TW, Kim SH, Jung SH, Kim TS, Joo SP: Rupture of distal anterior cerebral artery aneurysm presenting only subdural hemorrhage without subarachnoid hemorrhage: a case report. *Springerplus* 5: 73, 2016
- 6) Ishikawa E, Sugimoto K, Yanaka K, et al.: Interhemispheric subdural hematoma caused by a ruptured internal carotid artery aneurysm: case report. *Surg Neurol* 54: 82–86, 2000
- 7) Gilad R, Fatterpekar GM, Johnson DM, Patel AB: Migrating subdural hematoma without subarachnoid hemorrhage in the case of a patient with a ruptured aneurysm in the intrasellar anterior communicating artery. *AJNR Am J Neuroradiol* 28: 2014–2016, 2007
- 8) Saito R, Sugawara T, Mikawa S, Fukuda T, Kohama M, Seki H: Pupil-sparing oculomotor nerve paresis as an early symptom of unruptured internal carotid-posterior communicating artery aneurysms: three case reports. *Neurol Med Chir (Tokyo)* 48: 304–306, 2008
- 9) Motoyama Y, Nonaka J, Hironaka Y, Park YS, Nakase H. Pupil-sparing oculomotor nerve palsy caused by upward compression of a large posterior communicating

- artery aneurysm. Case report. *Neurol Med Chir (Tokyo)* 52: 202–205, 2012
- 10) Rhoton AL: Aneurysms. *Neurosurgery* 51: S121–S158, 2002
 - 11) Yasargil MG: Internal carotid artery aneurysms. In Yasargil MG (ed): *Microneurosurgery* Vol 2. Stuttgart, Germany, Thieme; 1984, pp. 76–77
 - 12) Horiuchi T, Kyoshima K, Oya F, Kobayashi S: Fenestrated oculomotor nerve caused by internal carotid-posterior communicating artery aneurysm: case report. *Neurosurgery* 40: 397–399, 1997
 - 13) Binning MJ, Couldwell WT: Fenestration of the oculomotor nerve by a duplicated posterior cerebral artery and aneurysm. Case report. *J Neurosurg* 111: 84–86, 2009
 - 14) Maekawa H, Hadeishi H, Tanaka M: [Unruptured internal carotid–posterior communicating artery aneurysm splitting the oculomotor nerve: case report]. *Jpn J Stroke* 32: 163–166, 2010 (Japanese)
 - 15) Shin HS, Lee SH, Koh JS: Asymptomatic penetration of the oculomotor nerve by a de novo aneurysm associated with severe atherosclerotic stenosis of the supraclinoid internal carotid artery. *J Korean Neurosurg Soc* 56: 48–50, 2014
 - 16) Toyota S, Taki T, Wakayama A, Yoshimine T: Unruptured internal carotid-posterior communicating artery aneurysm splitting the oculomotor nerve: a case report and literature review. *J Neurol Surg Rep* 75: e180–e182, 2014
 - 17) Beatty RA: Splitting of the optic nerve by a carotid-ophthalmic artery aneurysm. Case report. *J Neurosurg* 65: 560–562, 1986
 - 18) Hyland HH, Barnett HJ: The pathogenesis of cranial nerve palsies associated with intracranial aneurysms. *Proc R Soc Med* 47: 141–146, 1954
 - 19) Jea A, Başkaya MK, Morcos JJ: Penetration of the optic nerve by an internal carotid artery-ophthalmic artery aneurysm: case report and literature review. *Neurosurgery* 53: 996–999; discussion 999–1000, 2003
 - 20) Wang YY, Thani NB, Han TF: Optic nerve penetration by a carotico-ophthalmic artery aneurysm. *J Clin Neurosci* 17: 931–933, 2010
 - 21) Satoh T, Omi M, Ohsako C: Visualization of aneurysmal contours and perianeurysmal environment with conventional and transparent 3D MR cisternography. *AJNR Am J Neuroradiol* 26: 313–318, 2005
-
- Address reprint requests to:* Ryota Sasaki, MD, Department of Neurosurgery, Nara Medical University, 840 shijocho, Kashihara, Nara, 634-8522 Japan.
e-mail: mr.children2601@gmail.com