

Infectious keratitis after transepithelial photorefractive keratectomy: A case report

Suoqing Zhuang, Vishal Jhanji¹, Lixia Sun, Jinyu Li, Jingjing Jiang, Riping Zhang

Transepithelial photorefractive keratectomy (tPRK) promotes faster re-epithelialization which in turn can reduce the risk of infectious keratitis in the postoperative period. We present a case of a 22-year-old man with infectious keratitis in his left

Access this article online	
Quick Response Code:	Website: www.ijo.in
	DOI: 10.4103/ijo.IJO_1730_20

Department Ophthalmology and Vision Science, Joint Shantou International Eye Center of Shantou University and the Chinese University of Hongkong, Dong Xia North Road, Shantou, Guangdong Province, China, ¹Department of Ophthalmology, University of Pittsburgh School of Medicine, Pittsburgh, USA

Correspondence to: Dr. Riping Zhang, MD, Joint Shantou International Eye Center of Shantou University and the Chinese University of Hongkong, Dong Xia North Road, Shantou, Guangdong Province, China. E-mail: zrp@jsiec.org

Received: 31-May-2020
Accepted: 20-Oct-2020

Revision: 03-Oct-2020
Published: 23-Nov-2020

eye 8 days after an uneventful bilateral tPRK. A 2 mm × 5 mm anterior stromal area of corneal infiltration with a same sized overlying epithelial defect was noted at the time of presentation. His uncorrected distance visual acuity was 20/63 in his left eye. Corneal scrapings showed *Bordetella bronchiseptica*. The infection responded to intensive treatment with topical levofloxacin 0.5% eye drops. The final visual acuity was 20/20 in the left eye.

Key words: Infiltration, keratitis, transepithelial photorefractive keratectomy

Transepithelial photorefractive keratectomy uses a Smart Pulse Technology to ameliorate corneal stromal irregularities following ablation. A smooth stromal bed facilitates re-epithelialization which contributes to a reduction in postoperative inflammation. In addition, it can also accelerate visual rehabilitation and reduce postoperative pain.^[1] As compared to alcohol-assisted PRK, tPRK reduces the total operative time by 35% with increased comfort for patient.^[2] Infectious keratitis after refractive surgery is a rare but serious complication. The reported risk of keratitis is between 0.01 and 0.1% after LASIK and, between 0.01 and 0.8% after photorefractive keratectomy (PRK). The overall incidence of microbial keratitis after PRK (0.0013%)

This is an open access journal, and articles are distributed under the terms of the Creative Commons Attribution-NonCommercial-ShareAlike 4.0 License, which allows others to remix, tweak, and build upon the work non-commercially, as long as appropriate credit is given and the new creations are licensed under the identical terms.

For reprints contact: WKHLRPMedknow_reprints@wolterskluwer.com

Cite this article as: Zhuang S, Jhanji V, Sun L, Li J, Jiang J, Zhang R. Infectious keratitis after transepithelial photorefractive keratectomy: A case report. Indian J Ophthalmol 2020;68:3043-5.

is less as compared to LASIK (0.0046%).^[3] Transepithelial photorefractive keratectomy (tPRK) is a technique that can possibly reduce the risk of infectious keratitis by promoting faster re-epithelialization. We present a case of infectious keratitis after uneventful tPRK.

Case Report

A 22-year-old man without any past ocular or systemic history was evaluated for laser refractive surgery. The preoperative refraction was $-4.0/-1.75 \times 180$ in the right eye and $-3.25/-2.75 \times 180$ in the left eye with corrected distance visual acuity (CDVA) of 20/20 in both eyes. There were no anterior or posterior segment abnormalities in either eye. In October 2019, the patient underwent uneventful bilateral tPRK procedure using the Schwind Amaris 750S Excimer laser (Schwind eye-tech-solutions GmbH & Co, Kleinostheim, Germany). Postoperatively, the patient was prescribed 0.5% levofloxacin eye drops four times per day and 0.1% fluorometholone eye drops four times per day.

On day 5 postoperatively, complete epithelial healing was noted in both eyes after removing the bandage contact lens. At one week postoperatively, the patient experienced mild pain in his left eye. The pain worsened in 24 hours and the patient sought medical advice on day 8 after surgery. His uncorrected visual acuity were 20/25 in the right eye and 20/63 in the left eye. Slit-lamp examination revealed conjunctival hyperemia and a 2 mm \times 5 mm area of corneal infiltration with an overlying epithelial defect [Fig. 1]. AS-OCT showed a linear zone of hyperreflectivity in corneal stroma [Fig. 2]. *In vivo* confocal microscopy revealed a large number of Langerhans cells in the Bowman layer. Subsequently, corneal scrapings were obtained from the left eye. Hourly levofloxacin 0.5% eye drops and once daily gatifloxacin 0.3% eye gel were prescribed. Microbiological culture and sensitivity reports were available 5 days later (13 days postoperatively) showing *Bordetella bronchiseptica*. The organism was sensitive to levofloxacin and tobramycin and β lactam antibiotics except ceftriaxone and aztreonam.

At the end of first week, the UDVA improved to 20/25. Slit-lamp examination showed mild corneal edema over the area of corneal infiltrate. In addition, conjunctival hyperemia had reduced. Levofloxacin eye drops were reduced to four times a day. The corneal infiltrate resolved completely over the next 5 weeks leaving a residual anterior corneal stromal scar [Fig. 3]. The UDVA was 20/20 with auto-refraction of -0.75×155 in the left eye.

Discussion

tPRK utilizes a nomogram that combines epithelial removal with spherocylindrical correction by delivering variable amount of laser energy from the center to the periphery of the cornea.^[4] tPRK has also been used to remove superficial scars.^[2,5] Our patient underwent successful tPRK but developed microbial keratitis in the early postoperative period. We identified *Bordetella bronchiseptica* as the causative organism. Previous studies have demonstrated that *Bordetella bronchiseptica* is associated with wild or domesticated animals and it is an opportunistic pathogen in humans establishing both asymptomatic and symptomatic infection. It has been reported that *Bordetella bronchiseptica* can cause bronchitis, pneumonia and septicemia in people with risk factors including low immunity, and inappropriate animal contact.^[6] There is no previous report of *Bordetella*-related ocular infection. In

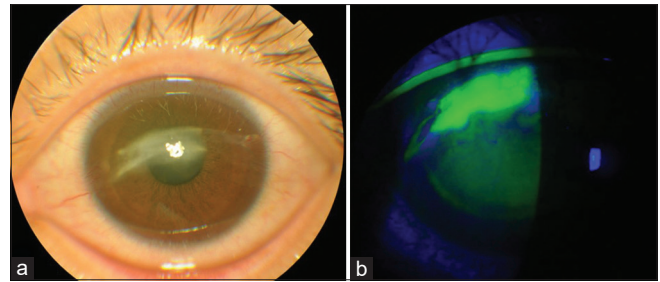


Figure 1: Slit-lamp examination shows band-like corneal infiltrate in central area (a) and corneal fluorescent staining test shows overlying epithelial defect in corresponding area (b)

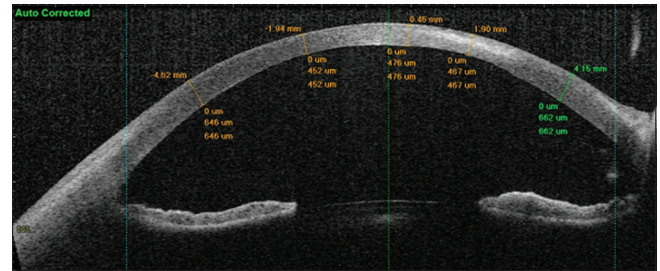


Figure 2: The anterior segment optical coherence tomography shows a linear zone of hyperreflectivity in corneal stroma indicating its infiltrative depth

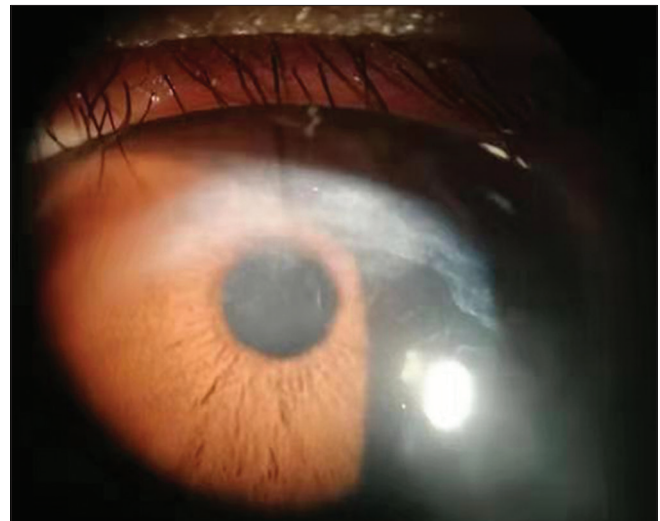


Figure 3: After 5-weeks treatment corneal leucoma is seen above the pupillary zone. Corneal infiltration is absent

our patient, the obvious risks for infection were surgery and postoperative use of contact lens. The organism was sensitive to levofloxacin and responded well to prompt treatment and the microbiological culture results were helpful to identify the organism as *Bordetella bronchiseptica*.

Infectious keratitis is a rare but potentially devastating complication after refractive surgery. Compared with flap-based refractive surgeries like LASIK or SMILE, surface ablation surgeries such as PRK and tPRK involve creation of an epithelial defect intraoperatively and use of contact lens in the postoperative period thereby increasing the risk of microbial keratitis in the early postoperative period. Although it has been suggested that epithelial healing is faster after tPRK compared

to conventional PRK,^[7] nevertheless, it is important to realize the potential risk of infection. Timely diagnosis and prompt management is essential to prevent permanent loss of vision.

Conclusion

This is the first case of infectious keratitis reported after tPRK. Rapid diagnosis and prompt treatment result in good visual outcomes.

Declaration of patient consent

The authors certify that they have obtained all appropriate patient consent forms. In the form the patient(s) has/have given his/her/their consent for his/her/their images and other clinical information to be reported in the journal. The patients understand that their names and initials will not be published and due efforts will be made to conceal their identity, but anonymity cannot be guaranteed.

Financial support and sponsorship

This study was funded by Science and Technology Project of Shantou City, Guangdong, China(2019-106).

Conflicts of interest

There are no conflicts of interest.

References

1. Aslanides IM, Kymionis GD. Trans advanced surface laser ablation (TransPRK) outcomes using SmartPulseTechnology. *Cont Lens Anterior Eye* 2017;40:42-6.
2. Kaluzny BJ, Cieslinska I, Mosquera SA, Verma S. Single-step transepithelial PRK vs alcohol-assisted PRK in myopia and compound myopic astigmatism correction. *Medicine* 2016;95:e1993-2262.
3. Schallhorn JM, Schallhorn SC, Hettinger K, Hannan S. Infectious keratitis after laser vision correction: Incidence and risk factors. *J Cataract Refract Surg* 2017;43:473-9.
4. Fadlallah A, Fahed D, Khalil K, Dunia I, Menassa J, El Rami H, *et al.* Transepithelial photorefractive keratectomy: Clinical results. *J Cataract Refract Surg* 2011;37:1852-7.
5. Sher NA, Bowers RA, Zabel RW, Frantz JM, Eiferman RA, Brown DC, *et al.* Clinical use of the 193-nm excimer laser in the treatment of corneal scars. *Arch Ophthalmol* 1991;109:491-8.
6. Ahuja U, Liu M, Tomida S, Park J, Souda P, Whitelegge J, *et al.* Phenotypic and genomic analysis of hypervirulent human-associated *Bordetella bronchiseptica*. *BMC Microbiol* 2012;12:167.
7. Naderi M, Jadidi K, Mosavi SA, Daneshi SA. Transepithelial photorefractive keratectomy for low to moderate myopia in comparison with conventional photorefractive keratectomy. *J Ophthalmic Vis Res* 2016;11:358-62.