

Hemoadsorption for severe MIS-C in critically ill children, should we consider it as a therapeutic opportunity?

Gabriella Bottari¹ , Flavia Severini², Anna Hermine Markowich²,
Giulia Lorenzetti², Juan Carlos Ruiz Rodriguez^{3,4},
Ricard Ferrer^{3,4}, Paola Francalanci⁵ , Antonio Ammirati⁶,
Paolo Palma⁷ and Corrado Cecchetti¹

The International Journal of Artificial
Organs

2022, Vol. 45(10) 871–877

© The Author(s) 2022



Article reuse guidelines:

sagepub.com/journals-permissions

DOI: 10.1177/03913988221111179

journals.sagepub.com/home/jao



Abstract

Multisystem inflammatory syndrome (MIS-C) is a new severe clinical condition that has emerged during the COVID-19 pandemic. MIS-C affects children and the young usually after a mild or asymptomatic COVID-19 infection. MIS-C has a high tropism for the cardiovascular system with need for inotropes and vasopressor support in 62% of cases. As of today a mortality from 1.5% to 1.9% related to MIS-C is reported. Hemoadsorption via the inflammatory mediator adsorber CytoSorb (CytoSorbents Europe, Berlin Germany) has been used as adjunctive therapy with the aim to restore the host response in septic shock and other hyper-inflammatory syndromes. We present the clinical experience of an adolescent boy with a refractory shock secondary to left ventricular dysfunction (LVD) in the context of MIS-C, treated with hemoadsorption, and continuous kidney replacement therapy (CKRT) in combination with immunomodulatory therapies. The therapeutic strategy resulted in hemodynamic and clinical stabilization as well as control of the hyperinflammatory response. Treatment appeared to be safe and feasible. Our findings are in line with previously published clinical cases on Cytosorb use in MIS-C showing the beneficial role of the hemoperfusion with Cytosorb in severe MIS-C to manage the cytokine storm. We provide an analysis and comparison of recent evidence on the use of hemoadsorption as an adjuvant therapy in critically ill children with severe forms of MIS-C, suggesting this blood purification strategy could be a therapeutic opportunity in severe LVD due to MIS-C, sparing the need for extracorporeal membrane oxygenation (ECMO) and other mechanical cardiocirculatory supports.

Keywords

Coronavirus, multisystem inflammatory syndrome in children (MIS-C), myocarditis, cytokines, left ventricular failure (LVEF), shock, pediatric critical care

Date received: 11 January 2022; accepted: 7 June 2022

¹Pediatric Intensive Care Unit, Pediatric Emergency Department, Bambino Gesù Children's Hospital, IRCCS, Rome, Italy

²Department of Pediatrics, University of Rome Tor Vergata, Residency School of Pediatrics, Bambino Gesù Children's Hospital, IRCCS, Rome, Italy

³Intensive Care Department, Vall d'Hebron University Hospital, Vall d'Hebron Barcelona Hospital Campus, Barcelona, Spain

⁴Shock, Organ Dysfunction and Resuscitation Research Group, Vall d'Hebron Research, Institute (VHIR), Barcelona, Spain

⁵Unit of Pathology, Bambino Gesù Children's Hospital, IRCCS, Rome, Italy

⁶Pediatric Emergency Unit, Pediatric Emergency Department, Bambino Gesù Children's Hospital, IRCCS, Rome, Italy

⁷Clinical Immunology and Vaccinology Unit, Pediatric Academic Department (DPUO), Bambino Gesù Children's Hospital, IRCCS, Rome, Italy

Corresponding author:

Gabriella Bottari, Pediatric Intensive Care Unit, Pediatric Emergency Department, Bambino Gesù Children's Hospital, Largo Sant'Onofrio, Rome 00165, Italy.

Email: gabriella.bottari@opbg.net

Introduction

Multisystem inflammatory syndrome in children (MIS-C) is a clinically severe condition that was first described during the coronavirus 2019 (COVID-19) pandemic. This new phenomenon appears to be temporally, geographically, and epidemiologically related to the severe acute respiratory syndrome coronavirus 2 (SARS-CoV-2) infection.¹ Most of the children affected have a positive SARS-CoV2 serology with a negative Reverse Transcription-Polymerase Chain Reaction (RT-PCR), indicating previous infection. It was hypothesized that a “cytokine storm” might be responsible for MIS-C, increased interferon signaling and high plasma levels of interleukin (IL)-6 and IL-10 were described by Cheung et al.² Diorio et al.³ reported that the combination of IL-10 and TNF-alpha levels uniquely identifies MIS-C from severe COVID-19, while Consiglio et al.⁴ observed that IL-6, IL-17A, and CXCL10 contributed the most to the cytokine storm.

The clinical picture in MIS-C is characterized by prolonged fever, nonspecific symptoms such as fatigue, headache, and mucocutaneous findings, with a high prevalence of gastrointestinal symptoms (71%) and cardiovascular dysfunction (82%).¹ Notably, cardiac involvement requiring inotropic support has been observed in 63% of cases and was the predominant reason for intensive care support (68%). Cardiovascular support is most common in cases where mechanical ventilation is required.¹ However, myocardial dysfunction improved in many cases with immunomodulatory drugs where the rate of Extracorporeal Membrane Oxygenation (ECMO) use (4%–6.3%) and mortality (1.5%–1.9%) are high.^{1,5} In particular, in their meta-analysis Radia et al. reported that from the 12 children included in the study, 7 died while on ECMO. Given the severity of this condition, there is an urgent need to identify the best therapeutic strategies.

Increasingly more reports are appearing in the literature that describe the use of hemadsorption with Cytosorb as a supportive therapeutic intervention in critically ill children with cytokine storm-related multiple organ dysfunction, including cytokine release syndrome after chimeric antigen receptor (CAR)-T -cell infusion, and secondary hemophagocytic lymphohistiocytosis (HLH).⁶ Indeed, CytoSorb is an extracorporeal adsorber which has been demonstrated to remove cytokines from the plasma, and it has been postulated that the use of hemoperfusion containing these highly biocompatible sorbents might potentially provide support to various organs in COVID-19 patients.^{7,8}

We present a new clinical case of a 13 years old boy with severe myocardial dysfunction, with evidence of overlapping MIS-C and viral myocarditis and review and compare recent evidence and the potential role of hemoadsorption as an adjuvant therapeutic strategy in critically ill children with severe forms of MIS-C characterized by cardiogenic shock.

Case report

The 13 years old boy (weight 60 kg, height 160 cm) presented with fever, rash, abdominal pain, and vomiting. Blood tests revealed elevated leukocytes with neutrophilia, high C-reactive protein (CRP) (29.31 mg/gL), procalcitonin (3.32 ng/mL), hyperferritinemia (1529 ng/mL). He had a positive history for SARS-CoV-2 infection 6 weeks previously with positive serology. Within 24 h he developed diarrhea, poor pallor, and hypotension. Cardiac markers were elevated, and 2D-echocardiogram showed left ventricular (LV) dysfunction (Ejection Fraction (EF) 35% calculated by Simpson biplane method). Supportive care with milrinone and dopamine was started and, as MIS-C was suspected, he received immunoglobulins and corticosteroids. The following day he deteriorated with an 2D-echocardiogram showing an EF of 25%, therefore he was referred to our pediatric intensive care unit (PICU) requiring endotracheal intubation and invasive mechanical ventilation (IMV) due to cardiogenic shock.

Given the increase in troponin I (high sensitivity troponin, hs-TnI) levels from 75 to 1200 pg/ml in 12 h, infectious myocarditis was suspected and an endomyocardial biopsy (EMB) was performed. Considering the clinical picture of hyperinflammation associated severe shock due to the left ventricular dysfunction (LVD) and high lactate (7.9 mmol/l) with the need for high inotropic support (epinephrine 0.35 µ/kg/min, norepinephrine 0.06 µ/kg/min, Milrinone 0.5 µ/kg/min) hemoperfusion with Cytosorb was started in combination with continuous kidney replacement therapy (CKRT). The patient was placed on a citrate-calcium anticoagulation protocol.

EMB histology showed diffuse infiltration of lymphocytes and monocytes (CD3+++ , CD4, CD8++ , TIA-1+, Granzyme B+, CD20+/-, and MUM1-) with myocyte fragmentation and necrosis (Figure 1) Nested PCR and RT-PCR for the detection viruses showed the presence of Parvovirus B19 (PVB19), but did not detect SarS-CoV-2 RNA in the myocardium. Serological test for PVB19 returned positive for IgG and negative for IgM.

PVB19 is a frequent causative agent of myocarditis that commonly induces cardiac dysfunction but also gastrointestinal symptoms. Of note, even though the patient fulfilled the diagnostic criteria of MIS-C, we cannot completely rule out the development of fulminant myocarditis due to PVB19 after suffering from COVID-19.

Due to PVB19 positivity, corticosteroids were withheld and immunoglobulin and anakinra were maintained. Blood purification continued for 72h (the sorbent was changed every 12h in the first 24h, then every 24h). We already observed an improvement in the LV-EF. after the first 24h of hemoperfusion and CKRT. Inflammatory and cardiac markers reduced and inotropes were progressively tapered off (Figures 2 and 3). The most of laboratory tests improved in the same time (Figure 4). CKRT was discontinued at the same

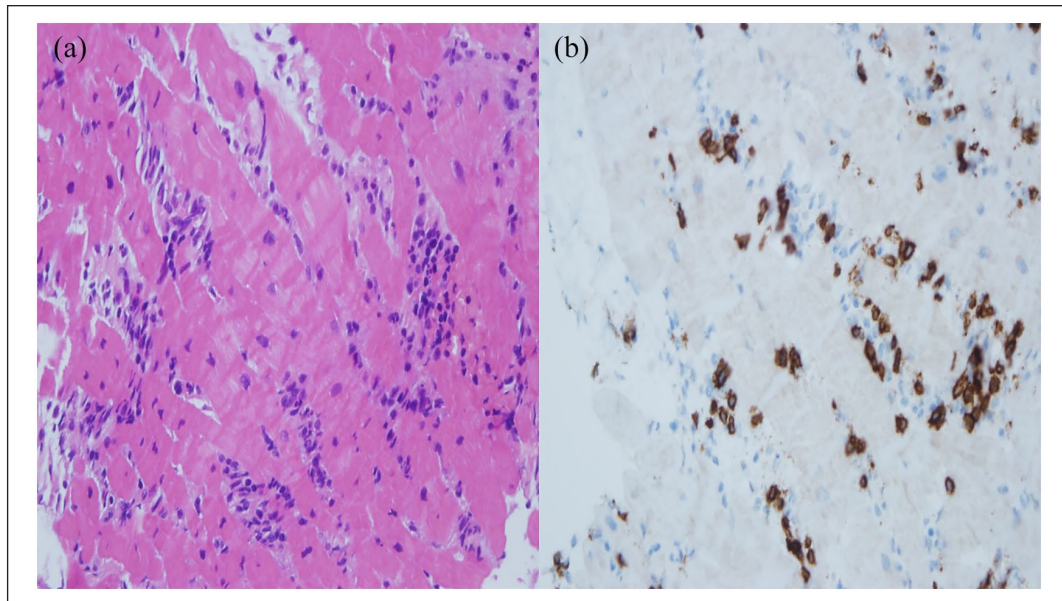


Figure 1. (a) Endomyocardial biopsy (EMB) histology shows a mononuclear, predominantly lymphocytic, inflammatory infiltrate, and myocardial injury with necrosis (HE, 40×). (b) Immunohistochemistry with anti-CD3 revealed a rich T-lymphocytic component (CD3, 40×).

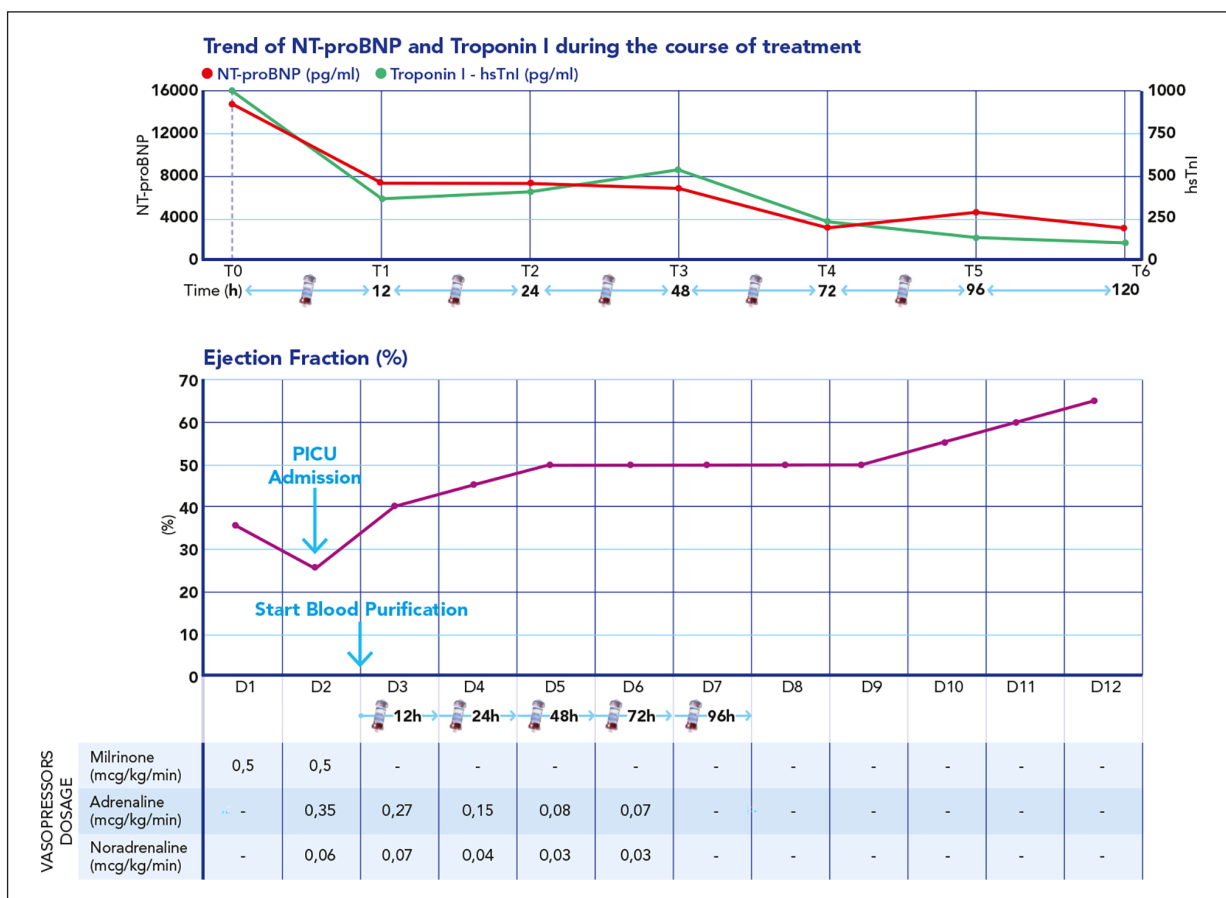


Figure 2. Upper section: time course of N-terminal (NT)-pro hormone brain natriuretic peptide (BNP) (NT-proBNP) and Troponin I (high sensitivity troponin hs-Tnl) during extracorporeal blood purification treatment (EBPT). Lower section: time course of the ejection fraction during EBPT.

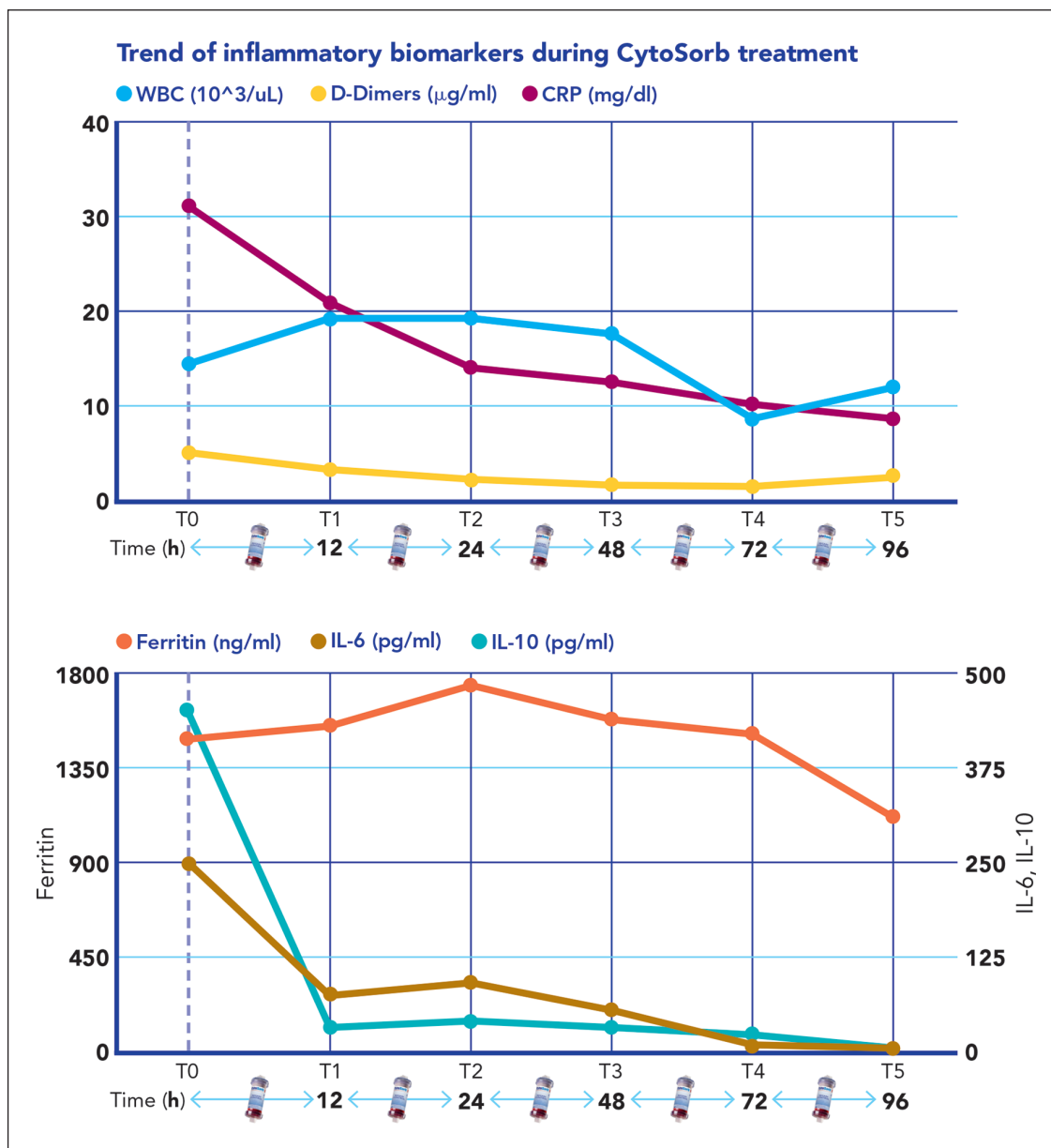


Figure 3. Upper section: time course of White Blood Cells (WBC), D-dimers, and C-reactive protein (CRP) during extracorporeal blood purification treatment (EBPT). Lower section time course of Ferritin, Interleukin 6, Interleukin 10 during EPBT.

time of hemoperfusion after 72 h (day 3), and there were no adverse events noted. He was weaned off invasive mechanical ventilation on day 6 and discharged from the PICU on day 8.

After 2 weeks his cardiac function had completely restored and the patient was discharged from the hospital on day 20 requiring only spironolactone.

Discussion

The exact mechanism of myocardial dysfunction in MIS-C is still poorly understood. Due to the fact that EMB is rarely performed, diagnosis is largely based on clinical symptoms, laboratory results and findings from imaging.

SARS-CoV-2 can infect macrophages and also myocytes, but the virus is in most cases not cytolytic.⁹ It is likely that SARS-CoV-2 rather induces an inflammatory response by cytokine release, thus resulting in indirect cytotoxic myocardial injury.¹⁰

Our patient fulfilled the diagnostic criteria of MIS-C: looking at the CDC criteria which confirm the diagnosis of MIS-C in contrast to other infections, and we concluded that the child had overlapping MIS-C and viral myocarditis, both of which probably contributed to the myocardial dysfunction.¹¹

In this adolescent with refractory shock secondary to LV dysfunction in the context of MIS-C, treatment with

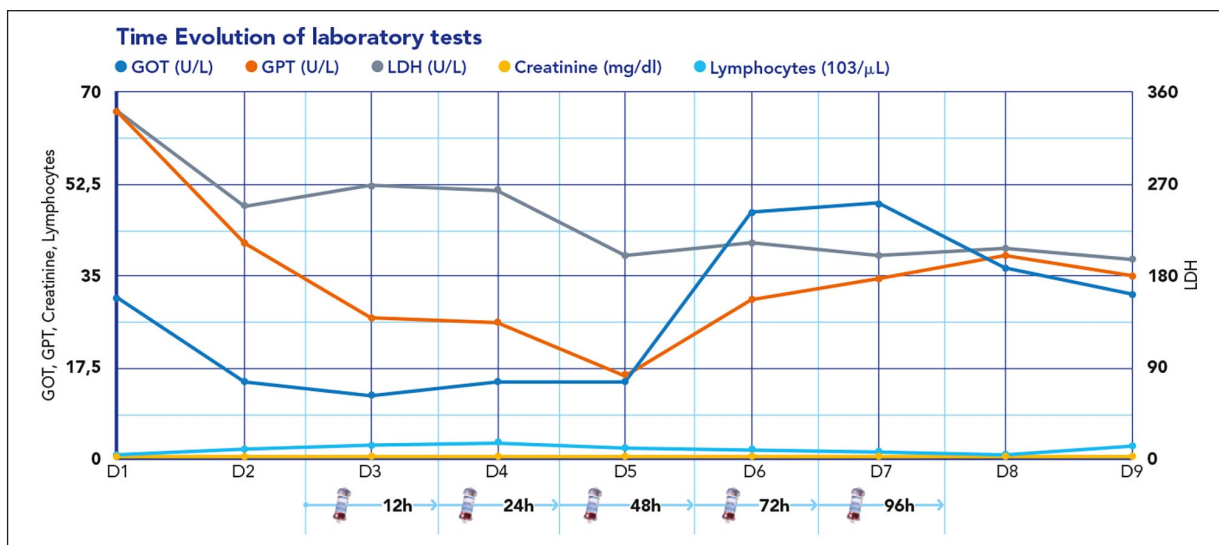


Figure 4. Time course of Lymphocytes, Lactate Dehydrogenase (LDH), Creatinine, aspartate aminotransferase AST, alanine aminotransferase ALT during Extracorporeal Blood Purification Treatment (EBPT).

hemoadsorption in combination with immunomodulatory therapies resulted in hemodynamic and clinical stabilization as well as control of the hyperinflammatory response. Treatment appeared safe and feasible.

We have previously described the successful treatment of severe MIS-C in a 14-year old girl with CytoSorb hemoadsorption plus CKRT and immunomodulatory drugs (described as patient B in Table 1).¹² Ruiz Rodriguez et al. recently also reported the use of hemadsorption as part of the supportive treatment in a 17-year old boy with severe MIS-C (described as patient C in Table 1).¹³ Including our present case (described as patient A in Table 1), these three patients all developed shock secondary to severe myocardial dysfunction requiring inotropic support and IMV (Table 1).

Patient A and Patient B required IMV due to cardiogenic shock, Patient C required IMV not only for hemodynamic reasons but also for a concomitant clinical picture of bilateral pneumonia. The time lapse in the three cases to receive blood purification support from the onset of the low cardiac output syndrome ranged between 24 and 48 h. High levels of inflammatory biomarkers are reported in all cases, in particular IL-6 values were significantly higher than 100 pg/ml (Table 1). The duration of blood purification ranged from 24 to 72 h. In the two patients treated at our center, the first two CytoSorb cartridge columns were changed every 12 h in the first 24 h.^{6,12,14} The patients also received immunomodulatory treatments (Table 1). All three patients responded with a prompt improvement in their myocardial function (within the first 24 h) following the start of hemadsorption. A dramatic decrease in inflammatory cytokines (IL-6 and IL-10) was observed, as well as a reduction in inflammatory markers (CRP, ferritin, D-dimers) (Table 1). As a treatment option for cytokine storm, CytoSorb has been applied by clinicians in MIS-C,

however the use of the device in the US is not FDA approved for the pediatric population, and thus the providers need to obtain authorization for compassionate use.¹⁴ Therefore, caution is advised with the use of these systems.^{8,15} On the other hand, the presented clinical experiences suggest that hemoadsorption may be a promising rescue therapy in patients with refractory shock secondary to severe left ventricular dysfunction (LVD) in MIS-C, potentially avoiding the need for ECMO and/or other mechanical cardiocirculatory support, if it is started as early as possible. Sparing ECMO in critically ill children with severe myocardial dysfunction due MIS-C is a stimulating therapeutic opportunity considering morbidity and mortality ECMO-related in these patients.^{1,5,16,17} Indeed blood purification is for technical reasons less invasive and allow the use of regional anticoagulation with citrate. On the other hand, these preliminary experiences should be confirmed with more evidences.

Furthermore, CytoSorb does not appear to interfere with the most common immunomodulatory therapies used currently in MIS-C.

Conclusions

MIS-C is a complex clinical syndrome that can induce severe myocardial dysfunction secondary to massive cytokine release. Evidence shows that mortality is significant and that there is a need for ECMO or other mechanical cardiocirculatory support. The potential beneficial role of an extracorporeal blood purification treatment based on hemoperfusion and CRRT is suggested by our report and by previous experience described in 2021. From this point of view hemoperfusion could be considered a therapeutic opportunity in this clinical setting, but further evidence is needed to confirm these clinical experiences.

Table 1. Upper section: clinical characteristics, intensive care supports including extracorporeal blood purification techniques and immunomodulatory treatments in clinical case reported (Patient A) and in the other two pediatric clinical cases previous reported by authors (Patient B and Patient C).^{12,13}

	Patient A	Patient B	Patient C
Age (years)	13	14	17
Sex	Male	Female	Male
Previous SARS-Cov-2 infection	Yes (6 weeks)	Yes (20 days)	Yes (2 weeks)
Clinical manifestations	Fever, rash, abdominal pain, diarrhea	Fever, rash, confusion	Fever, rash, dyspnea, chest and abdominal pain
Diagnosis	MIS-C Parvovirus B19 myocarditis	MIS-C	MIS-C
Reason for ICU admission	Shock	Shock	Shock and respiratory failure
Inotropes	Yes (milrinone, dopamine, then epinephrine, norepinephrine)	Yes (milrinone, epinephrine)	Yes (dobutamine, norepinephrine)
IMV	Yes	Yes	Yes
CRRT + CytoSorb	Yes	Yes	Yes
CytoSorb duration	72 h	72 h	24 h
Immunomodulatory treatment	Igex + methylprednisolone + anakinra	Igex + methylprednisolone + anakinra	Igex + methylprednisolone
Laboratory tests pre-CytoSorb			
CRP (mg/l)	364.5	135.2	306.8
Ferritin (mcg/l)	1475	2658	399
IL-6 (pg/ml)	250	5346	3457
IL-10 (pg/ml)	445	138	90.3
D-dimer (mcg/ml)	4.4	18.99	0.902
NT-proBNP (ng/ml)	14,305	2227	8.121
hs-Tnt (pg/ml)	1207	31.4	2886
EF%	25	35	30
Laboratory tests post-CytoSorb			
CRP (mg/l)	91.9	0.42	362.5
Ferritin (mcg/l)	1103	1289	619
IL-6 (pg/ml)	4	0	47.8
IL-10 (pg/ml)	0	42	9.24
D-dimer (mcg/ml)	2.28	2.92	1.36
NT-proBNP (ng/ml)	4898	635	15
hs-Tnl (pg/ml)	107	5.8	1883
EF%	51	57.5	45
Discharge from PICU	Day 8	Day 8	Day 5
Discharge from hospital	Day 19	Day 32	Day 20
Clinical outcome	No residual dysfunction	No residual dysfunction	No residual dysfunction

Lower section: biomarkers of inflammation before and after blood purification (Cytosorb plus CRRT) and clinical outcomes in clinical case reported (Patient A) and in the other two pediatric clinical cases previous reported by authors (Patient B and Patient C).^{12,13}

IMV: invasive mechanical ventilation; CRRT: continuous kidney replacement therapy; Igex, Immunoglobulines endovenous; CRP, C reactive protein; NT-proBNP, N-terminal (NT)-pro hormone BNP; Hs-Tnl, High Sensivity Troponin I; EF%, percentage of ejection fraction.

Declaration of conflicting interests

The author(s) declared the following potential conflicts of interest with respect to the research, authorship, and/or publication of this article: Gabriella Bottari received honoraria as a speaker for CytoSorbents.

Ricard Ferrer Roca received honoraria as a speaker for CytoSorbents.

Juan Carlos Ruiz-Rodriguez received fees for the Advisory Board Paalex.

Ethical statement


Written informed consent to participate in this study was provided by the participants' legal guardian/next of kin. Written informed consent was obtained from the minor(s)' legal guardian/next of kin for the publication of any potentially identifiable images or data included in this article.

Funding

The author(s) received no financial support for the research, authorship, and/or publication of this article.

ORCID iDs

Gabriella Bottari  <https://orcid.org/0000-0002-2723-9914>

Paola Francalanci  <https://orcid.org/0000-0001-9047-2383>

References

1. Radia T, Williams N, Agrawal P, et al. Multi-system inflammatory syndrome in children & adolescents (MIS-C): A systematic review of clinical features and presentation. *Paediatr Respir Rev* 2021; 38: 51–57.
2. Cheung EW, Zachariah P, Gorelik M, et al. Multisystem inflammatory syndrome related to COVID-19 in previously healthy children and adolescents in New York City. *JAMA* 2020; 324(3): 294–296.
3. Diorio C, Henrickson SE, Vella LA, et al. Multisystem inflammatory syndrome in children and COVID-19 are distinct presentation of SARS-CoV-2. *J Clin Invest* 2020; 130(11): 5967–5975.
4. Consiglio CR, Cotugno N, Sardh F, et al. The immunology of multisystem inflammatory syndrome in children with COVID-19. *Cell* 2020; 183(4): 968–981.e7.
5. Yasuhara J, Watanabe K, Takagi H, et al. COVID-19 and multisystem inflammatory syndrome in children: a systematic review and meta-analysis. *Pediatr Pulmonol* 2021; 56(5): 837–848.
6. Bottari G, Merli P, Guzzo I, et al. Multimodal therapeutic approach of cytokine release syndrome developing in a child given chimeric antigen receptor-modified T cell infusion. *Crit Care Explor* 2020; 2(1): e0071. eCollection 2020 Jan.
7. Ronco C, Navalesi P and Vincent JL. Coronavirus epidemic: preparing for extracorporeal organ support in intensive care. *Lancet Respir Med* 2020; 8(3): 240–241.
8. Raina R, Chakraborty R, Sethi SK, et al. Kidney replacement therapy in COVID-19 induced kidney failure and septic shock: a pediatric continuous renal replacement therapy [PCRRT] position on emergency preparedness with resource allocation. *Front Pediatr* 2020; 8: 413.
9. Greulich S and Klingel K. COVID-19 and myocarditis: findings from cardiac magnetic resonance imaging and endomyocardial biopsies. *Hamostaseologie* 2021; 41: 366–370.
10. Cantarutti N, Battista V, Adorisio R, et al. Cardiac manifestations in children with Sars-Cov-2 infection: 1-year pediatric multicenter experience. *Children* 2021; 8(8): 717.
11. www.CDC.gov. Multisystem inflammatory syndrome in children (MIS-C) associated with coronavirus disease 2019 (COVID-19). 2020. <https://emergency.cdc.gov/han/2020/han00432.asp>
12. Bottari G, Confalone V, Cotugno N, et al. Efficacy of CytoSorb in a pediatric case of severe multisystem inflammatory syndrome (MIS-C): a clinical case report. *Front Pediatr* 2021; 9: 676298–676307.
13. Ruiz-Rodríguez JC, Chiscano-Camón L, Palmada C, et al. Hemadsorption as a treatment option for multisystem inflammatory syndrome in children associated with COVID-19. A case report. *Front Immunol* 2021; 12: 665824–665913.
14. www.fda.gov. *CytoSorb 300 mL device approved by FDA for emergency treatment of COVID-19*. 2020.
15. Deep A, Bansal M and Ricci Z. Acute kidney injury and special considerations during renal replacement therapy in children with Coronavirus disease-19: perspective from the Critical Care Nephrology section of the European Society of Paediatric and Neonatal Intensive Care. *Blood Purif* 2021; 50(2): 150–160.
16. Steurer L, Schlager G, Sadeghi K, et al. Hemadsorption as rescue therapy for patients with multisystem organ failure in pediatric intensive care—report of two cases reports and review of the literature. *Artif Organs* 2021; 45(12): 1582–1593.
17. Saporov A, Sazonov V, Tobylbaeva Z, et al. First successful hemoadsorption using cytosorb® in a septic pediatric patient in Kazakhstan: a case report. *Int J Artif Organs* 2019; 42: 315–317.