



Contents lists available at ScienceDirect

International Journal of Surgery Case Reports

journal homepage: www.casereports.com

Acute pancreatitis secondary to duodeno-duodenal intussusception caused by a duodenal membrane, in a patient with intestinal malrotation



Pernille Oehlenschläger Larsen*, Mark Bremholm Ellebæk, Torsten Pless, Niels Qvist

Department of Gastrointestinal Surgery, Odense University Hospital, Denmark

ARTICLE INFO

Article history:

Received 15 April 2015

Received in revised form 28 May 2015

Accepted 7 June 2015

Available online 19 June 2015

ABSTRACT

Duodeno-duodenal intussusception is often caused by an intraluminal tumour. The condition is rare owing to the retroperitoneal fixation of the duodenum, which is sometime absent in cases of intestinal malrotation. We describe the case of a 19-year old man admitted to hospital with abdominal pain and vomiting. A CT scan revealed a duodeno-duodenal intussusception including the head of the pancreas, which was confirmed by laparotomy. The cause was found to be a duodenal membrane with a pinhole passage combined with non-rotation of the duodenum.

© 2015 The Authors. Published by Elsevier Ltd. on behalf of Surgical Associates Ltd. This is an open access article under the CC BY-NC-ND license (<http://creativecommons.org/licenses/by-nc-nd/4.0/>).

1. Introduction

Duodeno-duodenal intussusception, which involves the distal invagination of a segment of the duodenum, is a rare condition owing to the retroperitoneal fixation of the duodenum, which is sometime absent in cases of intestinal malrotation. The vast majority (80–90%) of cases of intestinal intussusception are secondary to pathological masses in the intestine, such as Brunner's gland hamartomas, lipomas and adenomas [1,2]. The presence of a duodenal membrane may cause retention of food resembling a pathologic mass, which may in turn facilitate intussusception.

We describe the interesting case of a patient with intestinal malrotation who developed acute pancreatitis as a result of a duodenal intussusception involving the head of pancreas which was caused by a duodenal membrane. The most common symptoms of duodenal intussusception are intermittent abdominal pain and vomiting. Other symptoms include gastro-oesophageal reflux, weight loss, fatigue, anaemia due to iron deficiency; pancreatitis due to obstruction of the outlet duct has also been described [3–6]. Owing to the intermittent nature of the symptoms delay in diagnosis is common [2].

2. Presentation of case

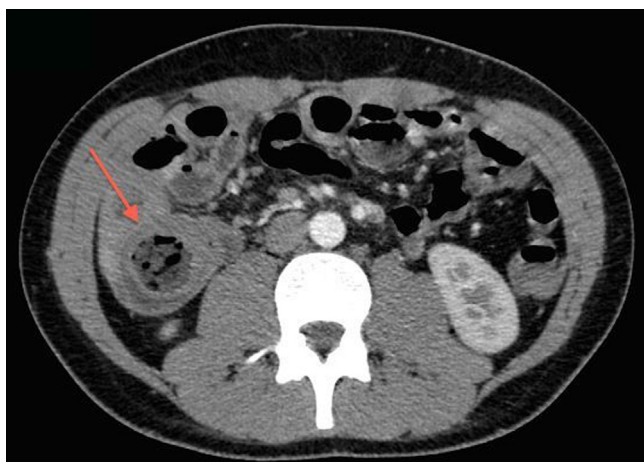
A 19 year old male was admitted with acute onset abdominal pain. Symptoms had started three days previously and consisted of intermittent peri-umbilical pain, nausea and vomiting.

The initial physical examination indicated a healthy young man with mild epigastric tenderness. In infancy he had undergone surgery for a congenital heart malformation involving closure of atrial and ventricular septal defects. During childhood he had been treated with proton-pump inhibitors for symptoms of gastro-oesophageal reflux, and he had a history of intermittent post-prandial abdominal pain, but had never undergone endoscopic examination, or any abdominal surgery. Presented with a normal height and weight for his age with a body mass index of 25.

Routine blood analyses revealed elevated levels of S-amylase (408 U/l; ref. value 10–65 U/l) and bilirubin (41 µmol/l; ref. value 5–25 µmol/l). Subsequently the patient developed fever, (core body temperature 38.6 °C); acute cholecystitis was suspected so he was treated with intravenous antibiotics. Subsequent abdominal ultrasonography was inconclusive, although there were signs consistent with a tumour in the head of the pancreas. A CT-scan revealed a duodeno-duodenal intussusception involving the head of the pancreas and the common bile duct (Figs. 1 and 2).

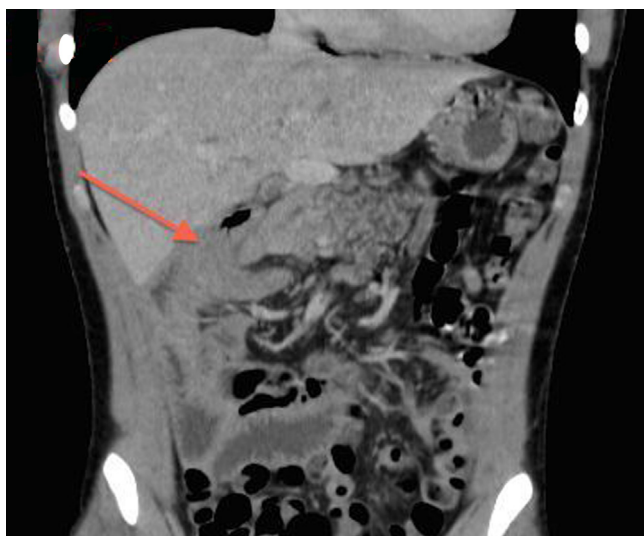These findings were confirmed at laparotomy and non-rotation of the duodenum was also noted (Fig. 3). The intussusception was released, and a duodenotomy revealed a duodenal membrane with a narrow central opening (Fig. 4). The top of the intussusception was at the level of the membrane. The membrane was excised and the duodenotomy closed transversely. Post-operative recovery was uncomplicated. S-bilirubin and S-amylase levels were within the normal range at discharge.

* Corresponding author.



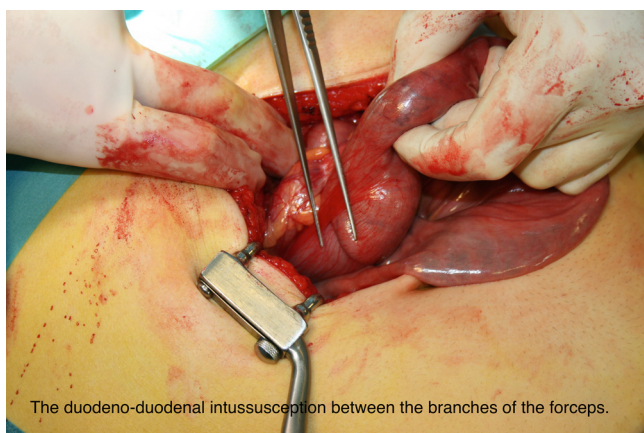
CT-scan demonstrating the intussusception with the characteristic double configuration of the intestinal wall.

Fig. 1. CT-scan demonstrating the intussusception with the characteristic double configuration of the intestinal wall.



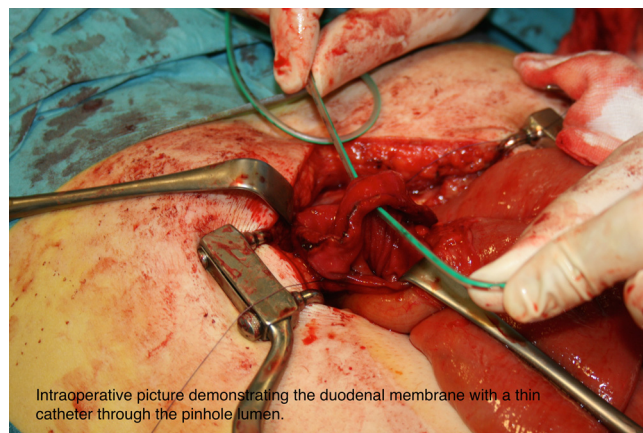
CT-scan demonstrating invagination of the head of the pancreas into duodenum (arrow).

Fig. 2. CT-scan demonstrating intussusception of the pancreas into duodenum (arrow).



The duodeno-duodenal intussusception between the branches of the forceps.

Fig. 3. The duodeno-duodenal intussusception between the branches of the forceps.



Intraoperative picture demonstrating the duodenal membrane with a thin catheter through the pinhole lumen.

Fig. 4. Intraoperative picture demonstrating the duodenal membrane with a thin catheter through the pinhole lumen.

3. Discussion

To our knowledge this is the first case report of pancreatitis resulting from duodenal invagination caused by a duodenal membrane. High peristaltic pressure proximal to the stenosis may have contributed to the development of the invagination, which may also have been facilitated by the mobile, non-rotated duodenum, which had a vertical straight course without retroperitoneal fixation.

Cases in which an intraluminal polypoid mass or tumour in the duodenum resulted in duodeno-jejunal intussusception have been reported [4,5]. In a few cases the intussusception involved the head of the pancreas, resulting in acute pancreatitis [5]. These patients were treated by surgical reduction of the intussusception and duodenal resection or polypectomy.

Membranous duodenal stenosis is often treated by duodenotomy and excision of the membrane followed by a duodenoplasty, or by duodeno-jejunal anastomosis, with good results [7,8].

In our case the patient had persistent symptoms of gastro-oesophageal reflux, which should have triggered an upper GI endoscopy; had this revealed the intestinal malformation the patient could have been treated in a timely fashion and which would have avoided this serious complication. The intussusception was not detected by ultrasonography but was revealed by a CT-scan. A previous study found that 27.1% of patients with intestinal malrotation had a history of congenital cardiovascular defects [9]. This suggests that all children with intermittent upper gastrointestinal symptoms such as vomiting, abdominal pain and gastro-oesophageal reflux, particularly those with a history of congenital heart malformation, should undergo upper GI endoscopy and imaging of the GI-tract to exclude GI anomalies.

4. Patient consent

Written informed consent was obtained from the patient for publication of this case report and accompanying images. A copy of the written consent is available for review by the Editor-in-Chief of this journal on request.

References

- [1] D.G. Begos, A. Sandor, I.M. Modlin, The diagnosis and management of adult intussusception, *Am. J. Surg.* 173 (2) (1997) 88–94.
- [2] G. Lianos, N. Xeropotamos, C. Bali, et al., Adult bowel intussusception: presentation, location, etiology, diagnosis and treatment, *Il Giornale di chirurgia* 34 (9–10) (2013) 280–283.
- [3] J. Gardner-Thorpe, R.H. Hardwick, N.R. Carroll, et al., Adult duodenal intussusception associated with congenital malrotation, *World J. Gastroenterol.: WJG* 13 (28) (2007) 3892–3894.

- [4] P. Neogi, A. Misra, R. Agrawal, Duodenal adenoma presenting as duodenojejunal intussusception, *Acta Bio-Med.: Atenei Parmensis* 79 (2) (2008) 137–139.
- [5] S.J. Jeon, S.E. Yoon, Y.H. Lee, et al., Acute pancreatitis secondary to duodenojejunal intussusception in Peutz-Jegher syndrome, *Clin. Radiol.* 62 (1) (2007) 88–91.
- [6] T.M. Hsieh, S.M. Sheen-Chen, C.C. Lin, Combination of adult intussusception and intestinal malrotation: an unusual presentation, *Digest. Dis. Sci.* 53 (11) (2008) 3037–3039.
- [7] F.C. Huang, J.H. Chuang, C.S. Shieh, Congenital duodenal membrane: a ten-year review, *Acta paediatrica Taiwanica = Taiwan Er Ke Yi Xue Hui Za Zhi* 40 (2) (1999) 70–74.
- [8] C. Mikaelsson, E. Arnbjornsson, C.M. Kullendorff, Membranous duodenal stenosis, *Acta paediatrica (Oslo, Norway: 1992)* 86 (9) (1997) 953–955.
- [9] M. Kouwenberg, R.S. Severijnen, L. Kapusta, Congenital cardiovascular defects in children with intestinal malrotation, *Pediatr. Surg. Int.* 24 (3) (2008) 257–263.

Open Access

This article is published Open Access at scimedirect.com. It is distributed under the [IJSCR Supplemental terms and conditions](#), which permits unrestricted non commercial use, distribution, and reproduction in any medium, provided the original authors and source are credited.