

Case report

Spontaneous rectus sheath hematomas in dengue hemorrhagic fever: A case report

Erni Juwita Nelwan^{a,c,*}, Frida Angelina^a, Randy Adiwinata^{a,c}, Sahat Matondang^b, Prasetyo Andriano^c^a Division of Tropical Medicine and Infectious Disease, Department of Internal Medicine, Dr. Cipto Mangunkusumo General Hospital, Faculty of Medicine Universitas Indonesia, Diponegoro Street Number 71, Jakarta, 10430, Indonesia^b Department of Radiology, Dr. Cipto Mangunkusumo General Hospital, Faculty of Medicine Universitas Indonesia, Diponegoro Street Number 71, Jakarta, 10430, Indonesia^c Abdi Waluyo Hospital, HOS Cokroaminoto Street number 31-33, Jakarta, Indonesia

ARTICLE INFO

Keywords:

Dengue hemorrhagic fever
Rectus sheath hematoma
Abdominal pain

ABSTRACT

Muscle hematomas are rare complications in dengue hemorrhagic fever (DHF). We report a case of 58-year-old female admitted with dengue fever who developed spontaneous rectus sheath hematoma complicating DHF. She presented with progressive thrombocytopenia with platelet count reaching 13000/ μ L at its lowest point. There was evidence of plasma leakage and persistent cough during the course of illness. During the recovery phase, she reported severe abdominal pain and developed hematoma in the right rectus sheath, which was confirmed by abdominal computed-tomography scan and serial magnetic resonance imaging. This complication during convalescent period of DHF needs to be recognized so it can be managed appropriately.

Introduction

Bleeding in Dengue hemorrhagic fever (DHF) cases commonly manifests as superficial bleeding (e.g. petechiae, ecchymosis, epistaxis, gum bleeding); although rare, organ-related bleeding such as severe gastrointestinal and intracranial hemorrhage may occur [1]. The pathogenesis of DHF remains unclear, there is only little correlation between hematological changes with clinical bleeding [2].

Rectus sheath hematoma (RSH) is characterized by bleeding within the rectus abdominis muscle sheath which may commonly be caused by ruptured epigastric vessels or a tear of the rectus muscle [3]. Some known risk factors of spontaneous RSH are female gender, anticoagulant drug usage, pregnancy, obesity, abdominal straining, severe vomiting, and persistent cough [4].

RSH complicating DHF is a rare clinical entity [5]. Here, we present a 58-year-old female with DHF who complained of acute abdominal pain due to spontaneous RSH occurring on the convalescent phase that was managed conservatively.

Case report

A 58-year-old female presented in our emergency room (ER) with an acute onset of fever one day prior to hospitalization. This was accompanied by nausea and vomiting of more than five times in the past 12 h. On physical examination, the body temperature was 39 °C. There was no other significant abnormality. She had no history of blood dyscrasias and was not maintained on anticoagulant therapy. Her initial laboratory results showed bicytopenia (hemoglobin 13.2 g/dL, hematocrit 37%, leukocytes 3200/ μ L, platelet count 134,000/ μ L) and positive for Dengue NS1 antigen. She was then admitted with the diagnosis of dengue fever.

The platelet count of our patient progressively decreased until the sixth day of admission, reaching the lowest level of 13,000/ μ L before it started to rise. The hemoglobin and hematocrit levels remained stable. The leukocyte remained low until the fifth day of admission when it started to increase to normal levels. There was no history of bleeding from any site. On the seventh day of admission, the patient complained of persistent cough especially when lying on the left side of the body. Electrocardiography (ECG) was normal. Chest X-ray showed massive pleural effusion of the right lung (Fig. 1A and B).

* Corresponding author at: Division of Tropical Medicine and Infectious Disease, Department of Internal Medicine, Dr. Cipto Mangunkusumo General Hospital, Faculty of Medicine Universitas Indonesia, Diponegoro Street Number 71, Jakarta, 10430, Indonesia.

E-mail addresses: ejnelwan@yahoo.com (E.J. Nelwan), Angelina.frida@gmail.com (F. Angelina), randyadiwinata@yahoo.com (R. Adiwinata), sahat92@yahoo.com (S. Matondang), amysomd@gmail.com (P. Andriano).

<http://dx.doi.org/10.1016/j.idcr.2017.08.004>

Received 4 August 2017; Accepted 6 August 2017

2214-2509/ © 2017 The Authors. Published by Elsevier Ltd. This is an open access article under the CC BY-NC-ND license (<http://creativecommons.org/licenses/by-nc-nd/4.0/>).

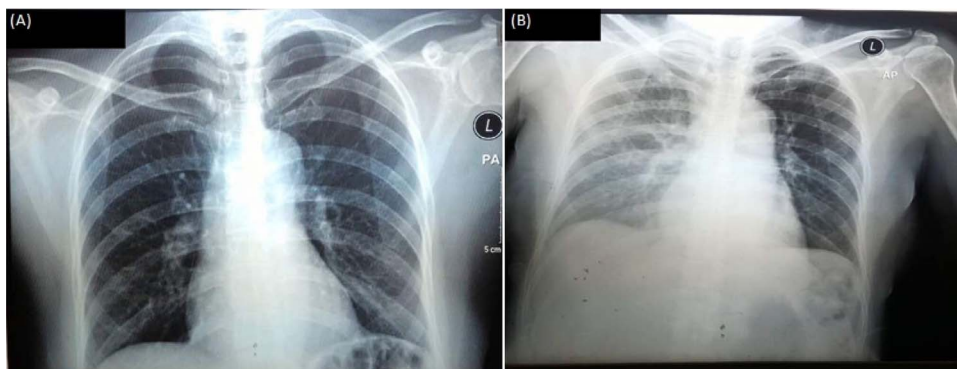


Fig 1. (A): Normal chest x ray at admission; (B): Massive pleural effusion of the right lung on the seventh day of hospitalization.

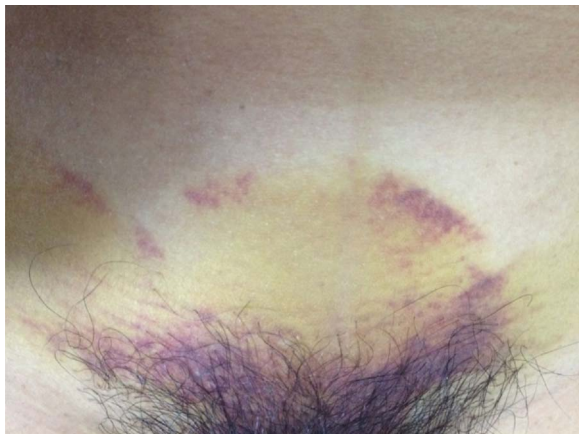

Fig. 2. Cullen's Sign on lower abdomen.

On the ninth day of admission, the patient complained of sudden pain in the lower abdominal region with a visual analogue score (VAS) of 8. On physical examination, there was a palpable, painful, firm, and nonpulsatile mass in the lower abdominal region with the size of approximately 9 cm × 6 cm that was positive for Cullen's sign (Fig. 2). The patient was referred for a surgical consult. Her laboratory results on that day showed hemoglobin 11.1 g/dL, hematocrit 32%, leukocyte 6400/μL, platelet count 116,000/μL. An abdominal computed tomography (CT) scan was performed which revealed a hematoma on the rectus abdominis muscle (not shown). The patient was managed with analgesics and discharged in a stable condition by her own request. She was advised to undergo serial magnetic resonance imaging (MRI) to further confirm the diagnosis and to return for follow up three days post-discharge.

Abdominal MRI scan with contrast result showed a mixed cystic solid lesion with a hyperintense rim on T1 and T2 at the right lower abdominal rectus sheath muscle measuring 11 × 7 × 3 cm (Fig. 3). A follow up abdominal MRI after three months showed a decreased in the size of the lesion at 2.9 × 3.6 × 2.5 cm (not shown).

Discussion

Bleeding complications in patients with DHF results from the combination of thrombocytopenia, increased vascular fragility, increased fibrinolysis, altered procoagulation and anticoagulation factors balance [6]. The critical stage of DHF is marked by defervescence and accompanied with higher degree of plasma leakage and low platelet count, which in turn may lead to circulatory failure and bleeding complications [7]. Muscles hematomas are rare complications of DHF. The common sites of intramuscular hematomas in the abdomen are the rectus sheath, psoas and iliac muscles. RSH of the anterior abdominal wall is caused by the rupture of the superior or inferior epigastric artery or a tear of the rectus muscle. Increased abdominal tension due to persistent cough as seen in this patient may precipitate RSH occurrence. RSH is usually frequent and self-limiting in elderly females. However, it can cause an expanding hematoma turning into a hemoperitoneum [8]. Typical clinical manifestations of RSH are palpable abdominal mass accompanied with sudden or increasing unilateral abdominal pain. Bleeding may be severe which may result in hypovolemic conditions reflected by hypotension, tachycardia, and pallor. Fothergill sign is useful to differentiate whether the location of the abdominal mass is part of the abdominal wall or in the abdomen cavity; in cases of RSH, the abdominal mass may become more painful and fixed. Positive Carnett's sign may suggest the abdominal wall as the source of the pain rather than a visceral organ. In our case, we also found periumbilical ecchymosis which indicate abdominal wall hemorrhage (Cullen's sign) [4]. The imaging modalities useful in the diagnosis of RSH are ultrasonography (USG), CT-scan, and MRI. USG is the initial procedure of choice because of its high sensitivity rates, cost-effectivity, and absence of radiation. However, USG studies may confuse these hematomas with abdominal wall tumors. CT is superior from USG in the localization of the hematoma. CT also provides additional information about the extent and exact size of the hematoma. MRI is more superior than CT scan in the determination of the age of the hematoma aside from obtaining information about the extent and size of hematoma. Our patient presented with a hematoma located within the muscle but bleeding occurred into the space between the transversalis fascia and the muscle [9,10]. Conservative treatment including intravenous hydration, blood

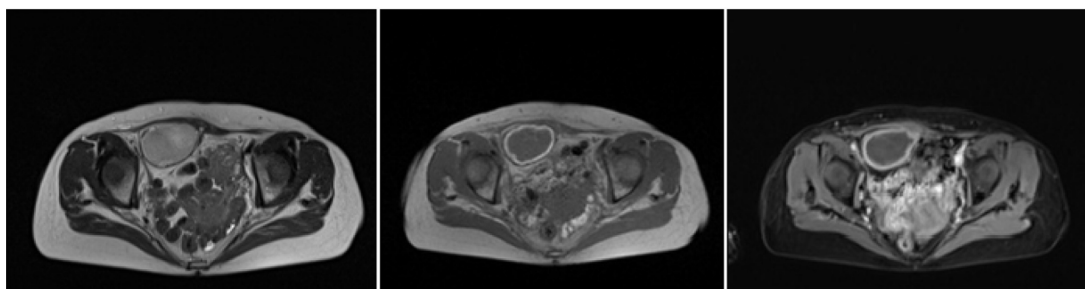


Fig. 3. Abdominal MRI with contrast at diagnosis of RSH.

transfusion and strict monitoring are appropriate in most of the settings with abdominal wall hematomas as the hematoma is usually self-limiting and completely reabsorbed. Surgical intervention or transcatheter arterial embolization is recommended only when conservative management fails [11].

In conclusion, it is important to be cautious in the convalescent phase of dengue fever for bleeding complications like muscle hematomas. Imaging modalities may aid the RSH diagnosis and lead to the treatment of choice.

This case report did not receive any specific grant from funding agencies in the public, commercial, or not-for-profit sectors.

Funding

This case report did not receive any specific grant from funding agencies in the public, commercial, or not-for-profit sectors.

Conflicts of interest

The authors declare no conflict of interest.

Acknowledgement

None

References

- [1] Kalayanarooj S. Clinical manifestations and management of Dengue/DHF/DSS. *Trop Med Health* 2011;39(Suppl 4):83–7.
- [2] de Azeredo EL, Monteiro RQ, de Oliveira Pinto LM. Thrombocytopenia in dengue: interrelationship between virus and the imbalance between coagulation and fibrinolysis and inflammatory mediators. *Mediat Inflamm* 2015;2015:313842.
- [3] Aktürk OM, Kayıoğlu SI, Aydoğan İ, Dinç T, Yıldız B, Cete M, et al. Spontaneous rectus sheath hematoma: an overview of 4-Year single center experience. *Indian J Surg* 2015;77(Suppl 3):1219–21.
- [4] Eckhoff K, Wedel T, Both M, Bas K, Maass N, Alkatout I. Spontaneous rectus sheath hematoma in pregnancy and a systematic anatomical workup of rectus sheath hematoma: a case report. *J Med Case Rep* 2016;10:292.
- [5] Bhat KJ, Shovkat R, Samoon HJ. Abdominal haematomas and dengue fever: two different cases of spontaneous psoas muscle haematoma and bilateral rectus sheath haematoma complicating dengue haemorrhagic fever. *J Vector Borne Dis* 2015;52(4):339–41.
- [6] Wills BA, Oragui EE, Stephens AC, Daramola OA, Dung NM, Loan HT, et al. Coagulation abnormalities in dengue hemorrhagic fever: serial investigations in 167 Vietnamese children with dengue shock syndrome. *Clin Infect Dis* 2002;35(3):277–85.
- [7] Martina BE, Koraka P, Osterhaus AD. Dengue virus pathogenesis: an integrated view. *Clin Microbiol Rev* 2009;22(4):564–81.
- [8] Cherry WB, Mueller PS. Rectus sheath hematoma: review of 126 cases at a single institution. *Medicine (Baltimore)* 2006;85(2):105–10.
- [9] Sharma A, Bhatia S, Singh RP, Malik G. Dengue fever with rectus sheath hematoma: a case report. *J Fam Med Prim Care* 2014;3(2):159–60.
- [10] Chawla S. Rectus sheath haematoma. *Med J Armed Forces India* 2002;58(4):355–6.
- [11] Yamada Y, Ogawa K, Shiomi E, Hayashi T. Images in cardiovascular medicine: bilateral rectus sheath hematoma developing during anticoagulant therapy. *Circulation* 2010;121(15):1778–9.