

# Microincision phacoemulsification combined with sutureless transpupillary passive silicone oil removal

Mithun Thulasidas, Hemlata Gupta, Mahipal S Sachdev, Avindra Gupta<sup>1</sup>, Lalit Verma<sup>1</sup>, Sanchi Vohra

**Purpose:** To evaluate the outcomes of combined microincision phacoemulsification with sutureless transpupillary silicone oil (SO) removal using an irrigation probe of bimanual irrigation/aspiration. **Methods:** We conducted a single-center retrospective study, including patients who had undergone phacoemulsification with transpupillary removal of SO, which had been used for intraocular tamponade after a previous pars plana vitrectomy. Outcome measures were corrected distance visual acuity (CDVA), refractive error, intraocular pressure (IOP), and endothelial cell count (ECC) evaluated preoperatively and postoperatively at 3-month follow-up. Any intraoperative or postoperative complications, duration of surgery, and final retinal status at 3 months were also noted. **Results:** Seventy-four eyes (74 patients) were analyzed. The mean interval between SO placement and cataract surgery was 4.73 months (standard deviation [SD]: 1.02). CDVA improved in 66 (89.2%) eyes and remained the same in 8 (10.8%) eyes ( $P < 0.001$ ). The mean postoperative spherical equivalent was  $-0.96D$  (SD: 0.75) at 3 months ( $P < 0.001$ ). There was a significant drop in IOP from 15.08 mmHg (SD: 2.67) preoperatively to 11.64 mmHg (SD: 2.02) postoperatively ( $P < 0.001$ ). The average ECC loss was only 5.7% at 3 months postoperatively. The mean surgical duration was 17.20 min (SD: 7.02). One patient had retinal redetachment and required resurgery. At 3 months, the retina was attached in all patients. **Conclusion:** Combined microincision phacoemulsification with transpupillary passive SO removal using irrigation probe of bimanual irrigation/aspiration is a safe, effective, and less invasive technique that offers the main advantage of reduced surgical trauma, and should be reserved for patients with a stable retina, not requiring additional surgical intervention.

**Key words:** Phacoemulsification, posterior capsulorhexis, retinal detachment, silicone oil removal, transpupillary

Video Available on:  
www.ijo.in

Access this article online

Website:  
www.ijo.in

DOI:  
10.4103/ijo.IJO\_3538\_20

Quick Response Code:



Silicone oil (SO) is commonly used as endotamponade in pars plana vitrectomy for complicated cases such as giant retinal tears and tractional retinal detachment (RD), which provides a clear view of the fundus in comparison with gas and also inhibits postoperative vitreous hemorrhage.<sup>[1-3]</sup> However, the incidence and severity of complications associated with intraocular SO such as secondary glaucoma, posterior subcapsular cataract (PSC), band keratopathy, and possible neural toxicity increase with the duration of SO tamponade.<sup>[4-6]</sup> Therefore, it is suggested that SO should be removed when it is no longer needed to keep the retina attached.<sup>[7,8]</sup> The occurrence of PSC is seen in nearly 100% of the eyes in whom SO remains *in situ* for more than 3 months.<sup>[9,10]</sup> Even early removal of SO (within 6 weeks of injection) is associated with a high incidence of late cataracts.<sup>[11]</sup> When a visually significant cataract in a SO-filled eye with visual potential develops, cataract surgery is indicated with SO removal.<sup>[12,13]</sup>

Different techniques of combined phacoemulsification and SO removal through a planned posterior capsulorhexis has been described.<sup>[12-24]</sup> SO removal without the use of a separate

infusion mechanism was first described by Jonas *et al.* where SO was removed through a planned posterior capsulorhexis and sclerocorneal tunnel, using a 20-gauge cannula.<sup>[14]</sup> These approaches use either active or passive phenomena for SO removal. However, no technique has used the irrigation probe of bimanual irrigation/aspiration (I/A) for passive hydrodynamic expression of SO without active aspiration, through a 2.2 mm clear corneal incision. The purpose of the present study was to evaluate the outcomes of combined microincision phacoemulsification with transpupillary passive SO removal using an irrigation probe of bimanual I/A.

## Methods

This single-center retrospective study conducted at our eye hospital analyzed the data of patients who had undergone microincision phacoemulsification combined with transpupillary SO removal between January 2018 and December 2019. The study was approved by the institutional

Cataract and Refractive Surgery Services, Centre for Sight, Safdarjung Enclave, <sup>1</sup>Vitreoretinal Services, Centre for Sight, New Delhi, India

**Correspondence to:** Dr. Mithun Thulasidas, Cataract and Refractive Surgery Services, Centre for Sight, B-5/24, Safdarjung Enclave, New Delhi, Delhi - 110 029, India. E-mail: mithun.thulasidas@gmail.com

Received: 25-Nov-2020

Revision: 25-Feb-2021

Accepted: 13-Mar-2021

Published: 25-Aug-2021

This is an open access journal, and articles are distributed under the terms of the Creative Commons Attribution-NonCommercial-ShareAlike 4.0 License, which allows others to remix, tweak, and build upon the work non-commercially, as long as appropriate credit is given and the new creations are licensed under the identical terms.

**For reprints contact:** WKHLRPMedknow\_reprints@wolterskluwer.com

**Cite this article as:** Thulasidas M, Gupta H, Sachdev MS, Gupta A, Verma L, Vohra S. Microincision phacoemulsification combined with sutureless transpupillary passive silicone oil removal. Indian J Ophthalmol 2021;69:2311-6.

ethics committee and adhered to the tenets of the Declaration of Helsinki. Informed consent was obtained from all patients before undergoing the procedure.

All patients had previously undergone pars plana vitrectomy and infusion of 1000 centistokes SO for different vitreoretinal pathologies, before the development of a visually significant cataract. Intraocular lens (IOL) power calculation for cataract surgery was carried out in SO mode by applying the Sanders-Retzlaff-Kraff-Theoretical (SRK-T) formula in IOL Master 700 (Carl Zeiss Meditec, Jena, Germany). Those patients with emulsified SO, unstable retina, open break, epiretinal membrane, subretinal fluid, active proliferative process traction on the retina or unhealthy corneal endothelium at the time of cataract surgery, and <3 months follow-up were excluded.

### Surgical technique

The procedure was performed with the patient under peribulbar local anesthesia. The local block consisted of a 50:50 mixture of 3 mL 2% lignocaine and 3 mL 0.5% bupivacaine mixed with 1 mL sodium hyaluronidase and was administered in a standard fashion. The procedure consisted of a 2.2 mm corneal incision at the superior/superotemporal position, two side-port paracentesis incisions at two clock hours away from the main incision, injection of an ophthalmic viscoelastic device (OVD) into the anterior chamber, continuous curvilinear capsulorhexis, hydrodissection, endocapsular phacoemulsification of lens nucleus, aspiration of the remaining cortical lens material using I/A, and creation of a preplanned posterior capsulorhexis using utrata forceps with an approximate diameter of 3–4 mm in the central area of the posterior lens capsule. The irrigation probe of bimanual I/A was then kept in the midvitreous cavity through the posterior capsulorhexis. The stream of fluid floated the SO out through the pupil and the corneal incision. The aspiration probe was used to depress the sclera at the site of the main corneal incision. Since SO is buoyant over water, it could float upon the surface, and scleral depression was used to move SO to a more central position beneath the posterior capsulorhexis. SO was expressed till the last bubble was seen coming out in toto. A fundus evaluation was done with an indirect ophthalmoscope to ensure that the retina was attached, and SO was completely removed. The capsular bag was then expanded with OVD, and foldable hydrophobic acrylic heparin-coated IOL with 360° square edge design and optic diameter of 6 mm was implanted in the capsular bag or the ciliary sulcus (with optic capture) if the bag was unstable. OVD was aspirated using I/A, wounds were hydrated, and an intracameral injection of moxifloxacin (0.01%) was given. The main corneal incision was sutured with a 10–0 nylon suture. Subconjunctival dexamethasone and gentamicin were given. This technique of sutureless transpupillary passive SO removal is shown in Video Clip 1.

Postoperative medications included topical antibiotics for 10 days, topical steroids slowly tapered over 4–6 weeks, and topical nonsteroidal anti-inflammatory drugs for 3 weeks. All patients were evaluated on the first postoperative day and at 1 week, 3 weeks, and 3 months after surgery and, in addition, as indicated clinically.

### Data collection

Demographic data collected from the records of the patients included age, gender, type of cataract, axial length (using IOL Master 700), primary diagnosis for the vitreoretinal surgery,

and the interval between SO placement and cataract extraction. Data obtained before combined phacoemulsification and SO removal included corrected distance visual acuity (CDVA; using Snellen's chart) measured as logarithm of the minimum angle of resolution (logMAR), refractive error measured as spherical equivalent, intraocular pressure (IOP; using noncontact tonometer), and corneal endothelial cell count (ECC; using specular microscopy [Topcon SP 3000P]).

Postoperative data included CDVA, refractive error, IOP, ECC, and final retinal status at 3-month follow-up. Any intraoperative or postoperative complications and the duration of surgery were also noted.

### Statistical analysis

Continuous variables were presented as means  $\pm$  standard deviation. Categorical variables were presented as frequency and percentage. Normality of data was tested by Kolmogorov–Smirnov test. Paired Student's *t*-test was applied to analyze the data. A probability value (*P*-value) of <0.05 was considered statistically significant at a 95% confidence level. The statistical package for social sciences (SPSS) version 24.0 was used in the analysis.

## Results

Seventy-four eyes of 74 patients (59 males and 15 females) were included in this study. The demographic characteristics of the study population are shown in Table 1. The mean age at the time of cataract surgery was  $58.74 \pm 7.84$  years, ranging from 29 to 70 years. The majority (87.8%) of the patients were in the age group of 50 to 70 years. The most common indication for the use of SO was rhegmatogenous RD in 48 eyes (64.9%), with the second most common indication being tractional RD in 24 (32.4%) patients with diabetes. All eyes had SO placed as a primary procedure, and no additional encircling or segmental explant was used. The mean interval between SO placement and subsequent cataract surgery was  $4.73 \pm 1.02$ , ranging from 3 to 7 months. The most common type of cataract observed was a combination of nuclear sclerosis with PSC, and the mean axial length was  $23.79 \pm 0.68$  mm.

**Table 1: Demographic characteristics of the study population**

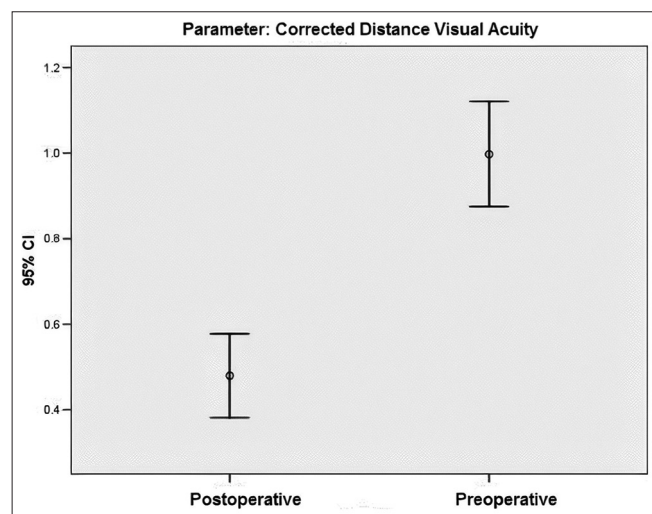
Characteristics	<i>n</i>
Number of eyes (patients)	74 (74)
Age (years), means $\pm$ SD	58.74 $\pm$ 7.84
Gender	
Male	59
Female	15
Primary diagnosis for the vitreoretinal surgery	
Rhegmatogenous RD	48
Tractional RD (Diabetic retinopathy)	24
Traumatic RD	2
Interval between SO placement and cataract surgery (months), means $\pm$ SD	4.73 $\pm$ 1.02
Type of cataract	
PSC+Nuclear sclerosis	53
PSC	21
Axial length (mm), means $\pm$ SD	23.79 $\pm$ 0.68

SD: Standard deviation, RD: Retinal detachment, SO: Silicone oil, PSC: Posterior subcapsular cataract

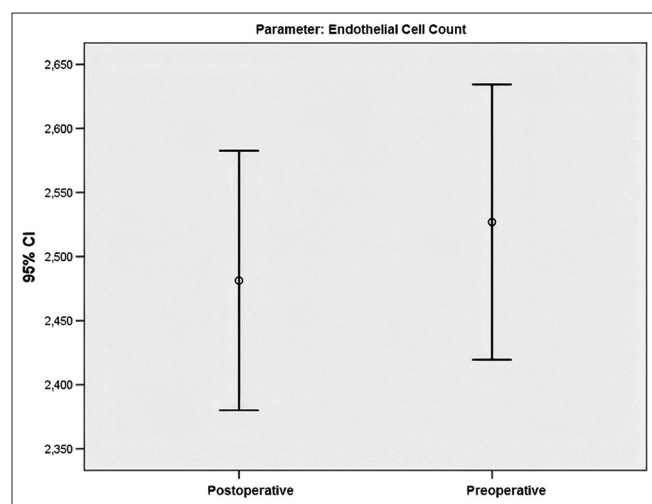


The mean preoperative logMAR CDVA improved from  $1 \pm 0.53$  to  $0.48 \pm 0.42$  at 3 months follow-up ( $P < 0.001$ ) [Fig. 1]. CDVA improved in 66 (89.2%) eyes and remained the same in 8 (10.8%) eyes. Fifty (67.6%) eyes had a gain of  $\geq 2$  lines of visual acuity. At 3 months, 8 (10.8%) eyes had a CDVA of logMAR  $> 1.0$ , 28 (37.8%) eyes had a CDVA of logMAR  $1.0-0.6$  and 38 eyes (51.4%) had a CDVA of logMAR  $\leq 0.48$ . No patients reported deterioration of visual acuity. The mean spherical equivalent decreased from  $6.3 \pm 0.8$  dioptres (D) preoperatively to  $-0.96 \pm 0.75$  D at the end of 3 months ( $P < 0.001$ ).

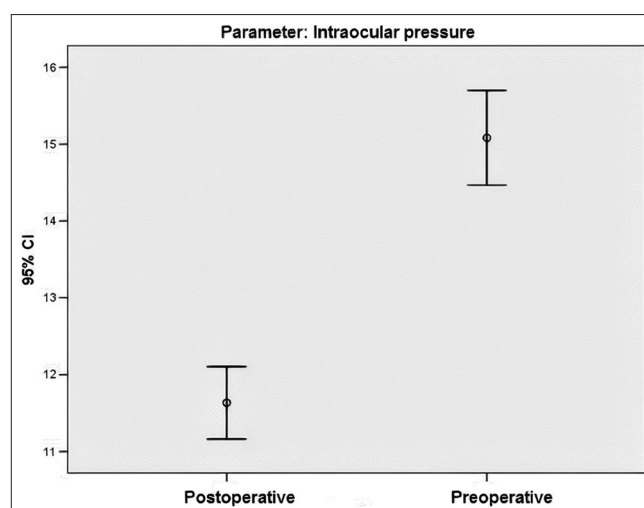
The mean preoperative IOP was  $15.08 \pm 2.67$  mmHg and the mean postoperative IOP at 3 months follow-up was  $11.64 \pm 2.02$  mmHg ( $P < 0.001$ ) [Fig. 2]. Seven (9.5%) patients who were started on ocular hypotensive drugs preoperatively (secondary to SO tamponade), did not require the medications after SO removal. Hypotony was not encountered in any of the patients during the postoperative phase.



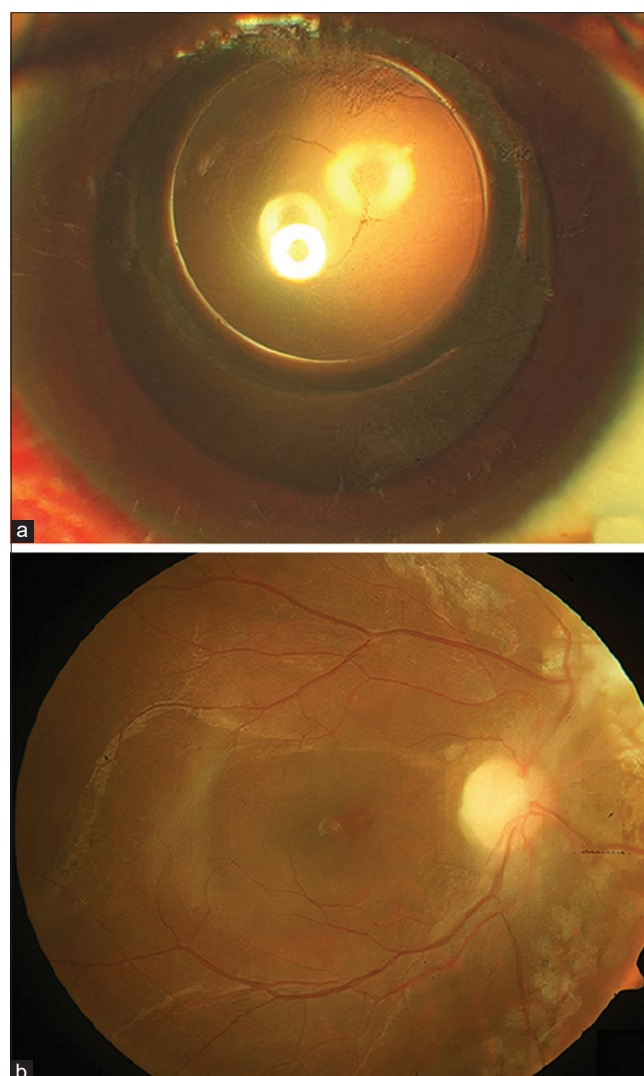
**Figure 1:** Preoperative and postoperative mean corrected distance visual acuity (logMAR), Paired *t*-test  $P < 0.001$ , highly significant (at the end of 3 months)



**Figure 3:** Preoperative and postoperative mean endothelial cell count, Paired *t*-test  $P > 0.05$ , no significant difference (at the end of 3 months)



**Figure 2:** Preoperative and postoperative mean intraocular pressure, Paired *t*-test  $P < 0.001$ , highly significant (at the end of 3 months)



**Figure 4:** Postoperative image of an eye with (a) visualization of posterior capsulorhexis and (b) attached retina at 3 months

The mean difference between pre and postoperative ECC at 3 months was  $145.66 \pm 65.19$  cells/mm<sup>3</sup> [Fig. 3]. The average percentage of endothelial cell loss was 5.7%. No patients had ECC <2,000 cells/mm<sup>3</sup> or persistent corneal edema at 3 months postoperatively.

The mean surgical duration was  $17.20 \pm 7.02$  min. None of the patients developed any intraoperative complications. There were no cases of vitreous hemorrhage, choroidal hemorrhage, cystoid macular edema, or IOL dislocation. No residual SO droplets were noted in the vitreous cavity, on the IOL surfaces, or in the anterior chamber. One patient had redetachment of the retina after 4 days of SO removal and required resurgery. At the end of 3 months, the retina was attached in all patients. Fig. 4 shows the postoperative image of an eye with visualization of posterior capsulorhexis and attached retina at 3 months.

## Discussion

Pars plana vitrectomy combined with SO tamponade is a widely used technique for RD repair.<sup>[1-3]</sup> However, SO can cause anterior segment complications, the most common being cataract formation.<sup>[4-6,9,10]</sup> The exact mechanism for cataract formation induced by SO is unclear. SO placement against the posterior capsule and the induction of proliferation of lens epithelium by the underlying complicated RD may contribute to cataract formation.<sup>[8,9,15,25]</sup> Previous studies have reported different techniques for cataract extraction combined with SO removal without the use of a separate infusion port.<sup>[12-14,16,17,19,20,22-24]</sup> Our technique is different from the other approaches in that we used the irrigation probe of bimanual I/A for passive hydrodynamic expression of SO (without active aspiration) through a 2.2 mm clear corneal incision.

Phacoemulsification combined with the active aspiration of SO using I/A handpiece through a planned posterior capsulorhexis without a separate infusion port was described by Frau *et al.* and Boshra *et al.*<sup>[19,23]</sup> Conversely, phacoemulsification with passive SO removal was previously described by Assi *et al.* and Boscia *et al.*<sup>[12,17]</sup> However, Assi *et al.* used a 20-gauge Rycroft cannula, and Boscia *et al.* used a 16-gauge curved cannula attached to balanced salt solution infusion for passive hydrodynamic expression of SO through the posterior capsulorhexis.<sup>[12,17]</sup> In the present study, we have used the irrigation probe of bimanual I/A to remove SO exclusively by the passive phenomenon.

There was a significant improvement in CDVA from  $1 \pm 0.53$  preoperatively to  $0.48 \pm 0.42$  at 3 months follow-up ( $P < 0.001$ ) in our study, although most of the patients had a guarded visual prognosis. The postoperative CDVA improved in 66 (89.2%) eyes and remained stable in 8 (10.8%) eyes. These results are comparable to those reported by Zhu *et al.*, and Dada *et al.*<sup>[13,18]</sup> Eight eyes had no improvement in visual acuity with logMAR CDVA >1.0 due to foveal thinning in four eyes and macular pucker in four eyes.

Achieving accurate refractive results in SO-filled eyes often poses a dilemma in combined surgery as SO causes refractive changes and hampers IOL power calculation. The velocity of sound in SO of viscosity 1000 centistokes (987 m/s) is lower than in vitreous humor (1532 m/s).<sup>[26]</sup> This causes an apparent increase in axial length in SO-filled eyes when measured

by echography.<sup>[27,28]</sup> Though most biometry machines allow conversion of the speed of sound through vitreous to 987 m/s, the absorption of sound waves through SO and the resultant loss of sensitivity often make it impossible to get an accurate A-scan.<sup>[29]</sup> In the present study, IOL power calculation was carried out in SO mode by applying the SRK-T formula in the new swept-source optical coherence tomography (SS-OCT) based IOL Master 700 and the outcomes were reasonably accurate with a mean spherical equivalent of  $-0.96 \pm 0.75$  D postoperatively at 3 months. This is in comparison to the study by Boscia *et al.*, which reported a mean postoperative spherical equivalent of  $-0.86 \pm 0.89$  D.<sup>[12]</sup> However, Boscia *et al.* had calculated the IOL power by the modified SRK II formula using the axial length of the fellow eye and taking the preoperative refractive error of the operated eye into consideration.<sup>[12]</sup> The IOL Master 700 has an in-built mode for SO-filled eyes which enables the proper density and velocity adjustments automatically.<sup>[30]</sup> The SS-OCT technology provides the benefits of image-based measurement allowing the surgeon to view the complete longitudinal section of the eye, identification of irregular eye geometries such as lens tilt, and imaging of the fovea to ensure correct fixation during the measurements. Moreover, it has been shown to have better light penetration through ocular tissues, especially in cases of dense PSC.<sup>[31]</sup>

There was a statistically significant drop in IOP after SO removal ( $P < 0.001$ ). There were no cases of postoperative hypotony (<6 mmHg) or raised IOP (>21 mmHg), which is comparable to the study by Boscia *et al.*<sup>[12]</sup> Preoperatively, seven patients had high IOP secondary to SO tamponade and were started on ocular hypotensive medications. Postoperatively, none of the patients required ocular hypotensive therapy.

Damage caused to corneal endothelium by SO flowing across the anterior chamber and out of the eye is a significant concern. Other factors such as ultrasound power used, the density of the nucleus, axial length, and experience of the surgeon also influence endothelial cell loss.<sup>[22]</sup> However, in our study, the average endothelial cell loss was only 5.7% at the end of 3 months postoperatively. No patients had postoperative corneal decompensation or persistent corneal edema. Cacciatori *et al.*, in their prospective study, reported an endothelial cell loss of 6.7% at 6 weeks in patients who underwent combined phacoemulsification and active aspiration of SO via anterior approach.<sup>[22]</sup> Boscia *et al.* in their retrospective study showed that the endothelial cell loss (8.3%) of patients undergoing phacoemulsification and IOL implantation was not statistically different from the endothelial cell loss (11.2%) of patients undergoing combined phacoemulsification and passive SO removal.<sup>[12]</sup>

The mean duration of surgery in the present study was  $17.20 \pm 7.02$  min, similar to the report by Boscia *et al.*<sup>[12]</sup> On the other hand, Xu *et al.* reported a mean surgical duration of  $53.6 \pm 8.2$  min with a transpupillary approach of SO removal. Nevertheless, the time taken with the 23-gauge approach in their study was  $58.8 \pm 9.5$  min, which was significantly longer than the transpupillary approach.<sup>[24]</sup> This difference in surgical duration might be due to variation in the competence of the surgeon.

In our study, we encountered retinal redetachment only in one patient (1.4%) after 4 days of SO removal, which could be



due to residual traction leading to the opening of the break and the formation of a secondary break. This rate is significantly lower compared with other studies.<sup>[12,14,17,19,20,24]</sup> SO was replaced, and the retina was attached at the end of the last follow-up. This variation in the redetachment rate might be due to the difference in the study population where patients with unstable retina, open break, epiretinal membrane, subretinal fluid, and active proliferative process traction on the retina were excluded in the present study. Moreover, all the patients received a preoperative prophylactic 360° peripheral laser retinopexy in our study. No intraoperative complications were observed. There were no cases of vitreous hemorrhage, cystoid macular edema, or IOL dislocation, in contrast to the reports by other studies.<sup>[12,14,15,17,19]</sup> It is essential to emphasize that this technique should be performed by an experienced surgeon to minimize the complications.

The combined technique of phacoemulsification with transpupillary passive SO removal is less invasive, avoids conjunctival and scleral incisions, and avoids iris prolapse. Postoperative dry eye and ocular surface abnormalities are also reduced due to the sutureless approach. The pars plana and peripheral retina do not interfere, thus decreasing the risk of peripheral iatrogenic retinal breaks, subretinal infusion, and vitreous or choroidal hemorrhage.<sup>[14]</sup> Moreover, it provides the benefits of a shorter duration of surgery and faster visual rehabilitation and prevents the need to perform a postoperative neodymium-YAG capsulotomy on a thickened posterior capsule.<sup>[9,10]</sup> Self-sealing 2.2 mm micro clear corneal incisions and the use of viscoelastic agents help the surgeon to achieve more control over anterior chamber fluidics throughout all stages of the surgery. They also avoid collapse of the anterior chamber and intraoperative hypotony.<sup>[12]</sup>

The main drawback of this approach lies in the violation of the posterior capsule integrity, which increases the theoretical risk of capsular bag instability, postoperative RD, and cystoid macular edema.<sup>[32,33]</sup> Also, it is sometimes difficult to perform capsulorhexis if posterior capsule plaque is present. In case the posterior capsulotomy is too large or irregular with inadequate capsular support, the IOL can be safely implanted in the ciliary sulcus in front of the anterior lens capsule. Contrarily, the absence of vitreous traction decreases the risk of postoperative RD and cystoid macular edema. These complications are more likely to occur as a sequel to the complicated nature of the initial RD and severe proliferative vitreoretinopathy rather than due to the technique of SO removal.<sup>[34]</sup> However, residual vitreous under the lens can be present and exert traction on the anterior retina. Hence, a careful examination of the posterior capsulorhexis tear should be done to look for any residual vitreous, before introducing the irrigation probe to avoid traction on the residual vitreous.<sup>[19]</sup>

Moreover, a posterior capsulorhexis should be performed cautiously and only by an experienced surgeon, as an unusually large posterior capsulotomy may lead to IOL dislocation into the vitreous cavity postoperatively. The specular microscopy should be noted and studied in these eyes before surgery to look for any preexisting corneal endothelial damage or dysfunction.<sup>[18]</sup> Patients with proliferative vitreoretinopathy may need laser photocoagulation or additional membrane peeling for macular pucker or develop recurrent peripheral proliferation.<sup>[14]</sup> Hence, this approach must be reserved for cases with a stable retina, completely sealed breaks, no epiretinal

membrane or subretinal fluid, or active proliferative process traction on the retina. Also, cases with preexisting zonular weakness or lens subluxation should be avoided.

The limitations of the study include its retrospective design and short-term follow-up of 3 months. Prospective studies with a longer follow-up may provide more significant results.

## Conclusion

Combined microincision phacoemulsification with a passive hydrodynamic expression of SO using irrigation probe of bimanual I/A through a planned posterior capsulorhexis is a safe, effective, and less invasive technique that offers the advantages of reduced surgical trauma, rapid visual rehabilitation, and decreased incidence of postoperative capsular thickening. We believe that this technique should be reserved for patients with a stable retina and closed retinal breaks, not in need of additional vitreoretinal procedures at the time of SO removal.

## Financial support and sponsorship

Nil.

## Conflicts of interest

There are no conflicts of interest.

## References

1. Berrocal MH, Chenworth ML, Acaba LA. Management of giant retinal tear detachments. *J Ophthalmic Vis Res* 2017;12:93-7.
2. Balakrishnan D, Jain B, Nayaka A, Rani PK, Mukundaprasad V, Jalali S. Role of tamponade in vitrectomy for proliferative diabetic retinopathy with vitreous hemorrhage. *Semin Ophthalmol* 2017;32:488-91.
3. Yeh PT, Yang CM, Yang CH. Distribution, reabsorption, and complications of preretinal blood under silicone oil after vitrectomy for severe proliferative diabetic retinopathy. *Eye (Lond)* 2012;26:601-8.
4. Abrams GW, Azen SP, Barr CC, Lai MY, Hutton WL, Trese MT, *et al.* The incidence of corneal abnormalities in the Silicone Study. Silicone Study Report 7. *Arch Ophthalmol* 1995;113:764-9.
5. Barr CC, Lai MY, Lean JS, Linton KL, Trese M, Abrams G, *et al.* Postoperative intraocular pressure abnormalities in the Silicone Study. Silicone Study Report 4. *Ophthalmology* 1993;100:1629-35.
6. Grzybowski A, Pieczynski J, Ascaso FJ. Neuronal complications of intravitreal silicone oil: An updated review. *Acta Ophthalmol* 2014;92:201-4.
7. Zilis JD, McCuen BW II, de Juan E Jr, Stefansson E, Machemer R. Results of silicone oil removal in advanced proliferative vitreoretinopathy. *Am J Ophthalmol* 1989;108:15-21.
8. Hutton WI, Azen SP, Blumenkranz MS, Lai MY, McCuen BW, Han DP, *et al.* The effects of silicone oil removal in the Silicone Study Report 6. *Arch Ophthalmol* 1994;112:778-85.
9. Leaver PK, Grey RHB, Garner A. Silicone oil injection in the treatment of massive preretinal retraction. II. Late complications in 93 eyes. *Br J Ophthalmol* 1979;63:361-7.
10. Federman Jay L, Schubert HD. Complications associated with the use of silicone oil in 150 eyes after retina-vitreous surgery. *Ophthalmology* 1988;95:870-6.
11. Gonvers M. Temporary silicone oil tamponade in the management of retinal detachment with proliferative vitreoretinopathy. *Am J Ophthalmol* 1985;100:239-45.
12. Boscia F, Recchimurzo N, Cardascia N, Sborgia L, Ferrari TM, Carlo Sborgia. Phacoemulsification with transpupillary silicone

- oil removal and lens implantation through a corneal incision using topical anesthesia. *J Cataract Refract Surg* 2003;29:1113-9.
13. Zhu YC, Yuan DQ, Xie P, Liu XY, Yuan ST, Liu QH. Phacoemulsification combined with transpupillary removal of silicone oil and intracapsular intraocular lens implantation. *Int J Ophthalmol* 2017;10:1693-7.
14. Jonas JB, Budde WM, Panda-Jonas S. Cataract surgery combined with transpupillary silicone oil removal through planned posterior capsulotomy. *Ophthalmology* 1998;105:1234-7.
15. Larkin GB, Flaxel CJ, Leaver PK. Phacoemulsification and silicone oil removal through a single corneal incision. *Ophthalmology* 1998;105:2023-7.
16. Tanner V, Haider A, Rosen P. Phacoemulsification and combined management of intraocular silicone oil. *J Cataract Refract Surg* 1998;24:585-91.
17. Assi A, Woodruff S, Gotzaridis E, Bunce C, Sullivan P. Combined phacoemulsification and transpupillary drainage of silicone oil: Results and complications. *Br J Ophthalmol* 2001;85:942-5.
18. Dada VK, Talwar D, Sharma N, Dada T, Sudan R, Azad RV. Phacoemulsification combined with silicone oil removal through a posterior capsulorhexis. *J Cataract Refract Surg* 2001;27:1243-7.
19. Frau E, Lautier-Frau M, Labetoulle M, Hutchinson S, Offret H. Phacoemulsification combined with silicone oil removal through the posterior capsulorhexis tear. *Retina* 2002;22:158-62.
20. Avci R. Cataract surgery and transpupillary silicone oil removal through a single scleral tunnel incision under topical anesthesia; sutureless surgery. *Int Ophthalmol* 2001;24:337-41.
21. Loncar VL, Petric I, Vataavuk Z, Bencić G, Andrijević-Derk B, Mandić Z. Phacoemulsification and silicone oil removal through the planned posterior capsulorhexis. *Coll Antropol* 2005;29:63-6.
22. Cacciatori M, Aspinall P, Bennett HG, Singh J. Corneal endothelial evaluation after phacoemulsification and silicone oil removal via an anterior approach. *Retina* 2007;27:755-8.
23. Boshra J, Narvaez J, Gimbel HV. Simplified technique for combined silicone oil removal during phacoemulsification with standard or toric intraocular lens implantation. *J Cataract Refract Surg* 2009;35:1853-6.
24. Xu W, Cheng W, Zhuang H, Guo J, Xu G. Safety and efficacy of transpupillary silicone oil removal in combination with micro-incision phacoemulsification cataract surgery: Comparison with 23-gauge approach. *BMC Ophthalmol* 2018;18:200.
25. Scott JD. Lens epithelial proliferation in retinal detachment. *Trans Ophthalmol Soc UK* 1982;102:385-9.
26. Hoffer KJ. Ultrasound velocities for axial eye length measurement. *J Cataract Refract Surg* 1994;20:554-62.
27. Murray DC, Potamitis T, Good P, Kirkby GR, Benson MT. Biometry of the silicone oil-filled eye. *Eye* 1999;13:319-24.
28. Shugar JK, de Juan E Jr, McCuen BW 2<sup>nd</sup>, Tiedeman J, Landers MR 3<sup>rd</sup>, Machemer R. Ultrasonic examination of the silicone-filled eye: Theoretical and practical considerations. *Graefes Arch Clin Exp Ophthalmol* 1986;224:361-7.
29. Murray DC, Durrani OM, Good P, Benson MT, Kirkby GR. Biometry of the silicone oil-filled eye: II. *Eye (Lond)* 2002;16:727-30.
30. Kanclerz P, Grzybowski A. Accuracy of intraocular lens power calculation in eyes filled with silicone oil. *Semin Ophthalmol* 2019;34:392-7.
31. Akman A, Asena L, Güngör SG. Evaluation and comparison of the new swept source OCT-based IOLMaster 700 with the IOLMaster 500. *Br J Ophthalmol* 2016;100:1201-5.
32. Tielsch JM, Legro MW, Cassard SD, Schein OD, Javitt JC, Singer AE, *et al.* Risk factors for retinal detachment after cataract surgery. A population-based case-control study. *Ophthalmology* 1996;103:1537-45.
33. Steinert RF, Puliafito CA, Kumar SR, Dudak SD, Patel S. Cystoid macular edema, retinal detachment and glaucoma after Nd:YAG posterior capsulotomy. *Am J Ophthalmol* 1991;112:373-80.
34. Jonas JB, Budde WM, Knorr HLJ. Timing of retinal detachment after removal of intraocular silicone oil tamponade. *Am J Ophthalmol* 1999;128:628-31.