

Case Series – General Neurology

Donepezil-Induced Complex Multimodal Hallucinations: Two Cases and a Review of the Literature

Federico Emanuele Pozzi^{a, b} Lucio Tremolizzo^{a, b} Carlo Ferrarese^{a, b}
Ildebrando Appollonio^{a, b}

^aDepartment of Neurology, San Gerardo Hospital, Monza, Italy; ^bSchool of Medicine and Surgery, University of Milano-Bicocca, Milan, Italy

Keywords

Donepezil · Hallucinations · Alzheimer's disease · Adverse events

Abstract

Hallucinations are common in neurodegenerative dementias, being present in a significant proportion of patients. Most of the available studies show that acetylcholinesterase inhibitors may be beneficial in preventing and treating hallucinations in patients with neurodegenerative and even psychiatric disorders, even though there are reports that they might also develop as an adverse effect of such therapy. However, a clear causal relationship for the latter association was not previously established. Here we describe 2 cases of patients treated with donepezil who developed complex multimodal hallucinations, which could be causally linked to the drug by means of a challenge-dechallenge (and rechallenge in one case) paradigm. We also provide a narrative review of the literature regarding donepezil and hallucinations and propose a hypothesis to explain the occurrence of this phenomenon.

© 2022 The Author(s).
Published by S. Karger AG, Basel

Introduction

Hallucinations are listed among the behavioral disorders associated with dementia, and they are thought to develop in up to 20% of patients suffering from Alzheimer's disease (AD) during the natural history of this condition [1]. Hallucinations are also a typical feature of dementia with Lewy body (DLB), and they are present in other types of neurodegenerative

dementias as well. Donepezil is an acetylcholinesterase inhibitor widely used in the mild-to-moderate phases of AD, DLB, and Parkinson's disease dementia, which seems to prevent and improve hallucinations and other neuropsychiatric features of dementias [2–7].

However, hallucinations are also reported as adverse events occurring with donepezil treatment, even though the prescribing information of Aricept (donepezil, reference ID: 4365411), revised in December 2018, states that there are inadequate data to establish a causal relationship between donepezil and hallucinations. Here we describe 2 cases of patients with neurodegenerative dementia experiencing the onset of hallucinations after the introduction of donepezil 5 mg QD and their disappearance with discontinuation of such drug, suggesting a causality relationship, whose nature is yet to be determined.

Case Reports

Case 1

The first patient was an 80-year-old male, complaining of progressive memory deficits in the last 2 years, with functional impairment. He had no parkinsonism and did not exhibit symptoms or signs compatible with DLB. Formal neuropsychological testing revealed a cognitive profile compatible with AD; his MMSE was 15/30, ADL was 4/6, and IADL was 1/8. A brain CT scan showed diffuse mild supratentorial atrophy and white matter changes. His history was notable for hypercholesterolemia and prostatic cancer currently on pharmacological treatment with anti-androgenic therapy, with no focal uptake on a recent total body FDG-PET. His ECG was unremarkable.

He was started on donepezil 5 mg QD, and soon after the introduction of the drug, he developed complex visual hallucinations in the evening, claiming to see several persons in his bedroom and asking them why they were there; such hallucinations were present for 7 days and abruptly ceased with donepezil withdrawal. He was then treated with memantine 20 mg QD, with no reported adverse events.

Case 2

The second patient was an 80-year-old female, with progressive linguistic and memory deficits over the course of the previous year. Her medical history was unremarkable and she was not on any systemic drug. Upon neurological examination, she had frequent anomia and paraphasia, attitudinal tremor with tendency toward micrographia, mild plastic right upper limb hypertonia, and mild dysdiadochokinesia. Brain MRI showed moderate diffuse cortical atrophy, more evident on anterolateral temporal, inferior-lateral frontal, and superior-lateral parietal convexities (shown in Fig. 1). Pseudo-continuous arterial spin labeling sequences showed a relative reduction of cerebral blood flow in the superior-lateral parietal lobe. Brain FDG-PET revealed moderate left precuneus and bilateral parietal and temporal hypometabolism (more evident in the left hemisphere), and milder left prefrontal and occipital hypometabolism, which seemed to be compatible with AD (shown in Fig. 2). Neuropsychological tests revealed a visuoconstructional deficit, right apraxia, mild semantic fluency and naming deficits, and a mild dysexecutive syndrome, together with mild anxiety, irritability, and depression; her MMSE was 16/30, ADL was 6/6, and IADL was 6/8, with a CDR-SB of 0.5. The clinical picture was judged consistent with a frontal behavioral-spatial syndrome phenotype with features of possible corticobasal syndrome (CBS; in particular, asymmetric limb rigidity and apraxia), according to established diagnostic criteria [8]. Although the preservation of posterior cingulum on FDG-PET (as shown in Fig. 2) may resemble the “cingulate island sign,” which has a specificity for DLB ranging from 75 to 100% across different studies [9], and even if the pattern of cognitive deficits may have pointed toward this diagnosis, she did not meet the core clinical

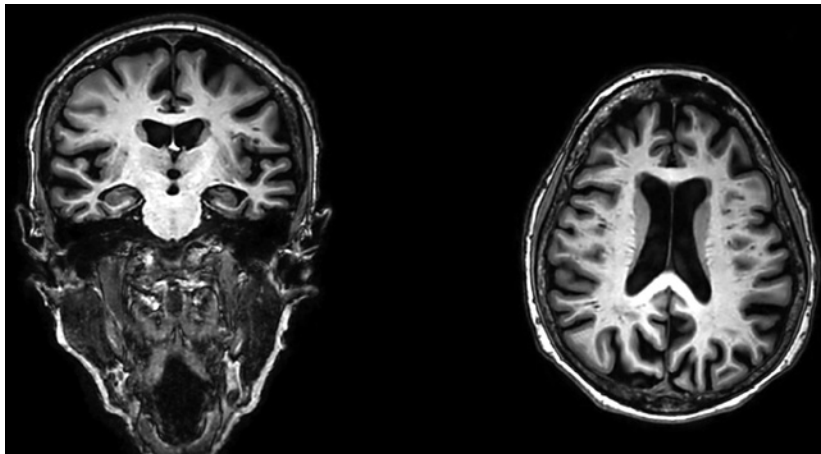


Fig. 1. Brain MRI of patient 2, showing diffuse atrophy, more evident on anterolateral temporal, inferior-lateral frontal, and superior-lateral parietal convexities.

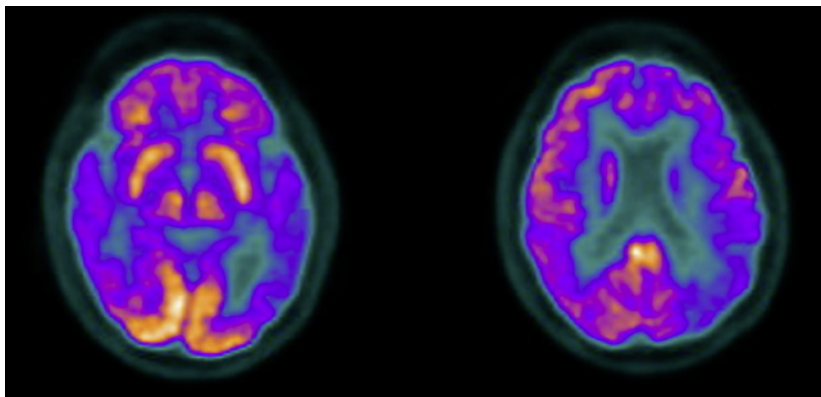


Fig. 2. Brain FDG-PET of patient 2, revealing moderate temporal and parietal hypometabolism.

features of the recently proposed criteria of MCI due to DLB (which do not include the cingulate island sign), while the striking lateralization of apraxia and rigidity was judged coherent with the CBS criteria [8, 10]. We performed a lumbar puncture, which revealed decreased amyloid- β 42 (337 pg/mL, normal values >599 pg/mL), and the normal total-tau, phospho-tau, amyloid- β 42/40 ratio, amyloid- β 42/phospho-tau ratio. Taken together, these findings suggested a possible corticobasal degeneration with coexistent amyloid pathology [8].

She was started on donepezil 5 mg QD but developed complex multimodal (visual and acoustic) hallucinations immediately afterward: she reported seeing a woman dressed in white, which she thought was an angel, who seemed to call her and with whom she interacted at times. She was also hearing undistinguishable voices and noises, and after walking around the house at night to look for the origin of such sounds, she would eventually go to bed and cover her head with the blankets attempting to avoid seeing and hearing. These visions typically happened in the evening and during the night, persisted when the donepezil dose was augmented to 10 mg QD, and immediately ceased after donepezil withdrawal. After 2 weeks, we performed a rechallenge and started again donepezil 5 mg QD, with the prompt reappearance of similar hallucinations, which stopped again after the interruption of the drug.

Discussion/Conclusion

To the best of our knowledge, there is only one previous study reporting donepezil-induced complex hallucinations, in which a 60-year-old man with probable AD developed hypnopompic visual hallucinations of insects, which did not worsen when the donepezil dose was augmented to 10 mg QD [1]. The authors noted that up to 20% of AD patients experience hallucinations, but it should be noticed that these figures were derived from papers written in the early 1990s, when DLB criteria were yet to be published [1, 11]. Moreover, hypnopompic hallucinations might be favored by donepezil-related sleep disturbances [1]. However, since donepezil is known to induce nightmares, it is possible that in past reports hallucinations might have been underreported and/or confused with nightmares.

Ali and colleagues [12] analyzed two pharmacovigilance databases from the USA and Canada, showing that hallucinations are present in around 3% of adverse events reports with acetylcholinesterase inhibitors, with less than 250 total reports; however, no further information about these data was provided in the text, and the same consideration made about causality may apply here. Another study by Winblad showed that hallucinations were more frequent in patients with severe AD treated with donepezil compared to placebo [13]. However, two considerations need to be made: first, there is currently no established indication for donepezil treatment in severe AD, in which hallucinations may be part of the natural history of the disease [1]. Second, out of 8 cases of hallucinations (128 patients on donepezil), only 4 were possibly treatment-related, while 3 were present before the start of the study [13]. Another study by the same authors on patients with mild-to-moderate AD treated with either donepezil continuously for 3 years or with 1 year placebo and 2 years donepezil showed that hallucinations were less present with donepezil during the first year (donepezil $n = 1$ vs. placebo $n = 3$) and more present with donepezil during the following 2 years (donepezil $n = 6$ vs. delayed-donepezil $n = 4$). However, drawing conclusions from these data is difficult, and no statistical comparison has been performed by the authors [14]. The previously cited study by Winblad is also the only study included in a Cochrane review by Birks, which reports an odds ratio of 4.68 for hallucinations with donepezil, but does not analyze the possible biases and confounding factors we pointed out [15].

Conversely, most studies report that donepezil (and acetylcholinesterase inhibitors in general) improves hallucinations in AD and DLB [2–7], and even in Charles-Bonnet visual and musical hallucinations [16, 17]. Other studies report that either donepezil ameliorates hallucinations in Parkinson's disease dementia [18], or there is at most no difference with respect to placebo [19]. Indeed, hallucinations might be related to a cholinergic deficit or dysfunction, which may explain the efficacy of this drug in their treatment [6, 7, 16].

It might be intriguing to notice that donepezil-induced hallucinations might be due to neurodegenerative diseases other than AD; therefore, it is of great importance to obtain a biomarker-based diagnosis for correct treatment. In our second case, PET, MRI, and NPS tests might have classified the case as a CBS due to AD, but some concerns about the underlying pathology exist. According to the established criteria, the clinical picture was consistent with corticobasal degeneration [8], while the role of the underlying AD pathology is debatable, depending on the definition of AD.

There are at least three different approaches to define AD according to CSF biomarkers: the first one emphasizes the superiority of the amyloid- β -42/phospho-tau ratio [20], while the recommendations of the Alzheimer's Biomarker Standardization Initiative (ABSI) and biomarkers for AD and Parkinson's disease (BIOMARKAPD) define AD as a combination of a reduced amyloid- β 42 and increased phospho-tau and total-tau (all other cases are defined as "non-AD") [21, 22]. According to these approaches, our case would have not been definitely classified as AD, but at most as an intermediate likelihood of AD pathology [21]. The approach proposed by the NIA-AA Research Framework would instead classify the case as "Alzheimer's and suspected

non-Alzheimer's pathologic change", due to the presence of an amyloid (A) pathology biomarker, normal tau (T) pathology biomarker, and positive neurodegeneration (N) biomarkers [23].

A recent work by Constantinides shows that these biomarker-based interpretation difficulties are indeed quite common in CBD patients. The authors found that the ATN criteria classified 50% of "probable CBD" patients as AD; however, from neuropathological studies, it seems that the application of ABSI/BIOMARKAPD and the amyloid- β 42/phospho-tau ratio criteria, which tend to exclude AD in our case, might be more accurate [24]. Moreover, donepezil should not be prescribed for patients with suspected CBS, as the pathology of this syndrome is not based on loss of cholinergic neurons, like AD and DLB, and there have been no clinical trials on CBS patients to show that donepezil is either safe or effective for them.

In conclusion, our cases are the only ones that seem to prove a causal relationship between donepezil and complex multimodal hallucinations, as we performed a challenge-dechallenge and a challenge-dechallenge-rechallenge paradigm in the first and second cases, respectively. The implications of this association might open the possibility that either the cholinergic deficit is not the only determinant of hallucinations, or that there was not a significant cholinergic dysfunction in our cases (if AD pathology was indeed not present). This latter hypothesis might be similar to the one provided by Richter in a study on the effect of rivastigmine in AD patients and healthy controls, which reports that the response to cholinergic stimulation might depend on the integrity of the cholinergic system in analogy to the Yerkes-Dodson law [25]: namely, in patients with preserved cholinergic function, the effect of adding acetylcholine would be an increase in arousal, resulting in poorer cognitive performances and, as in our cases, development of hallucinations. However, further studies are warranted to confirm these findings and establish a biological explanation for this phenomenon.

Statement of Ethics

The research was conducted in accordance with the World Medical Association Declaration of Helsinki. The two subjects involved and the patients' next of kin gave written informed consent to publish the details of their medical cases (including publication of images). No information revealing the subjects' identity was included in the text. This retrospective review of patient data did not require ethical approval in accordance with local guidelines.

Conflict of Interest Statement

The authors have no conflicts of interest to declare.

Funding Sources

No funding was received for the current work.

Author Contributions

Patients were clinically managed by Federico Emanuele Pozzi and Lucio Tremolizzo. The manuscript was drafted by Federico Emanuele Pozzi and critically revised, commented upon and approved by Lucio Tremolizzo, Carlo Ferrarese, and Ildebrando Appollonio before its final submission.

Data Availability Statement

All data generated or analyzed during this study are included in this article. Further inquiries can be directed to the corresponding author.

References

- 1 Yorston GA, Gray R. Hypnopompic hallucinations with donepezil. *J Psychopharmacol*. 2000;14(3):303–4.
- 2 Bergman J, Brettholz I, Shneidman M, Lerner V. Donepezil as add-on treatment of psychotic symptoms in patients with dementia of the Alzheimer's type. *Clin Neuropharmacol*. 2003;26(2):88–92.
- 3 Tanaka T, Kazui H, Morihara T, Sadik G, Kudo T, Takeda M. Post-marketing survey of donepezil hydrochloride in Japanese patients with Alzheimer's disease with behavioral and psychological symptoms of dementia (BPSD). *Psychogeriatrics*. 2008;8(3):114–23.
- 4 Cummings J, Lai TJ, Hemrungronj S, Mohandas E, Yun Kim S, Nair G, et al. Role of Donepezil in the management of neuropsychiatric symptoms in Alzheimer's disease and dementia with Lewy bodies. *CNS Neurosci Ther*. 2016;22(3):159–66.
- 5 Mori T, Ikeda M, Fukuhara R, Nestor PJ, Tanabe H. Correlation of visual hallucinations with occipital rCBF changes by donepezil in DLB. *Neurology*. 2006;66(6):935–7.
- 6 Satoh M, Ishikawa H, Meguro K, Kasuya M, Ishii H, Yamaguchi S. Improved visual hallucination by donepezil and occipital glucose metabolism in dementia with lewy bodies: the Osaki-Tajiri project. *Eur Neurol*. 2010;64(6):337–44.
- 7 Wynn JZ, Cummings JL. Cholinesterase inhibitor therapies and neuropsychiatric manifestations of Alzheimer's disease. *Dement Geriatr Cogn Disord*. 2004;17(1–2):100–8.
- 8 Bak TH, Bhatia KP, Borroni B, Armstrong MJ, Litvan I, Lang AE, et al. Criteria for the diagnosis of corticobasal degeneration. *Neurology*. 2013;80(5):496–503.
- 9 Chiba Y, Fujishiro H, Iseki E, Kasanuki K, Sato K. The cingulate Island sign on FDG-PET versus IMP-SPECT to assess mild cognitive impairment in Alzheimer's disease versus dementia with Lewy bodies. *J Neuroimaging*. 2019;29(6):712–20.
- 10 McKeith IG, Ferman TJ, Thomas AJ, Blanc F, Boeve BF, Fujishiro H, et al. Research criteria for the diagnosis of prodromal dementia with Lewy bodies. *Neurology*. 2020;94(17):743–55.
- 11 Mueller C, Ballard C, Corbett A, Aarsland D. Historical landmarks in dementia with Lewy bodies. *Lancet Neurol*. 2017;16(5):348.
- 12 Ali TB, Schleret TR, Reilly BM, Chen WY, Abagyan R. Adverse effects of cholinesterase inhibitors in dementia, according to the pharmacovigilance databases of the United-States and Canada. *PLoS One*. 2015;10(12):e0144337–10.
- 13 Winblad B, Kilander L, Eriksson S, Minthon L, Båtsman S, Wetterholm AL, et al. Donepezil in patients with severe Alzheimer's disease: double-blind, parallel-group, placebo-controlled study. *Lancet*. 2006;367(9516):1057–65.
- 14 Winblad B, Wimo A, Engedal K, Soininen H, Verhey F, Waldemar G, et al. 3-year study of donepezil therapy in Alzheimer's disease: effects of early and continuous therapy. *Dement Geriatr Cogn Disord*. 2006;21(5–6):353–63.
- 15 Birks JS, Harvey RJ. Donepezil for dementia due to Alzheimer's disease. *Cochrane Database Syst Rev*. 2018;6:CD001190.
- 16 Ukai S, Yamamoto M, Tanaka M, Takeda M. Treatment of typical Charles Bonnet syndrome with donepezil. *Int Clin Psychopharmacol*. 2004 Nov;19(6):355–7.
- 17 Blom JD, Coebergh JAF, Lauw R, Sommer IEC. Musical hallucinations treated with acetylcholinesterase inhibitors. *Front Psychiatry*. 2015 Apr 7;6:46–6.
- 18 Fabbri G, Barbanti P, Aurilia C, Pauletti C, Lenzi GL, Meco G. Donepezil in the treatment of hallucinations and delusions in Parkinson's disease. *Neurol Sci*. 2002 Apr;23(1):41–3.
- 19 Sawada H, Oeda T, Kohsaka M, Umemura A, Tomita S, Park K, et al. Early use of donepezil against psychosis and cognitive decline in Parkinson's disease: a randomised controlled trial for 2 years. *J Neurol Neurosurg Psychiatry*. 2018;89(12):1332–40.
- 20 De Souza LC, Lamari F, Belliard S, Jardel C, Houillier C, De Paz R, et al. Cerebrospinal fluid biomarkers in the differential diagnosis of Alzheimer's disease from other cortical dementias. *J Neurol Neurosurg Psychiatry*. 2011;82(3):240–6.
- 21 Molinuevo JL, Blennow K, Dubois B, Engelborghs S, Lewczuk P, Perret-Liaudet A, et al. The clinical use of cerebrospinal fluid biomarker testing for Alzheimer's disease diagnosis : a consensus paper from the Alzheimer's biomarkers standardization initiative. *Alzheimers Dement*. 2014;10(6):808–17.
- 22 Simonsen AH, Herukka SK, Andreasen N, Baldeiras I, Bjerke M, Blennow K, et al. Recommendations for CSF AD biomarkers in the diagnostic evaluation of dementia. *Alzheimers Dement*. 2017;13(3):274–84.
- 23 Jack CR, Bennett DA, Blennow K, Carrillo MC, Dunn B, Haeberlein SB, et al. NIA-AA research framework: toward a biological definition of Alzheimer's disease. *Alzheimers Dement*. 2018;14(4):535–62.

- 24 Constantinides VC, Paraskevas GP, Boufidou F, Bourbouli M, Stefanis L, Kapaki E. Cerebrospinal fluid biomarker profiling in corticobasal degeneration: application of the AT (N) and other classification systems. [Park Relat Disord](#). 2021 Jan;82:44–9.
- 25 Richter N, Beckers N, Onur OA, Dietlein M, Tittgemeyer M, Kracht L, et al. Effect of cholinergic treatment depends on cholinergic integrity in early Alzheimer’s disease. [Brain](#). 2018;141(3):903–15.