

The correlation between medial plica and trochlear dysplasia: An MRI study

Elif E Ekin, Hülya K Yıldız, Harun Mutlu¹, Engin Çetinkaya²

Departments of Radiology, ¹Orthopaedics and Traumatology, GOP Taksim Training and Research Hospital, İstanbul, ²Department Orthopaedics and Traumatology, Baltalimanı Education and Research Hospital, İstanbul, Turkey

Correspondence: Dr. Elif E Ekin, Department of Radiology, GOP Taksim Training and Research Hospital, İstanbul, Turkey.
E-mail: eeeoner@gmail.com

Abstract

Background: Trochlear dysplasia is the most commonly encountered congenital etiologic factor of anterior knee pain. **Aims:** The purpose of this study was to evaluate the relationship between trochlear dysplasia with medial patellar plica as well as to investigate the distribution of plica types according to types of dysplasia. **Settings and Design:** This is a retrospective case-control study. **Materials and Methods:** This study was conducted among 138 knee magnetic resonance imaging (MRI) scans. The presence of medial plica and its types were compared among 69 patients in whom trochlear dysplasia had been detected and 69 individuals with normal trochlear who were of the same age and gender as the patient group. **Statistical Analysis:** Trochlear dysplasia and medial plica was compared by Chi-square with Yates correction and Fisher's exact probability tests ($P < 0.001$). The data were presented as mean, standard deviation, minimum–maximum, frequency, and percentage. **Results:** Of all the patients ($n = 138$), the number of patients in whom plica was observed was $n = 104$ (75.3%), and the distribution of plica type was as follows: $n = 70$ (67.3%) Type 1, $n = 25$ (24%) Type 2, and $n = 9$ (8.6%) Type 3. Medial plica was more frequently observed in patients with trochlear dysplasia ($P < 0.001$). Type 2 and Type 3 medial plica were more frequently encountered in trochlear dysplasia ($P < 0.001$). Type 3 plica was not seen in patients with normal trochlea. **Conclusion:** Medial patellar plica is more frequently seen in trochlear dysplasia. As the type of trochlear dysplasia progresses, the prevalence of thicker and shelf-shaped plica increases.

Key words: Knee; medial plica; trochlear dysplasia

Introduction

Bone structures of the knee joint develop at the eight week of embryonal life. Synovial membranes that divide the knee into three compartments are resorbed after the 16th week of pregnancy, and a simple, single cavity is formed. According to the widespread opinion, synovial plica is the partially resorbed embryonal residue of these membranes. There are mainly three types of plicae, namely, suprapatellar plica, mediopatellar plica, and infrapatellar plica.^[1] Cases of lateral synovial plica have also been reported;^[2] however, it is not yet certain whether it is a genuine septal residue

or not. Being the most frequent cause of clinical signs, the prevalence of medial plica has been reported to be 47–50% in cadaveric studies.^[3] In arthroscopic studies, its prevalence has been reported between 18% and 80% in various studies and different results have been presented.^[4,5] Medial plica starts from the suprapatellar plica or medial joint wall, the oblique moves along the wall, and ends on the level of the infrapatellar fat pad.^[6] Plica has a flexible structure, glide on the femur condyles, and are generally asymptomatic. However, after inflammations, that frequently occur due to trauma, the elasticity of the thickened plica degenerates,

Access this article online

Quick Response Code:



Website:
www.ijri.org

DOI:
10.4103/0971-3026.195774

This is an open access article distributed under the terms of the Creative Commons Attribution-NonCommercial-ShareAlike 3.0 License, which allows others to remix, tweak, and build upon the work non-commercially, as long as the author is credited and the new creations are licensed under the identical terms.

For reprints contact: reprints@medknow.com

Cite this article as: Ekin EE, Yıldız HK, Mutlu H, Çetinkaya E. The correlation between medial plica and trochlear dysplasia: An MRI study. Indian J Radiol Imaging 2016;26:455-9.

and it may induce cartilage damage in progressive cases. Apart from trauma, chronic effusions can also cause the plica to thicken. Plica syndrome is generally found in youths and is more frequently encountered in females.^[6] Typically, history of anterior knee pain developing after a blunt trauma on the knee and effusion are present. The pain is intermittent, manifests with activity, and wears off with rest. In the diagnosis of medial plica, the sensitivity of dynamic ultrasonography (US) and magnetic resonance imaging (MRI) is quite high (90% and 95%, respectively); whereas the gold standard is arthroscopic evaluation.^[1] In their study, Stubbings and Smith determined the sensitivity of medial plica physical test and US for detecting the medial plica to be 90%.^[7]

There are many studies in the literature regarding the frequency and importance of medial plica in the etiology of anterior knee pain.^[4,6,8] Another significant factor in anterior knee pain is trochlear dysplasia. Similar to medial plica, which is accepted as an embryologic residue, trochlear dysplasia is also of congenital origin.^[9] Our hypothesis at the beginning of the study was whether or not there was a correlation between medial plica and trochlear dysplasia, one of the congenital factors frequently encountered in anterior knee pain, medial plica frequency, and the distribution of plica types were investigated in patients with and without trochlear dysplasia.

Materials and Methods

Patients selection

This is a case-control study. The study sample consisted patients over the age of 18, who had presented to our hospital for knee pain. After having obtained the approval of the ethics committee, power analysis was performed, and it was determined that 63 patients with trochlear dysplasia and 63 control individuals with normal trochlear groove needed to be included in the study because when first type error was 0.05, second type error was 0.2, and the general prevalence of plica was 80%, it was anticipated that a 20% difference between the two groups would be significant. Knee MRI scans performed in our department between January 2015 and March 2015 were retrospectively evaluated. First, 69 consecutive patients with trochlear dysplasia (Group 1) were selected. The control group (Group 2) consisted of 69 patients with normal trochlear groove who were of the same age and gender. Patients with Anterior cruciate ligament (ACL) rupture, femur fracture, previous knee surgeries, and widespread artefact were excluded from the study because these conditions could affect the measurements. A total of 138 knee MRI scans were examined.

Magnetic resonance imaging techniques

The 1.5 T MR unit (Signa HDxt; GE, USA) and extremity coil was used. (TR range/TE range 4000/40; matrix size,

256 × 256; field of view, 16 cm; slice thickness 4 mm, NEX 2). Sagittal proton density-weighted, fast spin-echo, and fat-suppressed sequences were used to determine measurements on sagittal, coronal, and axial images.

Evaluation of the images

The evaluation of medial plica

In 2013, Hayashi *et al.*^[8] adapted the medial plica classification for MRI, which was based on the arthroscopic classification of Sakakibara:^[10]

- Type 0: No detection of medial plica,
- Type 1: Cord-shaped thickening of the synovial wall, concordant with Sakakibara Type A,
- Type 2: Shelf-like plica that does not cover the anteromedial trochlear surface concordant with Sakakibara Type B,
- Type 3: Thick, shelf-like plica covering the anteromedial trochlear surface concordant with Sakakibara Type C and Type D. The basic difference between the plicae classified as Sakakibara Type C and D in arthroscopy is the additionally detected fenestration in Type D, which cannot be differentiated on MRI.

Sulcus angle and trochlear typing

Axial images passing 3 cm above the knee joint distance were used. Sulcus angle was measured at the anterior trochlear surface between the highest lateral edge, the deepest sulcus point, and the highest medial edge. Normal trochlear angle was set as $137 \pm 8^\circ$.

Dejour classification^[11] was used for the classification of trochlear dysplasia as follows:

- Type A: Sulcus angle $>145^\circ$ but with a normal shape.
- Type B: Flattened trochlear surface and a supratrochlear spur.
- Type C: Asymmetric trochlear surface; hypoplastic medial facet; and convex lateral facet.
- Type D: A hump in shape; asymmetric trochlear surface with a supratrochlear spur.

All images were jointly evaluated by two radiologists experienced in the musculoskeletal system.

Statistical analysis

Normality test was conducted using the one-sample Kolmogorov–Smirnov test, histogram, box-plot, and by drawing Q–Q graphs. The data were presented as mean, standard deviation, minimum–maximum, frequency, and percentage. In the comparison of the two groups, age variable was compared with independent samples *t*-test. Nominal variable was compared by Chi-square with Yates correction and Fisher's exact probability tests. $P < 0.05$ was considered statistically significant. NCSS (10 <http://vassarstats.net/fisher2x4.html>) was used for analysis.

Results

According to the study conducted on a total of 138 patients, of whom 69 had trochlear dysplasia and the other 69 had normal trochlear. Mean age for the group with trochlear dysplasia was 37.01 ± 10.65 years (minimum: 18, maximum: 65). Mean age for the group with normal trochlear groove was 39.36 ± 10.68 years (minimum: 19, maximum: 62). In the evaluation in terms of age, there was no statistical difference between the two groups ($P = 0.198$).

A statistical difference was not detected in terms of gender between the two groups ($P = 0.865$). Among all the patients ($n = 138$), the number of patients in whom plica was observed was $n = 104$ (75.3%), and the distribution of plica type was as follows: $n = 70$ (67.3%) Type 1, $n = 25$ (24%) Type 2, and $n = 9$ (8.6%) Type 3.

The distribution of dysplasia types in 69 patients with trochlear dysplasia was as follows: $n = 15$ (21.7%) type A, $n = 26$ (37.6%) type B, $n = 27$ (39.1%) type C, and $n = 1$ (1.4%) type D.

While medial plica was not observed in 29 (42%) patients [Figure 1], Type 1 was detected in 35 (50.7%), type 2 in

5 (7.2%) [Figure 1], and type 3 plica was not detected among the 69 patients with normal trochlear groove.

The prevalence of medial plica among patients with trochlear dysplasia and those with normal trochlear was different ($P < 0.001$). Medial plica was more frequently seen in the group with trochlear dysplasia ($P < 0.001$) [Table 1].

Distribution of medial plica in trochlear dysplasia ($n = 69$) was as follows: 35 (50.7%) Type 1 plica, 20 (29%) type 2 plica, and 9 (13%) type 3 plica. Type 1 medial plica was observed in equal numbers in the control and dysplastic group. There was no difference in prevalence in type 1 plica between the groups with and without trochlear dysplasia [Table 1; Figure 1]. Type 2 and type 3 medial plica were more frequently observed in trochlear dysplasia ($P < 0.001$) [Table 1]. Type 2 plica was seen in 20 patients, and its distribution regarding trochlear dysplasia was as follows: 9 in type C, 6 in type B, and 5 in type A [Figures 2 and 3]. Type 3 plica was seen in 9 patients and its distribution regarding trochlear dysplasia was as follows: 4 in type B, 4 in type C, and 1 in type D [Figure 4A and B]. Importantly, type 3 plica was not detected in patients with normal trochlear groove.

Fourteen patients, in whom medial plica was detected, were also arthroscopically evaluated. Our patients, of whom 5 were determined as type 3 and 9 as type 2 in MRI, were confirmed by arthroscopy [Figure 4C].

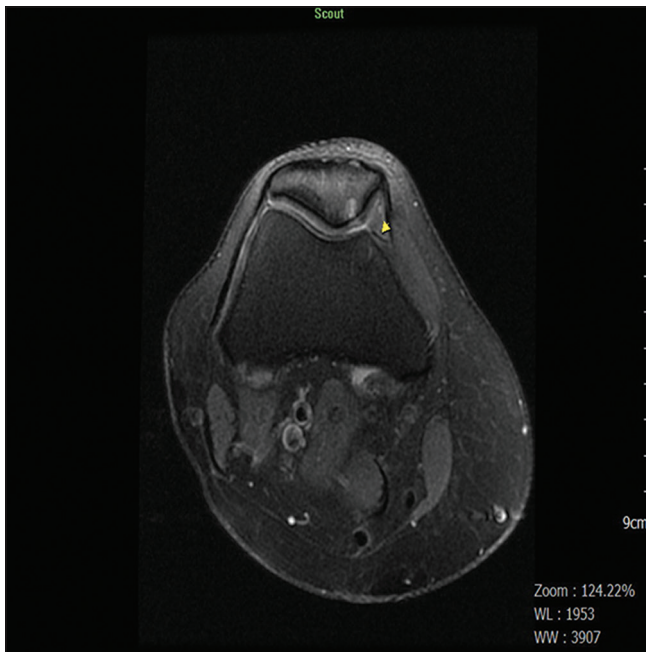


Figure 1: On the fat suppressed T2WI axial sections passing from the center of the patella; Type 1 medial plica (arrow head) is seen in Type A trochlear dysplasia. Moreover, focal thinning chondromalacia is observed in the patella medial cartilage

Discussion

The difference in the rates of medial plica detection in various studies is striking. Nakayama *et al.*^[12] arthroscopically detected 79.9% medial plicae in 3889 knees and defined these as 35.2% type A, 22.4% type B, 12.3% type C, and 10% type D plicae according to the Sakakibra classification. Hayashi *et al.*^[8] detected 47.7% medial plicae in 342 knees with MRI, and the types of plicae were as follows: 46.6% type A, 42.3% type B, and 11% type C. Lyu *et al.*^[13] have detected 29.7% medial plicae in 1587 knees, and Christoforakis *et al.*^[14] detected 32.1% medial plicae in 1000 knees. When all patients were considered in our study, the detection rate of medial plica was 75.3%, which was close to the arthroscopic studies of Nakayama *et al.*^[12] There was a high incidence of type 1 plica, and most frequently type 1 and least frequently type 3 were observed, which is similarly to these studies. The different rates in the frequency of medial plica in the literature are explained by the fact that, while

Table 1: The prevalence of medial plica in patients with normal trochlea and in patients with trochlear dysplasia and the distribution of plica types

| | Plica (-) | Plica (+) | P | Plica Type 1 | Plica Type 2 | Plica Type 3 |
|----------------------------------|------------------|-------------------|-----------|------------------|------------------|----------------|
| Control Group ($n = 69$) | $n = 29$ (42%) | $n = 40$ (58%) | | $n = 35$ (50.7%) | $n = 5$ (7.2%) | $n = 0$ (0%) |
| Trochlear Dysplasia ($n = 69$) | $n = 5$ (7.2%) | $n = 64$ (92.7%) | < 0.001 | $n = 35$ (50.7%) | $n = 20$ (29%) | $n = 9$ (13%) |
| Total ($n = 138$) | $n = 34$ (24.6%) | $n = 104$ (75.3%) | | $n = 70$ (50.7%) | $n = 25$ (18.1%) | $n = 9$ (6.5%) |

some researchers consider small residues of synovium as plicae, some do not.^[15] Hayashi *et al.* have stated that the differences in study populations were important.^[8] Kang *et al.*^[16] indicated the correlation of the presence of abnormal geometry and/or medial plica in the patellofemoral joint with anterior knee pain in a study conducted among young male soldiers with atraumatic anterior knee pain. In addition to the results of Kang *et al.*, it was evident in our study that the ratio of trochlear dysplasia affected the prevalence of medial plica. When trochlear dysplasia was taken into consideration, the prevalence of medial plica was found to be statistically high in the group with dysplasia. It can

be considered that the prevalence of medial plica is higher in societies where the prevalence of trochlear dysplasia is high. Again, it is striking that thicker, shelf-shaped plicae are more frequently seen in trochlear dysplasia. Type 1 plica was detected at the same frequency in normal and dysplastic trochlea. Together with being observed in both the groups, Type 2 plica was more prevalent in the dysplastic group. Type 3 plica was only observed in the group with trochlear dysplasia, and type B, type C, and type D were seen among patients with trochlear dysplasia. Type 2 plica was detected only in 5 of the patients with normal trochlea ($n = 40$), in whom plica was observed, and type 1 was detected in the

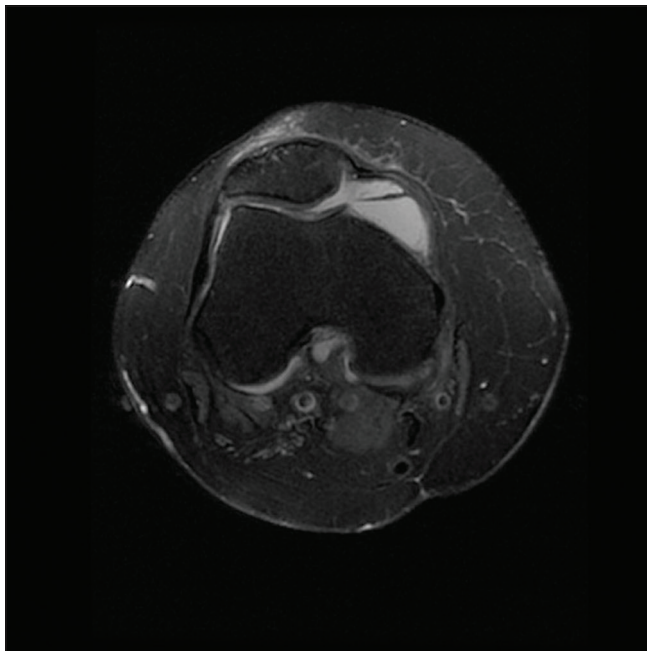


Figure 2: On the fat suppressed T2WI axial sections passing from the center of the patella; thick, shelf-shaped Type 2 medial plica is seen in the knee with Type B trochlear dysplasia. The increase in suprapatellar fluid raises the visibility of the plica

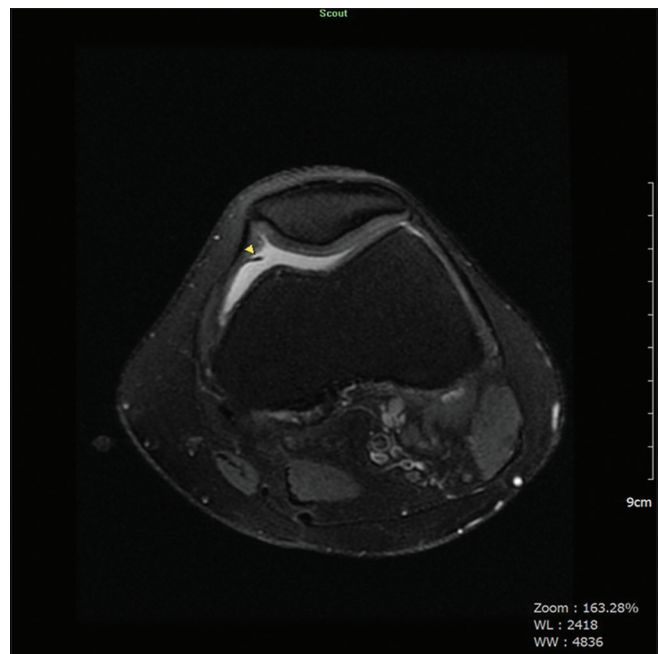


Figure 3: On the fat suppressed T2WI axial sections passing from the center of the patella; thick, shelf-shaped Type 2 medial plica is seen on the knee with Type C trochlear dysplasia (arrow head)

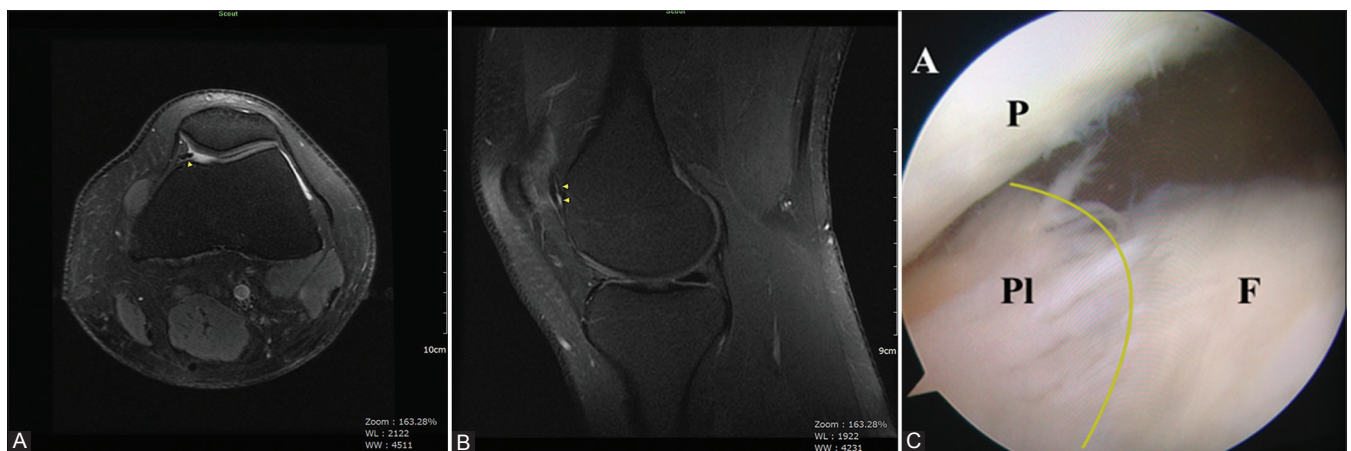

Figure 4 (A-C): On the fat suppressed T2WI axial sections passing from the center of the patella; (A) thick, shelf-shaped Type 3 medial plica covering the medial trochlear surface is seen in the knee with Type C trochlear dysplasia (arrow head). (B) The extension of Type 3 plica on the fat suppressed T2WI sagittal plan (arrow head). (C) In arthroscopy, thick, fringed, and shelf-shaped Type 3 medial plica partially covering the femur medial condyle was seen in line with the MRI

rest. Type 2 and type 3 plicae were detected in 29 of the patients with trochlear dysplasia ($n = 64$), in whom plica was seen. Medial plica in the shape of thick-shelf, which are the most commonly responsible agents of clinical symptoms, are more frequently seen in trochlear dysplasia. Moreover, thick, shelf-shaped medial plicae are more frequent in advanced trochlear dysplasia.

One of the limitations of our study was that the prevalence of plica would be affected in our study which included all patients with knee pain, reducing the power of the study. Unfortunately, it was not possible to describe the relationship between anterior knee pain and medial plica in this retrospective study.

The presence of medial plica and its types were evaluated by MRI and not all patients' arthroscopic correlations were made. However, there are studies in the literature indicating that the sensitivity of MRI is quite high in detecting medial plica.^[1] We are of the opinion that plica diagnosis is reliable using MRI.

Conclusion

Medial plica frequently accompanies trochlear dysplasia, and a detailed evaluation in terms of medial plica is necessary in patients with trochlear dysplasia. As the type of trochlear dysplasia advances, the prevalence of thicker and shelf-shaped plica also increases.

Acknowledgment

We thank Dr. Sevim Purisa for statistical evaluation.

Financial support and sponsorship

Nil.

Conflicts of interest

There are no conflicts of interest.

References

1. Al-Hadithy N, Gikas P, Mahapatra AM, Dowd G. Plica syndrome of the knee. *J Orthop Surg* 2011;19:354-8.
2. Tearse DS, Clancy WG, Gersoff WK. The symptomatic lateral synovial plica of the knee. 7th ed. Annual Meeting of Arthroscopy association of North America. Washington DC; 1988.
3. Dinesh P. Plica as a cause of anterior knee pain. *Orthop Clin North Am* 1986;17:273-9.
4. Ege G, Akman H, Ertem E. Medial patellar plica syndrome. *Turk J Diagn Intervent Radiol* 2002;8:93-6.
5. Dupont JY. Synovial plicae of the knee. *Clin Sports Med* 1997;16:87-122.
6. Pinar H. Plica Syndrome: A cause of anterior knee pain. *Acta Orthop Traum Turc* 1988;22:268-71.
7. Stubbings N, Smith T. Diagnostic test accuracy of clinical and radiological assessments for medial patella plica syndrome: A systematic review and meta-analysis. *Knee* 2014;21:486-90.
8. Hayashi D, Xu L, Guermazi A, Kwok CK, Hannon MJ, Jarraya M, *et al.* Prevalence of MRI-detected mediopatellar plica in subjects with knee pain and the association with MRI-detected patellofemoral cartilage damage and bone marrow lesions: Data from the joints on Glucosamine study. *BMC Musculoskeletal Disord* 2013;14:292-302.
9. Glard Y, Jouve JL, Garron E, Adalian P, Tardieu C, Bollini G. Anatomic study of femoral patellar Groove in fetüs. *J Pediatr Orthop* 2005;25:305-8.
10. Sakakibara J. Arthroscopic study on lino'sband (plica synovial is medio patellaris) *J Jpn Orthop Ass* 1976;50:513-22.
11. Dejour D, Le Coultre B. Osteotomies in patello-femoral instabilities. *Sports Med Arthrosc* 2007;15:39-46.
12. Nakayama A, Sugita T, Alzawa T, Takahashi A, Honma T. Incidence of medial plica in 3889 knee joints in the Japanese population. *Arthroscopy* 2011;27:1523-7.
13. Lyu SR, Hsu CC. Medial plica and degeneration of the medial femoral condyle. *Arthroscopy* 2006;22:17-26.
14. Christoforakis JJ, Sanchez Ballester J, Hunt N, Thomas R, Strachan RK. Synovial shelves of the knee: Association with chondral lesions. *Knee Surg Sports Traumatol Arthrosc* 2006;14:1292-8.
15. Dandy DJ. Anatomy of the medial suprapatellar plica and medial synovial shelf. *Arthroscopy* 1990;6:79-85.
16. Kang S, Park J, Kang SB, Chang CB. MRI findings of young male soldiers with atraumatic anterior knee pain. *Scand J Med Sci Sports* 2016;26:572-8.