



Contents lists available at ScienceDirect

## International Journal of Surgery Case Reports

journal homepage: [www.casereports.com](http://www.casereports.com)

# Successful primary staple-repair of thoracic oesophagus after delayed presentation of a spontaneous perforation



Giacomo Leoncini, Luca Novello, Andrea Denegri, Lucia Morelli\*, Giovanni B. Ratto

IRCCS San Martino University Hospital—IST National Institute for Cancer Research Unit of Thoracic Surgery, Genoa, Italy

## ARTICLE INFO

### Article history:

Received 15 July 2015

Received in revised form 27 July 2015

Accepted 28 July 2015

Available online 31 July 2015

### Keywords:

Boerhaave's syndrome

Primary repair

Stapler

## ABSTRACT

**INTRODUCTION:** Spontaneous perforation of the oesophagus is diagnosed late in over 50% of cases. Misdiagnosis may be due to atypical presentations. Primary repair is technically demanding in this setting and the risk of failure is high.

**PRESENTATION OF CASE:** An 85 year-old lady presented with an atypical cohort of mild nonspecific symptoms in spite of a pleuro-mediastinal purulent collection secondary to an undiagnosed spontaneous perforation of the oesophagus occurred seven days before. Despite the extent of perforation (3 cm in length), the late diagnosis and the necrosis of the muscular wall, the oesophagus was successfully repaired by means of a stapler.

**DISCUSSION:** The mechanism of the atypical presentation is discussed and possible modalities of treatment of delayed oesophageal perforations are reviewed, with particular reference to primary repair and to the possible use of staplers within this setting.

**CONCLUSION:** Even large spontaneous perforations of the oesophagus can result in a contained abscess, with no frank sepsis. Diagnosis can be missed for days in these cases. The attempt at primary repair of the oesophagus is still indicated. The use of a stapler is preferable in such cases as a perfect mucosal approximation is provided with minimal manipulation and with the use of inert, well tolerated material, which does not tend to become infected.

© 2015 The Authors. Published by Elsevier Ltd. on behalf of Surgical Associates Ltd. This is an open access article under the CC BY-NC-ND license (<http://creativecommons.org/licenses/by-nc-nd/4.0/>).

## 1. Introduction

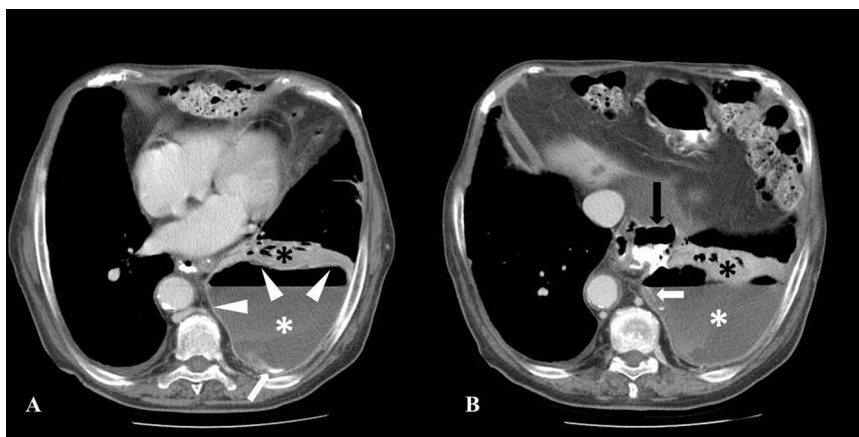
Spontaneous perforations of the thoracic oesophagus are diagnosed late in over 50% of cases [1–4]. Different modalities of treatment have been reported [2–4]. The attempt at primary repairing regardless of the interval between the injury and the operation is currently advised [1–4]. However, such procedure may be technically demanding and it is at risk of failure in case of very late diagnosis [1,5]. We report the case of a spontaneous perforation diagnosed seven days after an episode of vomiting. In spite of a large perforation with pleural empyema, purulent mediastinitis and extended necrosis of the muscular wall of the oesophagus, a successful repair was achieved by means of the mechanical suture of the oesophageal mucosa.

## 2. Presentation of case

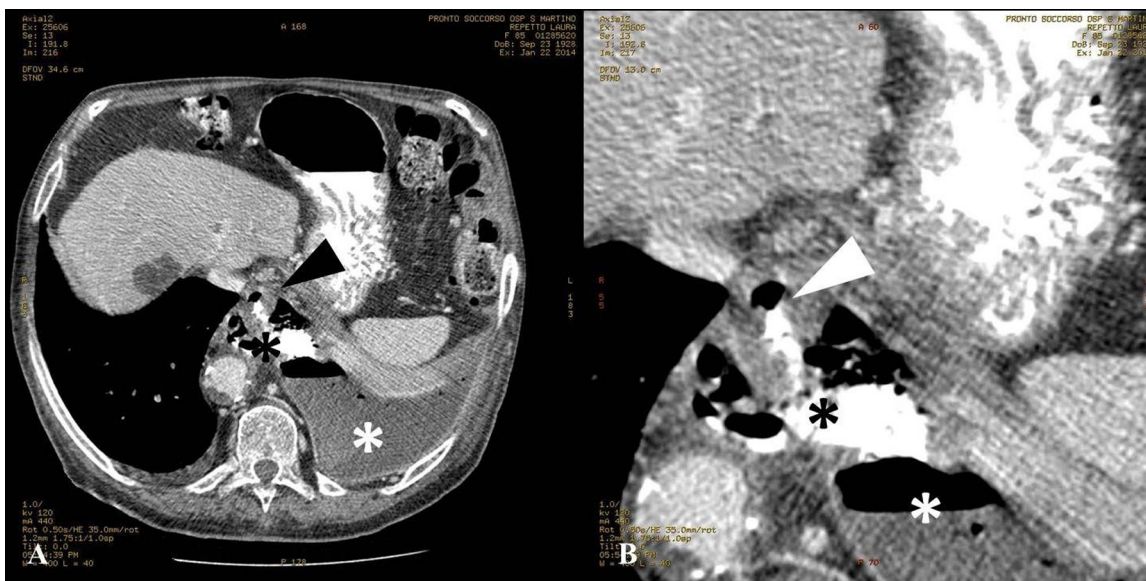A 85 year old lady was observed as she was suffering from a seven days lasting discomfort with moderate fever. As her clinical conditions progressively deteriorated, she had been referred to the emergency department of another hospital. A CT scan showed a lower para-oesophageal pleuro-mediastinal collection filled with fluid and air. As the wall of the oesophagus was thickened, the patient was diagnosed with perforated oesophageal cancer. She was then advised with no treatment except for palliation of symptoms. The patient was then referred to the emergency department of our hospital by the family. On admission, she was conscious, normal breathing and moderately febrile. Blood pressure and heart rate were normal. The white blood cell count and C-reactive protein were 11.100 cells/ $\mu$ L and 243 mg/L, respectively. Biochemical signs of liver and renal impairment were minimal. Accurate anamnesis revealed an episode of vomiting occurred seven days before. Since then, the patient had fever and malaise, but she continued to feed orally. CT scan showed the oral contrast to spread into a para-oesophageal mediastinal and left pleural collection (Figs. 1 and 2). A left thoracotomy was performed. A smelly purulent collection was wide opened and debrided. The lower lobe of the lung appeared to be trapped. Necrotic tissues were removed. The distal third of the oesophagus was isolated down to the hiatus. A perforation of

\* Corresponding author at: Unit of Thoracic Surgery, IRCCS San Martino University Hospital, IST National Institute for Cancer Research, L.go R.Benzi, 10, 16132 Genoa, Italy. Fax: +39 105556662.

E-mail addresses: [giacomo.leoncini@hsanmartino.it](mailto:giacomo.leoncini@hsanmartino.it) (G. Leoncini), [luca.novello@gmail.com](mailto:luca.novello@gmail.com) (L. Novello), [andrea.denegri68@gmail.com](mailto:andrea.denegri68@gmail.com) (A. Denegri), [luca.morelli@gmail.com](mailto:luca.morelli@gmail.com) (L. Morelli), [giovannibattista.ratto@hsanmartino.it](mailto:giovannibattista.ratto@hsanmartino.it) (G.B. Ratto).



**Fig. 1.** CT scan performed on admission. Water soluble contrast has been administered by mouth. (a) A left large loculated pleural effusion filled with purulent fluid and air is evident (white asterisk). The wall of such collection is thickened and hyperaemic (arrowheads). The black asterisk shows the atelectatic lower lobe of the lung. (a), (b) A small amount of contrast leaks from the mediastinum into the pleural collection (white arrows). (b) A large amount of contrast mixed with air is filling a para-oesophageal mediastinal collection (black arrow).



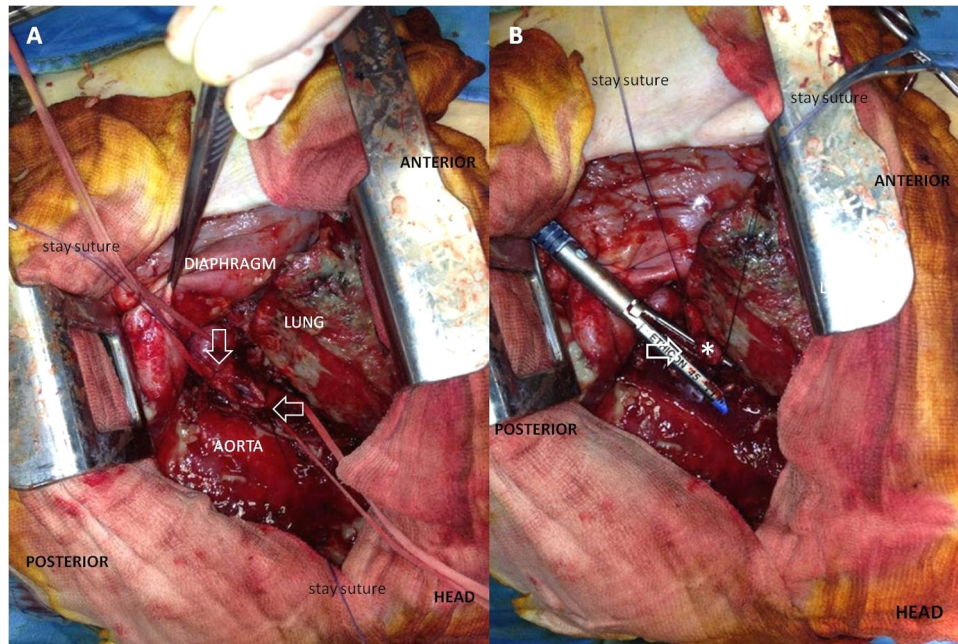
**Fig. 2.** (a) CT scan shows the contrast leakage from the oesophagus (black arrowhead) into the large mediastinal collection (black asterisk). The loculated pleural effusion is also evident (white asterisk). (b) Enlarged vision. Oesophageal perforation (white arrowhead), mediastinal collection (black asterisk), pleural collection with an air-water level (white asterisk).

about 3 cm in length was evident close to the gastro-oesophageal junction. The muscular layer around the perforation was diffusely necrotic and it was removed, thus widely exposing the mucosal layer. The bulging edges of the tear appeared to be inflamed and edematous but still viable. Two stay sutures were placed at both ends of the rupture (Fig. 3a). The mucosal edges were gently grasped with an Allis clamp, so that a 45 mm endoscopic articulating linear cutter (ENDOPATH® ETS-Flex, Ethicon Endo-Surgery) was twice-placed below them on healthy mucosa (Fig. 3b). The seal was tested. The nasogastric tube was then left in place into the stomach. The hiatus was slightly opened, and a limited portion of the gastric fundus was gained. Such kind of “gastric wrap” was wide enough to be positioned over the repaired mucosa and secured with interrupted absorbable stitches to the edges of the resected oesophageal muscular wall. The lower lobe of the lung was decontaminated. Three chest drains were left in place. *Escherichia coli* and *Enterococcus faecalis* were cultured from the pleural fluid. The postoperative course was complicated by left lower lobe pneumonia and systemic infection by multidrug-resistant *Klebsiella*

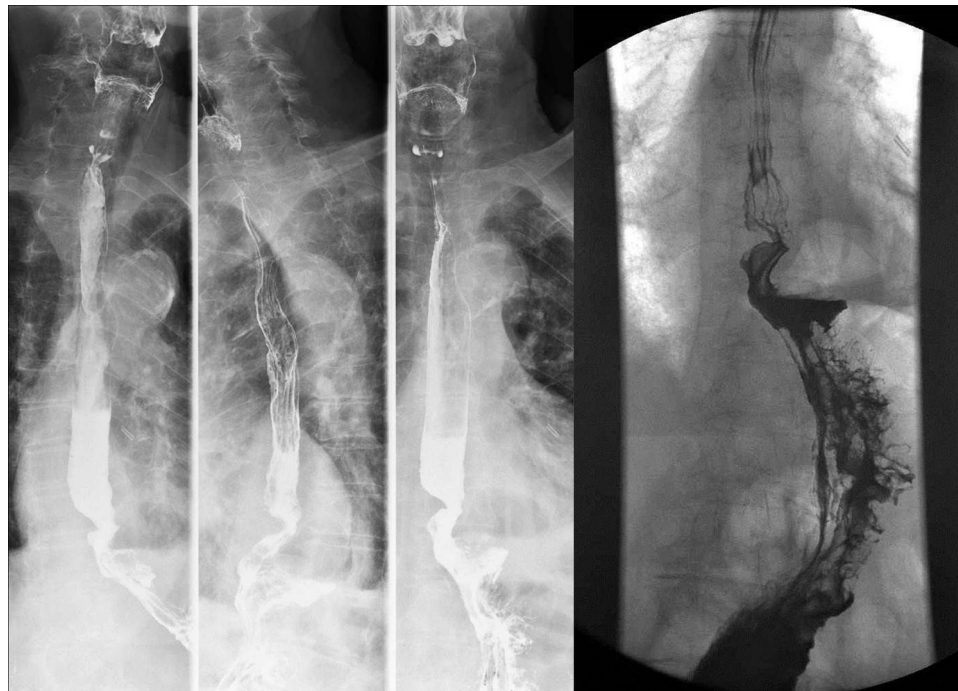*pneumoniae*. A CT scan with oral contrast performed on postoperative day 9 confirmed the seal of the repair and excluded residual collections. The patient resumed a creamy diet. Chest drains were removed on postoperative day 11. The patient was finally discharged home on postoperative day 27 on a normal diet. Her oesophagogram performed after one month is shown in Fig. 4.

**3. Discussion**

Symptoms of spontaneous perforation of the oesophagus have been reported to be absent or very mild in the exceptional circumstances of a small and confined leak [1]. Late diagnosis is likely to occur in such cases [2]. Our patient presented with a seven days-lasting cohort of mild nonspecific symptoms in spite of a three centimeters oesophageal perforation associated with a large mediastinal and pleural collection. The discrepancy between the clinical and the surgical findings is worthy of note in our opinion. Unaccountably, the abscess was probably confined into the medi-



**Fig. 3.** (a) The distal oesophagus has been isolated. The necrotic muscle around the perforation has been widely resected. Two stay sutures have been placed at both ends of the mucosal tear (arrows). (b) A 45 mm endoscopic articulating linear cutter (ENDOPATH® ETS-Flex, Ethicon Endo-Surgery) has been introduced into the operative field from a separate inferior access, later used for a drainage. The stapler was placed twice. The first part of the suture has been already performed (arrow). Note how the edematous mucosal edges are elevated into the jaws of the stapler so that the suture line definitely falls on healthy tissue (asterisk, see text for details).



**Fig. 4.** Contrast study of the oesophagus one month after discharge from the hospital. The patient was on a free diet and she experienced no transit discomfort.

astinum at an early stage. Back drainage of infected material into the oesophageal lumen may be occurred. We observed one additional patient in the past with a diagnostic delay of 10 days and with a similar clinical presentation as the present. Still, he was very elderly. It may be speculated that a sort of age-related hyporeactivity of patients could play a role.

As severe inflammation, crumbly tissues, purulent infection and necrosis are usually encountered, surgeons were usually advised against attempting at repairing the oesophagus in case of very

late diagnosis [6,7]. Possible alternative modalities are conservative or semiconservative treatment [8,9], exclusion and/or diversion procedures [10,11], use of endoprotheses [12,13] and oesophagectomy [14,15]. Nonetheless, primary repair is currently advocated as the treatment of choice since a few series showed that good outcome could be obtained with suturing oesophageal tears in spite of delayed diagnosis [16–20]. Variable rates of recurrent leak and need for re-do surgery are reported, but this does not seem to be associated with increased overall mortality rates [1–4,16–19,21].

Recent advances in intensive care and antibiotic therapy certainly play a major role.

Oesophageal repairing seemed not to be feasible at initial exploration. Nonetheless, as all the necrotic tissues were removed, the mucosa appeared to be viable. As the mucosal edges were extremely friable and the muscular layer was no longer available to be reconstructed, the use of a stapler was deemed appropriate, so that the mucosa could be perfectly approximated with minimal manipulation. An additional advantage is that the inflamed, edematous mucosal edges must necessarily be elevated into the jaws of the stapler so that the suture line definitely falls on healthy tissue. An articulating endoscopic stapler was used as it was easily introduced into the operative field and placed tangentially to the tear with an optimal angle (Fig. 2B). Moreover, such stapler has a triple row of stitches, resulting in a perfectly sealed suture. As a large amount of muscle was removed in our case, the mucosa was redundantly available. In other cases, the muscle should be mobilized well away from the mucosa and a dilator should be used in order to avoid narrowing of the oesophagus [18].

Suture buttressing has been reported to be associated with lower rates of persistent and recurrent leakage, need for re-do surgery and mortality [3,20–22]. As a single layer repair was performed, suture reinforcement was deemed to be appropriate in our case. Nonetheless, successful single layer mucosal repair has been reported previously [4,17,20]. It is emphasized that much more important to a successful repair is a meticulous technique of exposure and repair of the mucosa, usually associated with a drainage gastrostomy [16,17] or to the complete elimination of a possible distal obstruction [18]. As an optimal mucosal approximation on healthy tissue can be accomplished with the stapler, this option seems to be preferable in late cases.

The use of staplers in repairing the perforated oesophagus has been rarely reported. In 1981 Engelberg et al. [23] reported on a 5 cm iatrogenic delayed perforation of the thoracic oesophagus. A single layer repair was performed by means of a TA-55 stapler (Auto Suture®, United States Surgical Corporation, Norwalk, Connecticut). Minimal handling of friable tissues and the stapler capability to fire 19 staples arranged in staggered rows were reported as the main advantages. A series of 13 thoracic oesophageal perforations was reported by Gayet et al. [24]. Eleven perforations were diagnosed late and two were spontaneous. Different types of staplers (TA 30T, TA 55T, TA 90T, U.S. Surgical Corporation®, RL 60T and ES 60T Ethicon®) were used to close the mucosa. Muscular repair was then achieved. There were two failures with one death. The Authors attributed the efficacy of the mechanical suture to the careful exposure of the mucosal layer, to its complete elevation through the jaws of the stapler and to the use of inert and well tolerated metal sutures. Finally, Whyte et al. [18] reported the use of the GIA stapler (Auto Suture, Inc., Norwalk, Conn.) in 9 out of 22 patients who underwent primary repair for thoracic spontaneous and iatrogenic oesophageal perforations. The GIA stapler was reported to be used regardless of the time interval from injury to operation. A double-layer repair is advocated. Twenty-one patients survived in spite of four recurrent leaks. It is not mentioned which kind of repair technique had been used in recurrent cases. Nonetheless, staple closure is reported to be the Authors' preference, provided that a 40F to 46F dilator is used.

#### 4. Conclusion

The spontaneous perforation of the oesophagus can result in a loculated mediastinal and/or pleural abscess, without the signs of frank sepsis. Diagnosis can be missed for days in these cases. The attempt at primary repair of the oesophagus is still indicated. This

should be performed in a double layer fashion, if possible, and a stapler should be preferably used to close the mucosa.

#### Conflict of interest

All authors have no conflict of interest.

#### Funding

There are not any sources of funding for this report.

#### Ethical approval

This report is no a research study.

#### Author contribution

Giacomo Leoncini, Luca Novello, Andrea Denegri, Lucia Morelli, Giovanni B. Ratto: planning the article.

Giacomo Leoncini: collecting and analysing all the data, and-drafting the text.

All the authors approved the revision process and the final version.

#### Consent

Written informed consent was obtained from the patient for publication of this case report and accompanying images. A copy of the written consent is available for review by the Editor-in-Chief of this journal on request.

#### Guarantor

Dr. Lucia Morelli.

#### References

- [1] C.J. Brinster, S. Singhal, L. Lawrence, M.B. Marshall, L.R. Kaiser, J.C. Kucharczuk, Evolving options in the management of esophageal perforation, *Ann. Thorac. Surg.* 77 (2004) 1475–1483.
- [2] J.P. de Schipper, A.F. Pull ter Gunne, H.J.M. Oostvogel, C.J.H.M. van Laarhoven, Spontaneous rupture of the oesophagus: Boerhaave's syndrome in 2008, *Digest. Surg.* 26 (2009) 1–6.
- [3] M. Chirica, A. Champault, X. Dray, L. Sulpice, N. Munoz-Bongrand, E. Sarfati, et al., Esophageal perforations, *J. Visc. Surg.* 147 (2010) e117–e128.
- [4] C.M. Vial, R.I. Whyte, Boerhaave's syndrome: diagnosis and treatment, *Surg. Clin. North Am.* 85 (2005) 515–524.
- [5] A.G. Hill, A.T. Tiu, I.G. Martin, Boerhaave's syndrome: 10 years experience and review of the literature, *ANZ J. Surg.* 73 (2003) 1008–1010.
- [6] W.S. Walker, E.W.J. Cameron, P.R. Walbaum, Diagnosis and management of spontaneous transmural rupture of the oesophagus (Boerhaave's syndrome), *Br. J. Surg.* 72 (1985) 204–207.
- [7] W.G. Jones, R.J. Ginsberg, Esophageal perforation: a continuing challenge, *Ann. Thorac. Surg.* 53 (1992) 534–543.
- [8] T.D. Ivey, D.A. Simonowitz, D.H. Dillard, D.W. Miller Jr., Boerhaave syndrome: successful conservative management in three patients with late presentation, *Am. J. Surg.* 141 (1981) 531–533.
- [9] S.B. Vogel, W.R. Rout, T.D. Martin, P.L. Abbitt, Esophageal perforation in adults: aggressive, conservative treatment lowers morbidity and mortality, *Ann. Surg.* 241 (2005) 1016–1021.
- [10] H.C. Urschel Jr., M.A. Razzuk, R.E. Wood, N. Galbraith, M. Pockey, D.L. Paulson, Improved management of esophageal perforation: exclusion and diversion in continuity, *Ann. Surg.* 179 (1974) 587–590.
- [11] P.A. Linden, R. Bueno, S.J. Mentzer, L. Zellos, A. Lebenthal, Y.L. Colson, et al., Modified T-tube repair of delayed esophageal perforation results in a low mortality rate similar to that seen with acute perforations, *Ann. Thorac. Surg.* 83 (2007) 1129–1133.
- [12] V. Koivukangas, F. Biancari, S. Merilainen, T. Ala-Kokko, J.O. Saarnio, Oesophageal stenting for spontaneous esophageal perforation, *J. Trauma Acute Care Surg.* 73 (2012) 1011–1013.
- [13] M. Schweigert, R. Beattie, N. Solymosi, K. Booth, A. Dubecz, A. Muir, et al., Endoscopic stent insertion versus primary operative management for spontaneous rupture of the esophagus (Boerhaave syndrome): an

- international study comparing the outcome, *Am. Surg.* 79 (2013) 634–640.
- [14] J.A. Salo, J.O. Isolaari, L.J. Heikkila, H.T. Markkula, L.O. Heikkinen, E.O. Kivilaakso, et al., Management of delayed esophageal perforation with mediastinal sepsis. Esophagectomy or primary repair? *J. Thorac. Cardiovasc. Surg.* 106 (1993) 1088–1091.
- [15] A. Altorjav, J. Kiss, A. Voros, E. Sziranyi, The role of esophagectomy in the management of esophageal perforations, *Ann. Thorac. Surg.* 65 (1998) 1433–1436.
- [16] J. Jougon, T. Mc Bride, F. Delcambre, A. Minniti, J.F. Velly, Primary oesophageal repair for Boerhaave's syndrome whatever the free interval between perforation and treatment, *Eur. J. Cardiothorac. Surg.* 25 (2004) 475–479.
- [17] D.R. Lawrence, S.K. Ohri, R.E. Moxon, E.R. Townsend, S.W. Fountain, Primary esophageal repair for Boerhaave's syndrome, *Ann. Thorac. Surg.* 67 (1999) 818–820.
- [18] R.I. Whyte, M.D. Iannettoni, M.B. Orringer, Intrathoracic esophageal perforation. The merit of primary repair, *J. Thorac. Cardiovasc. Surg.* 109 (1995) 140–146.
- [19] N. Wang, A.J. Razzouk, A. Safavi, K. Gan, G.S. Van Arsdell, P.M. Burton, et al., Delayed primary repair of intrathoracic esophageal perforation: is it safe, *J. Thorac. Cardiovasc. Surg.* 111 (1996) 114–122.
- [20] C.D. Wright, D.J. Mathisen, J.C. Wain, A.C. Moncure, A.D. Hilgenberg, H.C. Grillo, Reinforced primary repair of thoracic oesophageal perforation, *Ann. Thorac. Surg.* 60 (1995) 245–249.
- [21] L. Sulpice, S. Dileon, M. Rayar, B. Badic, K. Boudjema, J.P. Bail, et al., Conservative surgical management of Boerhaave's syndrome: experience of two tertiary referral centers, *Int. J. Surg.* 11 (2013) 64–67.
- [22] T.H. Gouge, H.J. Depan, F.C. Spencer, Experience with the Grillo pleural wrap procedure in 18 patients with perforation of the thoracic esophagus, *Ann. Surg.* 209 (1989) 612–617.
- [23] M. Engelberg, R.J. Jedeikin, D. Eschkol, S. Hoffman, R. Reiss, Use of a stapling technique in closure of perforation of the esophagus, *Am. J. Surg.* 142 (1981) 300–301.
- [24] B. Gayet, P. Breil, F. Fekete, Mechanical sutures in perforation of the thoracic esophagus as a safe procedure in patients seen late, *Surg. Gynecol. Obstet.* 172 (1991) 125–128.

#### Open Access

This article is published Open Access at [sciendoirect.com](http://sciendoirect.com). It is distributed under the [IJSCR Supplemental terms and conditions](#), which permits unrestricted non commercial use, distribution, and reproduction in any medium, provided the original authors and source are credited.