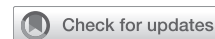

Mind the gap: Open repair of iatrogenic cor triatriatum dexter after previous atrial septal defect repair



Rachel NeMoyer, MD,^a Tiffany Vaughan, BA,^b James Witten, MD,^a Rashed Mahboubi, MD,^a Miza Salim Hammoud, MD,^a Shawn Shah, MD,^a Munir Ahmad, MD,^a Hani Najm, MD,^a Robert Stewart, MD,^a and Tara Karamlou, MD, MSc,^a Cleveland, Ohio

From the ^aDepartment of Thoracic & Cardiovascular Surgery, Heart Vascular and Thoracic Institute, Cleveland Clinic; and ^bCase Western Reserve University School of Medicine, Cleveland, Ohio.

Received for publication June 12, 2023; revisions received July 28, 2023; accepted for publication Aug 4, 2023; available ahead of print Aug 20, 2023.

Address for reprints: Tara Karamlou, MD, MSc, Department of Thoracic & Cardiovascular Surgery, Heart Vascular and Thoracic Institute, Cleveland Clinic, 9500 Euclid Ave, J4, Cleveland, OH 44195 (E-mail: karamlt@ccf.org).

JTCVS Techniques 2023;21:181-3

2666-2507

Copyright © 2023 The Author(s). Published by Elsevier Inc. on behalf of The American Association for Thoracic Surgery. This is an open access article under the CC BY-NC-ND license (<http://creativecommons.org/licenses/by-nc-nd/4.0/>).

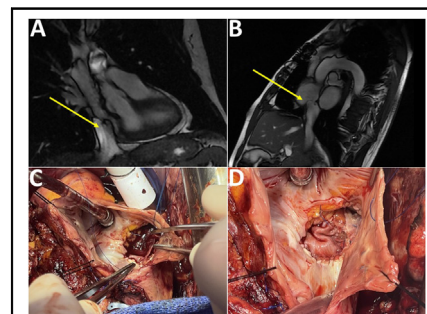
<https://doi.org/10.1016/j.xjtc.2023.08.006>

Cor triatriatum dexter (CTD) is a congenital cardiac anomaly whereby a membranous structure divides the right atrium (RA) into 2 chambers. Normal embryological development involves regression of the right valve of the sinus venosus; however, failure of regression can lead to CTD with varying clinical manifestations.¹ We present a case of what we term “iatrogenic” CTD, where the RA was divided into 2 chambers from a previous atrial septal defect (ASD) repair with persistent, thickened eustachian valve (EV) leading to liver cirrhosis.

CASE PRESENTATION

A 55-year-old male patient with a congenital ASD presented to the office, reporting an asymptomatic cardiac murmur from childhood and was diagnosed with an ASD at age 15 years. Right heart catheterization (RHC) showed an elevated Qp/Qs (pulmonary/systemic blood flow) suggestive of left-to-right shunting. The patient underwent surgical ASD closure at age 17 years at another institution. The operative report is unavailable. The patient provided written consent for this publication; institutional review board approval was not required.

The patient was asymptomatic throughout much of adulthood. At age 45 years, his elevated liver enzymes prompted liver imaging and biopsy, which showed liver fibrosis due to venous congestion. He exhibited increasing fatigue with exertion, abdominal bloating, and lower-extremity edema. Cardiac magnetic resonance (MR) showed normal biventricular function and a possible obstructive membrane at the inferior vena cava (IVC)/right atrium (RA) junction. A local computed tomography angiography demonstrated a patent IVC without a membrane.



A-D, MRI; dilated IVC, thickened EV, and IVC obstruction. ASD. Bovine pericardial patch.

CENTRAL MESSAGE

Right-heart failure symptoms and history of cardiac intervention may suggest an “iatrogenic” cor triatriatum dexter. Although rare, clinical awareness is important to avoid extracardiac complications.

At our institution, repeat MR and computed tomography confirmed liver disease with mechanical obstructive etiology. RHC with intracardiac echo showed a thick band of tissue at the IVC/RA junction, with evidence of flow acceleration at the CTD and a sinus venosus versus residual ASD (Figures 1 and 2). The IVC pressure was 17 to 18 mm Hg (normal 5-10 mm Hg), with normal pressures above the level of obstruction. The Qp/Qs was 1.05. On cardiac angiogram, the catheter could advance from the RA to the pulmonary vein, confirming a residual ASD.

While ballooning could have enlarged the IVC to RA opening, the benefit and durability of repair were unknown, given the EV thickness, degree of liver dysfunction, and need to also address a residual ASD. Moreover, the patient desired definitive correction, as he came from overseas. Our multidisciplinary consensus was that open heart surgery with excision of the remnant EV and closure of the ASD would be optimal.

In the operating room, transesophageal echo (TEE) confirmed the expected anatomy. The IVC was dilated; a

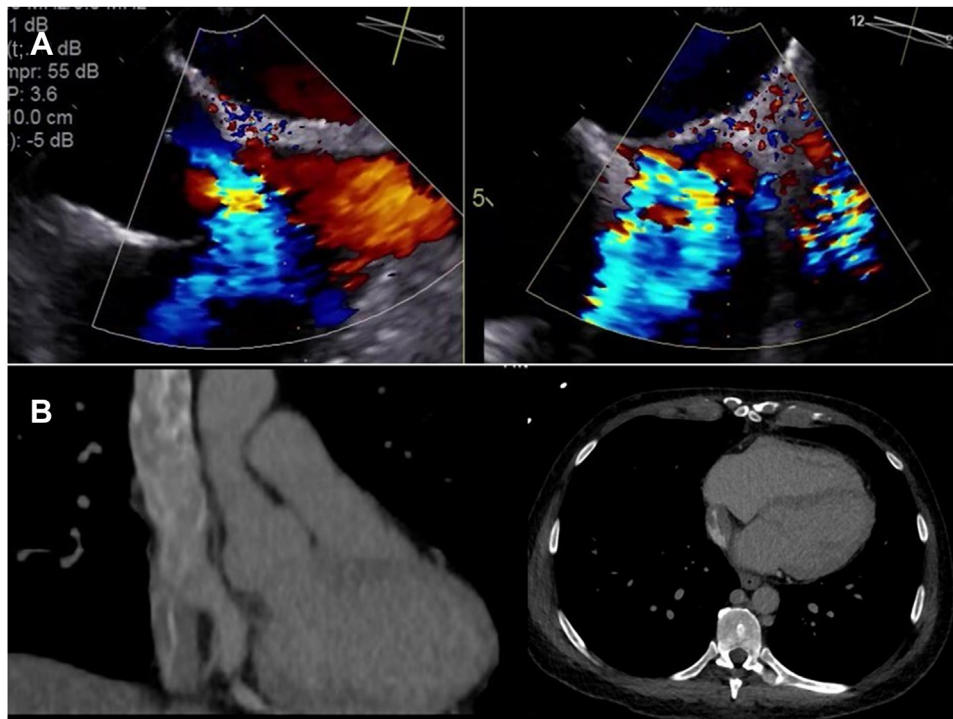


FIGURE 1. A, Intracardiac echocardiogram demonstrates a thick band of tissue at the inferior vena cava/right atrial junction, suggesting a prominent eustachian valve (EV) leading to cor triatriatum dexter. B, Computed tomography demonstrating the EV thickness and obstruction.

very large azygous vein drained into the superior vena cava. No cannulation sites were identified, suggesting the initial operation was completed under inflow occlusion. The RA was opened away from the previous transverse incision. A thickened EV, which was sewn to the inferior edge of a residual ASD with near occlusion of the IVC orifice, was excised to expose the entire IVC orifice. The ASD was

enlarged, then a bovine pericardial patch was sewn in. The patient was uneventfully weaned from bypass. TEE demonstrated no residual turbulence through the IVC; bubble study was negative.

The postoperative course was uneventful. The patient is doing well 1 year later with normalization of liver enzymes and significant improvement in liver stiffness, measured by

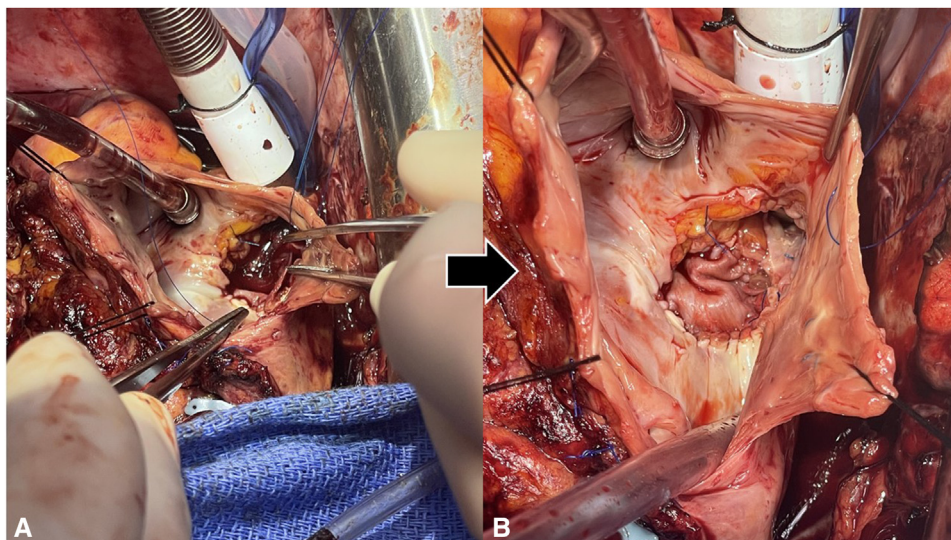


FIGURE 2. Enlarged atrial septal defect before (A) and after (B) bovine pericardial patch.

magnetic resonance imaging elastography showing average liver stiffness of 5.5 kPa and controlled attenuation parameter score of 180.

DISCUSSION

CTD is an extremely rare heart conditions owing to failure of tissue to regress during embryological development. In this patient, the RA being divided into 2 chambers by a membrane from previous ASD repair—an iatrogenic rather than developmental failure—is even rarer. We present a patient who underwent an ASD repair as a teenager and developed iatrogenic CTD that caused right-sided heart failure and liver cirrhosis, requiring surgical repair in his 50s.

Few papers highlight the varied clinical presentation of iatrogenic CTD. A 2011 case featured a 29-year-old female patient with asymptomatic CTD found on follow-up TEE after transcatheter ASD closure.² Another case report of a 63-year-old man demonstrated CTD with exertional fatigue, lower-extremity edema, and orthostatic hypotension.³ The patient had severe tricuspid stenosis and RA dilation, due to CTD-like anatomy caused by pacemaker lead fibrosis.

Our case report also illustrates the risks of inflow occlusion used in earlier era cardiac surgery.⁴ Surgeons in the 1970s would have considered our patient's simple ASD closure a complete repair. However, systemic and cerebral malperfusion during inflow occlusion can cause cardiac and neurologic complications, thereby

heightening the risk of error caused by the initial ASD closure.⁵

Symptoms of right-sided heart failure, including hepatic cirrhosis and history of cardiac intervention, may suggest a diagnosis of iatrogenic CTD. Although rare, clinicians should know the causes and clinical manifestations of this anomaly to determine the most optimal treatment.

Conflict of Interest Statement

The authors reported no conflicts of interest.

The *Journal* policy requires editors and reviewers to disclose conflicts of interest and to decline handling or reviewing manuscripts for which they may have a conflict of interest. The editors and reviewers of this article have no conflicts of interest.

References

1. Bindra BS, Patel Z, Patel N, Choudhary KV, Patel V. Cor triatriatum dexter as an incidental finding: role of two-dimensional transthoracic echocardiography. *Cureus*. 2019;11:e5683.
2. Lodha A, Haran M, Enakpene E, Sadiq A, Shani J. Cor triatriatum dextro iatrogenica: an unusual complication of atrial septal defect closure device. *Echocardiography*. 2012;29:E45-7.
3. Premkumar A, Paine A, Bloom J, Wolfe S, Cameron D. A case of iatrogenic cor triatriatum dexter. *CTSNet*. 2022; <https://doi.org/10.25373/ctsnet.19701343.v1>
4. Pettersson GB, Karamlou T, Blackstone EH. Identifying, capturing, and understanding surgery for adult congenital heart disease: a novel framework. *J Thorac Cardiovasc Surg*. 2022.
5. Singh J, Dhaliwal RS, Biswal S, Swami N. Inflow occlusion in the era of modern cardiac surgery. *J Thorac Cardiovasc Surg*. 2006;132:1246. author reply 1246-7.