

 **Case Report** 

# Quantification of Mesenteric Blood Flow by Magnetic Resonance Flow Imaging in Patients with Arterial Dissection

Hiroaki Sasaki, MD, PhD,<sup>1</sup> Yosuke Inoue, MD,<sup>1</sup> Yoshiaki Watanabe, MD,<sup>2</sup>  
Yoshiaki Morita, MD, PhD,<sup>2</sup> Hitoshi Matsuda, MD, PhD,<sup>1</sup> and Junjiro Kobayashi, MD, PhD<sup>1</sup>

Mesenteric ischemia is an infrequent, but potentially dangerous, complication of aortic or mesenteric artery dissection. Severe mesenteric ischemia presenting as a malperfusion syndrome, caused by aortic dissection or isolated mesenteric dissection, should be treated immediately by central aortic repair or angioplasty. However, treatment of non-critical, symptomatic mesenteric ischemia without narrowing true lumen of the aorta or localized mesenteric artery dissection was difficult. We treated two distinctly different cases of non-critical, symptomatic mesenteric ischemia superior mesenteric artery ischemia needing intensive care and mesenteric blood flow was determined by quantification with cine-phase contrast magnetic resonance imaging.

**Keywords:** malperfusion syndrome, superior mesenteric artery, magnetic resonance imaging

## Introduction

The treatment for complicated acute type B aortic dissection, including severe mesenteric ischemia, has usually been thoracic endovascular aortic repair (TEVAR) in recent years.<sup>1)</sup> However, it is difficult to decide the indication and timing of surgical or interventional treatment for non-

critical, symptomatic mesenteric ischemia resulting from a reduction in mesenteric blood flow by arterial dissection. This report concerns two distinctly different patients with non-critical, symptomatic mesenteric ischemia, whose mesenteric blood flow was quantified by phase contrast magnetic resonance imaging (PC-MRI).

## Case Report

### Patient 1

A 55 year-old female with a previous history of treatment for cerebral arterial aneurysm presented with acute onset of severe back pain. She was admitted to a local hospital with a diagnosis of acute type B aortic dissection. During the two-week medical treatment, no evidence of malperfusion syndrome or rapid aortic expansion was detected. However, she subsequently suffered from abdominal pain, nausea, and vomiting. Computed tomography (CT) revealed a caliber change in the duodenum under the superior mesenteric artery (SMA). A nasoduodenum tube was placed to decompress the upper gastrointestinal tract due to suspected SMA syndrome. Nevertheless, her symptoms, including dull abdominal pain, dysphasia, and weight loss continued, leading to an exclusive diagnosis of mesenteric ischemia. The patient was then transferred to our hospital for further treatment five weeks after the onset of type B aortic dissection.


Contrast enhanced CT showed a partial thrombosis of the false lumen, descending to the abdominal aorta. The true lumen inside the celiac artery (CA) and the SMA were narrow (Figs. 1A, 1B and 1C). Abdominal vascular sonography revealed accelerated blood flow at the orifice of CA (3.4 m/s) and SMA (4.1 m/s) (Fig. 1D). For quantitative evaluation of the non-critical, symptomatic mesenteric ischemia, fasting and postprandial status of the superior mesenteric vein (SMV) was examined by PC-MRI.

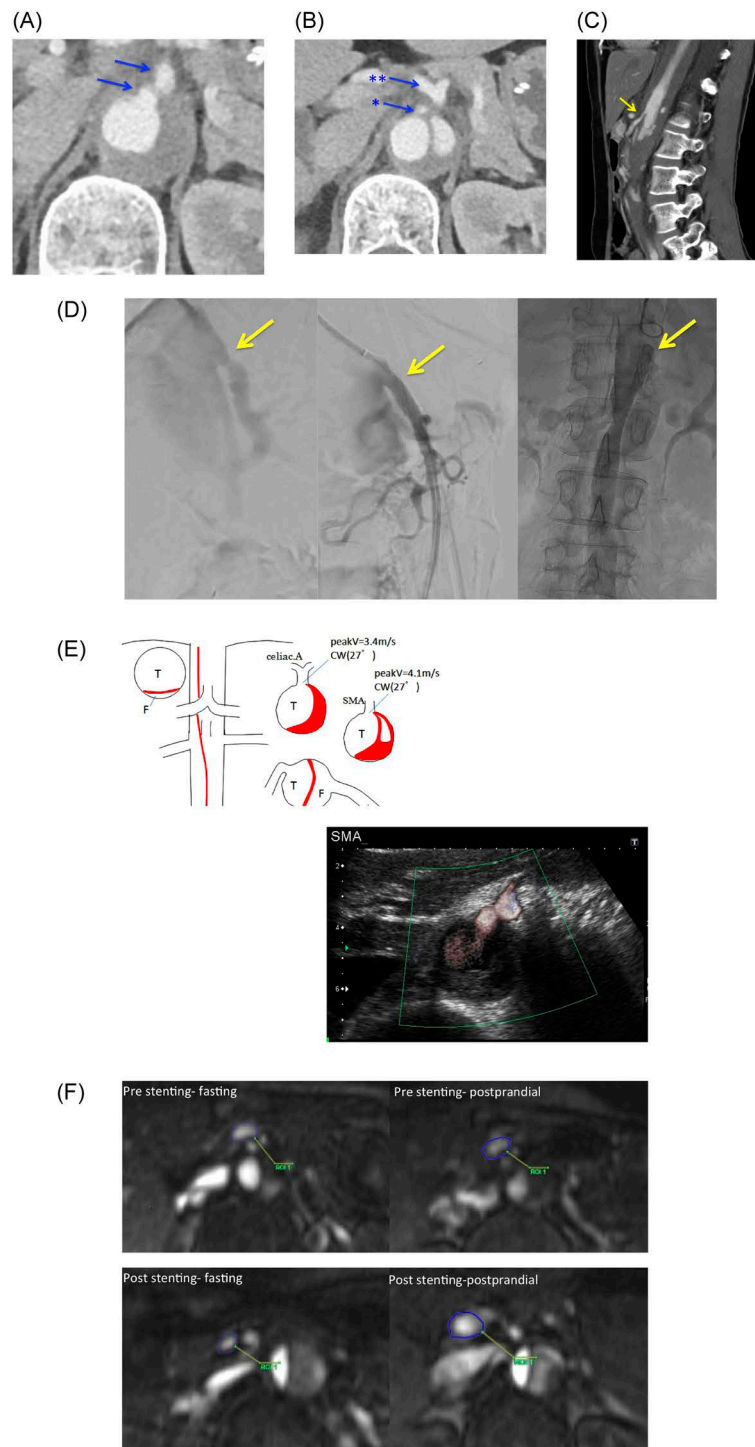
Briefly, PC-MRI was carried out with the patient in the supine position in the fasting state and 30 min after ingesting a standard meal. Imaging was performed on a 1.5-T MRI (Magnetom Sonata; Siemens, Erlangen, Germany).

<sup>1</sup>Department of Cardiovascular Surgery, National Cerebral and Cardiovascular Center, Suita, Osaka, Japan

<sup>2</sup>Department of Radiology, National Cerebral and Cardiovascular Center, Suita, Osaka, Japan

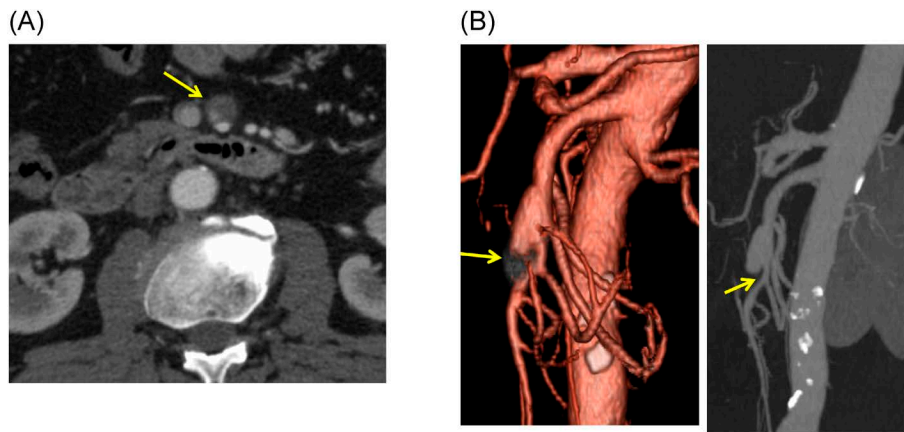
Received: December 16, 2018; Accepted: March 8, 2019  
Corresponding author: Hitoshi Matsuda, MD, PhD. Department of Cardiovascular Surgery, National Cerebral and Cardiovascular Center, 5-7-1 Fujishiro-dai, Suita, Osaka 565-8565, Japan  
Tel: +81-6-6833-5012, Fax: +81-6-6833-9865  
E-mail: hitmat@mist.ocn.ne.jp

 ©2019 The Editorial Committee of Annals of Vascular Diseases. This article is distributed under the terms of the Creative Commons Attribution License, which permits use, distribution, and reproduction in any medium, provided the credit of the original work, a link to the license, and indication of any change are properly given, and the original work is not used for commercial purposes. Remixed or transformed contributions must be distributed under the same license as the original.



**Fig. 1** Patient 1.

(A, B) Axial image of the celiac artery and superior mesenteric artery using contrast computed tomography (CT) performed on the day of admission. Blue arrows indicate stenosis of the true lumen at the orifice of (A) the celiac artery and (B) superior mesenteric artery (\*) and celiac artery (\*\*). (C) Multiplanar reformation view reconstructed by CT angiography. The yellow arrow points the stenosis of true lumen at the superior mesenteric artery. (D) Pre-interventional angiography (left) and post-interventional angiography (center). Since the first stent migrated distally, another stent was added (right). The yellow arrows point to the stenosis of true lumen at the superior mesenteric artery (SMA). (E) Schema of ultrasonography imaging and imaging of Doppler ultrasonography. (F) Tracing of the axial superior mesenteric vein to assess the blood flow volume on cine-phase contrast magnetic resonance imaging at each phase of case 1. Pre-stenting fasting phase (upper, left panel) and pre-stenting postprandial phase (upper, right panel), post-stenting fasting phase (lower, left panel) and post-stenting postprandial phase (lower, right panel).  
 celiac. A: celiac artery; T: true lumen; F: false lumen; CW: continuous wave



**Fig. 2** Patient 2.

(A) Axial image of the superior mesenteric artery using contrast computed tomography on the day of admission. The yellow arrow indicates the mid-portion of the superior mesenteric artery. (B) Three-dimensional reconstructed imaging by computed tomography angiography (left side) and maximum intensity projection view (right side). The yellow arrow points the stenosis of true lumen at the superior mesenteric artery.

One 5-mm axial section was obtained at the level of the head of the pancreas, perpendicular to the SMA and to the SMV. A two-dimensional PC-MRI image was acquired during breath hold using retrospective ECG (electrocardiographically) triggering (echo time 3.2 ms, temporal resolution 55 ms, flip angle 15 degrees, slice thickness 5 mm, FOV (field-of-view) 320×240 mm, matrix 125×256, VENC (velocity encoding) 100 to 150 cm/s depending on the velocity of target vessels). The SMV blood was examined on a two-dimensional cine image during breath hold with ECG triggering. (VENC 75 to 80 cm/s, which were same in fasting and post-prandial phase.)<sup>2)</sup>

As the increase in the SMV blood flow at the postprandial phase, compared to the fasting phase, remained at 43% on PC-MRI, endovascular placement of a bare stent inside the SMA was indicated to expand the true lumen (Fig. 1E). The patient's symptoms surprisingly disappeared just after the intervention, and the amount of oral intake fully recovered. She was discharged home with no digestive symptoms.

Two months after the intervention, PC-MRI revealed a 150% increase in SMV blood flow at the postprandial phase compared to the fasting phase (Fig. 1F). No abdominal symptoms recurred after the intervention.

### Patient 2

A 61-year-old male with no previous medical history presented with postprandial epigastric pain, which worsened gradually. At a local hospital, the localized dissection inside the SMA was diagnosed on CT, and he was referred to us for further treatment. CT angiography revealed aneurysmal change at the origin of the SMA, and a stenotic lesion was detected. SMA dissection with a thrombosed

false lumen was confirmed (Figs. 2A and 2B). Abdominal MRI showed narrowing of the distal SMA, but there was no significant increase in peak velocity (0.9 m/s). PC-MRI showed the increase in the SMV blood flow at the postprandial phase remained at 43%. Revascularization of the SMA with endovascular placement of a bare stent or bypass grafting to the SMA were planned to treat digestive symptoms. However, the patient rejected intervention and preferred close observation. His postprandial abdominal discomfort has persisted for four months during the follow-up period.

### Discussion

Mesenteric ischemia, due to acute type B aortic dissection, is one of the fatal complications of aortic dissection. Critical malperfusion should be treated by emergent TEVAR or revascularization of the SMA.<sup>3)</sup> However, TEVAR alone might be ineffective for a patient with a long dissecting lesion inside the SMA. In addition, a stenotic, but not occlusive, lesion can resolve spontaneously with recanalization of the true lumen or development of collateral flows. It is, therefore, difficult to decide the optimal treatment strategy for symptomatic, but not critical, mesenteric ischemia, which usually needs intensive care to prevent progression to the critical state and avoid the delay of treatment.

Except for the measurement of flow velocity in SMA by vascular sonography, quantitative evaluation of mesenteric blood flow is difficult. Diminished postprandial hyperemia is a positive factor indicating invasive treatment for mesenteric ischemia. Dalman et al. reported that the quantitative analysis of SMV using PC-MRI, which manifested a 270% gain in flow volume at the postprandial phase

in control volunteers, was an accurate and non-invasive modality. Dalman and colleagues also found that only of 70% increasing postprandial hyperemia was detected even though asymptomatic patients with aorto-mesenteric occlusive diseases and 29% increasing of itself in symptomatic patients. The first description of the present study presented 43% increasing, which was comparable to data with symptomatic patients with aorto-mesenteric occlusive disease.<sup>2)</sup> No optimal cut-off line or criteria exist in this treatment; however, our indication for patient 1 might be justified.

Naganawa et al. also investigated the volumetric flow of not only SMA but also the inferior mesenteric artery (IMA).<sup>4)</sup> They found that IMA did not show a significant reaction against the food challenge, which was completely different from that of SMA. They concluded that the difference in blood supply to the small and large intestine is the cause of the different reactions of SMA and IMA against the food challenge.

In our study reported here of two distinctly different patients, patient 1 showed recovery of postprandial hyperemia from 43% to 150% after endovascular stenting of SMA, but patient 2 remained symptomatic with no treatment for improving the SMA blood flow, which increased at the postprandial phase and remained at 43%. However, the follow-up period was insufficient. Further follow-up, especially in patient 2, is critical.

The critical threshold of PC-MRI for indicating mesenteric intervention in patients with symptomatic, but not critical, mesenteric ischemia remains to be investigated. However, the utility of PC-MRI for these two patients has been confirmed.

## Conclusion

PC-MRI is a modality with potential for helping to decide on invasive treatment for non-critical, symptomatic mes-

enteric ischemia.

## Disclosure Statement

All authors have no financial relationship with a biotechnology manufacturer, a pharmaceutical company, or other commercial entity that has an interest in the subject matter or materials discussed in the manuscript.

## Author Contributions

Study conception: HS, YI

Data collection: HS, YI, YW, YM

Analysis: YW, YM

Investigation: HS, YI

Writing: HS, YI, HM

Funding acquisition: no funding for this article

Critical review and revision: all authors

Final approval of the article: all authors

Accountability for all aspects of the work: all authors

## References

- 1) Kato N, Shimono T, Hirano T, et al. Midterm results of stent-graft repair of acute and chronic aortic dissection with descending tear: the complication-specific approach. *J Thorac Cardiovasc Surg* 2002; **124**: 306-12.
- 2) Dalman RL, Li KC, Moon WK, et al. Diminished postprandial hyperemia in patients with aortic and mesenteric arterial occlusive disease. Quantification by magnetic resonance flow imaging. *Circulation* 1996; **94 Suppl**: II206-10.
- 3) Kamman AV, Yang B, Kim KM, et al. Visceral malperfusion in aortic dissection: the Michigan experience. *Semin Thorac Cardiovasc Surg* 2017; **29**: 173-8.
- 4) Naganawa S, Cooper TG, Jenner G, et al. Flow velocity and volume measurement of superior and inferior mesenteric artery with cine phase contrast magnetic resonance imaging. *Radiat Med* 1994; **12**: 213-20.