



Contents lists available at ScienceDirect

## International Journal of Surgery Case Reports

journal homepage: [www.casereports.com](http://www.casereports.com)Ileal malignant hemangioendothelioma as a hypervascular lesion on computed tomography scan<sup>☆</sup>Hang Li<sup>a</sup>, Deepa Shah<sup>b</sup>, Abhishek Shah<sup>a</sup>, Xiang Qiu<sup>a</sup>, Dianbo Cao<sup>a,\*</sup><sup>a</sup> Department of Radiology, The First Hospital of Jilin University, Changchun 130021, Jilin Province, PR China<sup>b</sup> Department of Internal Medicine, China–Japan Union Hospital of Jilin University, Changchun 130021, Jilin Province, PR China

## ARTICLE INFO

## Article history:

Received 19 April 2013

Received in revised form 9 September 2013

Accepted 9 September 2013

Available online 26 November 2013

## Keywords:

Computed tomography (CT)

Epithelioid hemangioendothelioma

Ileum

Immunohistochemical study

Prognosis

## ABSTRACT

**INTRODUCTION:** Malignant epithelioid hemangioendothelioma (EHE) is an uncommon and grave vascular tumor. EHE is frequently angiocentric and is associated with a medium sized vessel, especially a vein. No definite etiological associations have been ascribed to this tumor so far, except an association with oral contraceptives in EHE of liver.

**PRESENTATION OF CASE:** A 47 year old man presented with the complaint of intermittent black stool over the past two weeks. Occasionally, he experienced pain in left lower abdomen. On Computed Tomography (CT), it showed hypervascular lesion in the ileum with persistent enhancement. An exploratory laparotomy was performed with short segmental resection and functional end-to-end anastomosis. It was diagnosed finally with the histopathological and immunohistochemical analysis as a malignant EHE.

**DISCUSSION:** EHE is an uncommon endothelial tumor that most frequently arises in soft tissue, liver, lung and skeleton. It behaves biologically in between benign epithelioid hemangioma and the more aggressive epithelioid angiosarcoma. Although a standard systemic treatment for malignant EHE has not been fully established, complete surgical excision is strongly recommended if feasible.

**CONCLUSION:** EHE has a variable presentation and CT is helpful in identifying ileal EHE timely in the early stage, even when there is no obvious mass formation, however the diagnosis can be confirmed only after histopathological and immunohistochemical studies.

© 2013 The Authors. Published by Elsevier Ltd on behalf of Surgical Associates Ltd. All rights reserved.

## 1. Introduction

Epithelioid hemangioendothelioma (EHE) is an uncommon malignant vascular tumor and characterized by an often unpredictable clinical course. This disease entity was first described by Enzinger and Weiss in 1982.<sup>1</sup> There is no definitive association of this disease with any causative factor except for oral contraceptives in hepatic EHE.<sup>2</sup> The incidence of this tumor is less than 3% of all tumors in the small intestine.<sup>3</sup> Due to its variable clinical course, it has been difficult to identify and diagnose this disease in the early phase. Computed tomography (CT) scan has shown some promising investigation in identifying this disease, as described in our case. However, final diagnosis can be made only by the aid of histopathological and immunohistochemical studies. Due to

inability to diagnose this disease in the early stage, it can lead to high mortality and the 5-year survival rate for those patients suffering from EHE is 33.5%.<sup>4</sup> Here, we report such a patient in the early stage when searching for the etiology of gastrointestinal tract bleeding by multiphase CT examination. To our knowledge, no similar case has been described in the literature yet.

## 2. Presentation of case

A 47-year-old man was admitted to our hospital with intermittent black stool over the past 2 weeks. Occasionally, he experienced intermittent pain in the left lower abdomen. On admission, physical examination was negative for abdominal palpable mass. The patient denied taking any non-steroidal anti-inflammatory drugs. Except for the positive fecal occult blood test and microcytic, hypochromic anemia with decrease hemoglobin values down to 5.5 g/L, all the other laboratory values including tumor markers were in the normal range. An upper gastrointestinal endoscopy and colonic endoscopy did not reveal any cause or site of gastrointestinal tract bleeding. Abdominal ultrasound was also normal. Abdominal contrast-enhanced CT scan showed a hypervascular lesion with persistent enhancement and contrast extravasations in the ileum (Figs. 1–3). An exploratory laparotomy was immediately performed. During operation, regional bowel wall thickening associated with a small area of ulceration was found in the ileum

<sup>☆</sup> This is an open-access article distributed under the terms of the Creative Commons Attribution-NonCommercial-No Derivative Works License, which permits non-commercial use, distribution, and reproduction in any medium, provided the original author and source are credited.

\* Corresponding author at: Department of Radiology, The First Hospital of Jilin University, No. 71 XinMin Street, Changchun 130021, PR China.

Tel.: +86 043188782911; fax: +86 043185654528.

E-mail addresses: [360303992@qq.com](mailto:360303992@qq.com) (H. Li), [deepa0205@gmail.com](mailto:deepa0205@gmail.com) (D. Shah), [shahabhi64@gmail.com](mailto:shahabhi64@gmail.com) (A. Shah), [qx3290@sina.com](mailto:qx3290@sina.com) (X. Qiu), [dianbocao@gmail.com](mailto:dianbocao@gmail.com) (D. Cao).

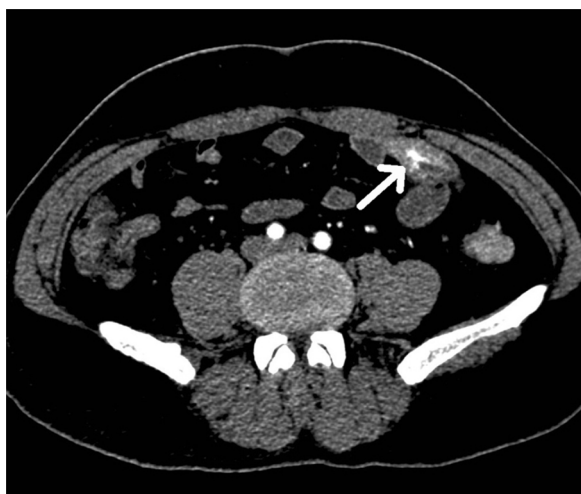


Fig. 1. Axial section of CT abdomen (arterial phase) showing hypervascular lesion in ileum.

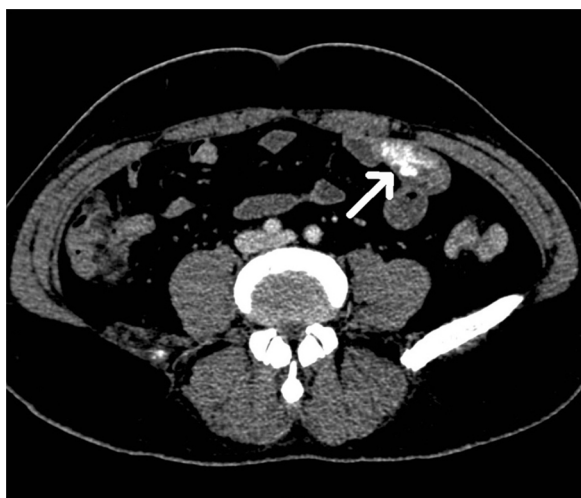


Fig. 2. Axial section of CT abdomen (portal phase) showing hypervascular lesion in ileum.

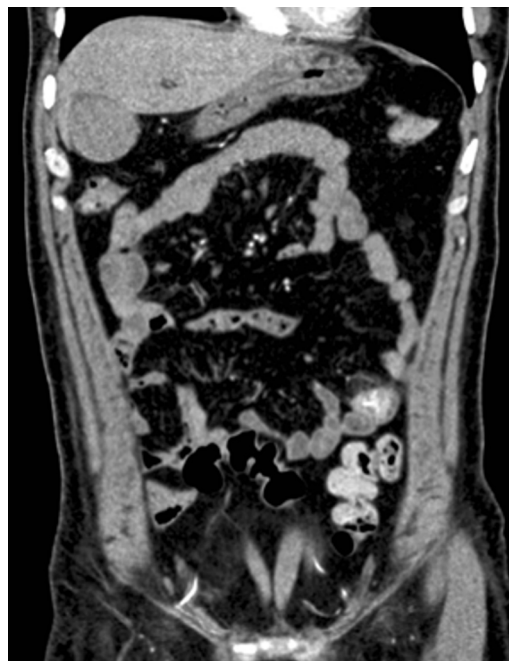

Fig. 3. Coronal section of CT abdomen showing hypervascular lesion in ileum.

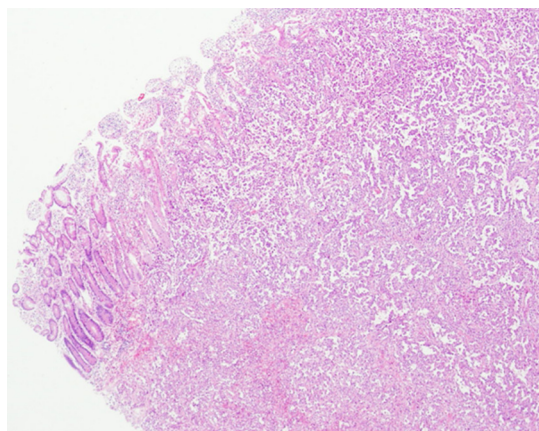


Fig. 4. Resected specimen showed to be malignant hemangioendothelioma on the basis of microscopic findings.

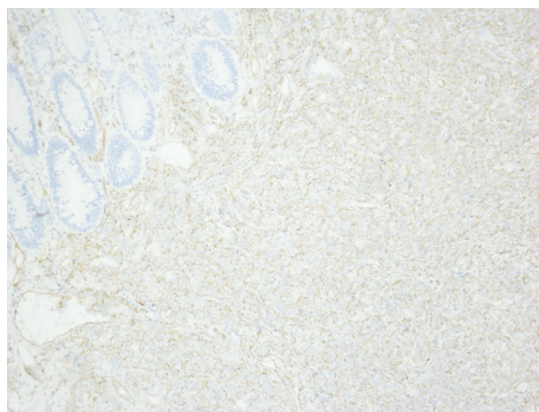


Fig. 5. Resected specimen showed to be malignant hemangioendothelioma on the basis of immunohistological stains of CD31.

about 150 cm proximal to the ileocecal valve, and a short segmental resection was done with a functional end-to-end anastomosis. On histopathological examination, resected specimen was confirmed to be malignant hemangioendothelioma with regional lymphnode metastasis (Figs. 4 and 5). The patient had uneventful recovery and was discharged on 7th post-operative day. He refused for chemotherapy or antiangiogenic agents, and died on the post-operative follow-up of 18 months.

3. Discussion

EHE is an uncommon endothelial tumor that most frequently arises in soft tissue, liver, lung and skeleton. It behaves biologically in between benign epithelioid hemangioma and the more aggressive epithelioid angiosarcoma. Malignant EHE can be seen in most age groups and has its peak frequency in the 2nd and 3rd decades. The tumor affects males and females equally and develops in whites disproportionately more often than members of other races.<sup>1</sup> Although EHE has an equal sex distribution, involvement of the lung and liver is more frequently observed in women. There are no good modalities for diagnosing this disease prior to surgery

due to its uncertain presentations. But radiological diagnosis can sometimes be helpful, especially contrast-enhanced CT scan on the basis of its specific constituent components, even if there is no obvious mass formation. EHE is frequently angiocentric and is associated with a medium sized vessel, especially a vein. The tumor, first described in the lung was designated “intravascular bronchioalveolar” tumor and considered to be of epithelial origin. No definite etiological association has been ascribed to this tumor till now, except an association with oral contraceptives in EHE of liver. Injury and radiation therapy has also shown virtual association in the development of this tumor according to few literatures.<sup>2,5</sup>

EHE is pale tan in color, and lacks the red, hemorrhagic appearance of conventional hemangiomas. Microscopically, it is poorly defined as an infiltrative tumor, characterized by nests and cords of spindle to epithelioid cells embedded in a hyaline, myxoid, chondroid or collagenous stroma. The diagnostic features are the cells that show prominent cytoplasmic vacuoles. Red blood cells may be present within some of these vacuoles (reminiscent of primitive vascular channels). These vacuoles are mucin negative. There is low mitotic activity and mild to moderate pleomorphism. The tumor cells express the full spectrum of immunohistochemical endothelial markers including Factor VIII, CD34 and CD31 and, like epithelioid endothelial cells in general, may also exhibit intense and extensive positive staining for keratin and epithelial membrane antigen. The tumor cells usually do not stain with antibodies to S-100 protein, and desmin.<sup>1,6</sup> Differential diagnoses should be kept in mind during establishing the diagnosis which includes other epithelioid vascular neoplasms, particularly epithelioid hemangioma and angiosarcoma.

Although a standard systemic treatment for malignant EHE has not been fully established, complete surgical excision is strongly recommended if feasible. Multifocal lesions may be difficult to excise and may require radiation, chemotherapy or thermal ablation. The results of a small number of single case report of EHE patients treated with cytotoxic chemotherapy, such as doxorubicin or liposomal formulation, have been far from ideal.<sup>7</sup> As new anticancer agents, antiangiogenic agents and an inhibitor of the tyrosine-kinase, such as bevacizumab, lenalidomide, thalidomide and sorafenib, provide encouraging evidence of the potential benefit in the treatment of those patients with EHE. EHE has an overall mortality rate of about 13%, but this can be as high as 65% for the patients whose tumor arises in liver.<sup>8</sup> The 5-year survival rate for the patient with EHE is only 33.5%,<sup>4</sup> mainly because the condition is often diagnosed late. If our patient would have received chemotherapy or antiangiogenic agents like sorafenib, the patient could have probably lived more than 18 months.

#### 4. Conclusion

It is convincing that EHE carries a grave prognosis due to lack of diagnosis in the early stage however contrast-enhanced CT is helpful in identifying ileal EHE timely in the early stage, even when there is no obvious mass formation. The optimal treatment for this disease is surgical excision if feasible. Surgical excision in combination with antiangiogenic agents is probably a promising therapy in the future.

#### Ethical approval statement

Written informed consent was obtained from the patient for publication of this case report and accompanying images. A copy of the written consent is available for review by the Editor-in-Chief of this journal on request.

#### Conflicts of interest statement

The authors report that there are no conflicts of interest.

#### Funding

None.

#### Contribution

All authors have equal contribution to this article.

#### References

1. Liu Q, Miao J, Lian K, Huang L, Ding Z. Multicentric epithelioid hemangioendothelioma involving the same lower extremity: a case report and review of literature. *Int J Med Sci* 2011;**8**(7):558–63.
2. Sarma NH. Epithelioid hemangioendothelioma of soft tissue after pellet injury. *J Clin Pathol* 1992;**45**(7):640–1.
3. Yasuda S, Hashimoto T, Kanaizumi T, Kuwata H, Matsumoto I, Shiratori T. A case of hemangioendothelioma of the small intestine. *Jpn J Surg* 1989;**19**(1):67–9.
4. Botsford TW, Crowe P, Crocker DW. Tumors of the small intestine. A review of experience with 115 cases including a report of a rare case of malignant hemangioendothelioma. *Am J Surg* 1962;**103**:358–65.
5. Akosa AB, Ali MH. Epithelioid hemangioendothelioma of terminal ileum after therapeutic irradiation. *J Clin Pathol* 1989;**42**:889–90.
6. Naqvi J, Ordóñez NG, Luna MA, Williams MD, Weber RS, El-Naggar AK. Epithelioid hemangioendothelioma of the head and neck: role of podoplanin in the differential diagnosis. *Head Neck Pathol* 2008;**2**:25–30.
7. Mehrabi A, Kashfi A, Fonouni H, Schemmer P, Schmied BM, Hallscheidt P, et al. Primary malignant hepatic epithelioid hemangioendothelioma: a comprehensive review of the literature with emphasis on the surgical therapy. *Cancer* 2006;**107**(9):2108–21.
8. Mainenti PP, Romano L, Contegiacomo A, Romano M, Casella V, Cuccuru V, et al. Rare diffuse peritoneal malignant neoplasms: CT findings in two cases. *Abdom Imaging* 2003;**28**(6):827–30.

#### Open Access

This article is published Open Access at [scimedirect.com](http://scimedirect.com). It is distributed under the [IJSCR Supplemental terms and conditions](#), which permits unrestricted non commercial use, distribution, and reproduction in any medium, provided the original authors and source are credited.