



Since January 2020 Elsevier has created a COVID-19 resource centre with free information in English and Mandarin on the novel coronavirus COVID-19. The COVID-19 resource centre is hosted on Elsevier Connect, the company's public news and information website.

Elsevier hereby grants permission to make all its COVID-19-related research that is available on the COVID-19 resource centre - including this research content - immediately available in PubMed Central and other publicly funded repositories, such as the WHO COVID database with rights for unrestricted research re-use and analyses in any form or by any means with acknowledgement of the original source. These permissions are granted for free by Elsevier for as long as the COVID-19 resource centre remains active.

# FELINE HERPESVIRUS INFECTION

## ABCD guidelines on prevention and management

Etienne Thiry, Diane Addie, Sándor Belák, Corine Boucraut-Baralon, Herman Egberink, Tadeusz Frymus, Tim Gruffydd-Jones, Katrin Hartmann, Margaret J Hosie, Albert Lloret, Hans Lutz, Fulvio Marsilio, Maria Grazia Pennisi, Alan D Radford, Uwe Truyen and Marian C Horzinek



### Virus properties

Feline herpesvirus (FHV) causes feline viral rhinotracheitis. It is distributed worldwide and only one serotype is known, although the virulence can differ among strains.<sup>1</sup> Strain differences can be shown by restriction endonuclease analysis of viral DNA. In the cat, FHV replicates in epithelial cells of both the conjunctiva and the upper respiratory tract, and in neurons. Neuronal infection leads to lifelong latency after primary infection. Feline herpesvirus is related antigenically to canine herpesvirus and phocid herpesviruses 1 and 2, but there is no known cross-species transfer.<sup>1,2</sup>

The virus is susceptible to most commercially available disinfectants, antiseptics and detergents. It is inactivated within 3 h at 37°C, and in 5 mins at 56°C. At 4°C, the virus remains infective for at least 5 months, and at 25°C for about 1 month.<sup>3</sup>

### Epidemiology

The domestic cat is the main host for FHV, but the virus has also been isolated from cheetahs and lions, and antibodies have been detected in pumas. There is no evidence of human infection.

Latent chronic infection is the typical outcome of an acute FHV infection, and intermittent reactivation gives rise to viral shedding in oronasal and conjunctival secretions. Contamination of the environment is not a primary source of transmission, except in catteries. Virus shedding from acutely infected cats and from latently infected cats experiencing reactivation are the two main sources of infection.<sup>4</sup>

Transplacental infection has not been demonstrated in the field. Latently infected queens may transmit FHV to their offspring because parturition and lactation typically induce stress and may lead to viral reactivation and

**Overview** Feline viral rhinotracheitis, caused by feline herpesvirus (FHV), is an upper respiratory tract disease that is often associated with feline calicivirus and bacteria. In most cats, FHV remains latent after recovery, and they become lifelong virus carriers. Stress or corticosteroid treatment may lead to virus reactivation and shedding in oronasal and conjunctival secretions.

**Infection** Sick cats shed FHV in oral, nasal and conjunctival secretions; shedding may last for 3 weeks. Infection requires direct contact with a shedding cat.

**Disease signs** Feline herpesvirus infections cause acute rhinitis and conjunctivitis, usually accompanied by fever, depression and anorexia. Affected cats may also develop typical ulcerative, dendritic keratitis.

**Diagnosis** Samples consist of conjunctival, corneal or oropharyngeal swabs, corneal scrapings or biopsies. It is not recommended that cats recently vaccinated with a modified-live virus vaccine are sampled. Positive PCR results should be interpreted with caution, as they may be produced by low-level shedding or viral latency.

**Disease management** 'Tender loving care' from the owner, supportive therapy and good nursing are essential. Anorexic cats should be fed blended, highly palatable food – warmed up if required. Mucolytic drugs (eg, bromhexine) or nebulisation with saline may offer relief. Broad-spectrum antibiotics should be given to prevent secondary bacterial infections.

Topical antiviral drugs may be used for the treatment of acute FHV ocular disease. The virus is labile and susceptible to most disinfectants, antiseptics and detergents.

### Vaccination recommendations

Two injections, at 9 and 12 weeks of age, are recommended, with a first booster 1 year later. Boosters should be given annually to at-risk cats. For cats in low-risk situations (eg, indoor-only cats), 3-yearly intervals suffice. Cats that have recovered from FHV-associated disease are usually not protected for life against further disease episodes; vaccination of recovered cats is therefore recommended.

**European Advisory Board on Cat Diseases**  
The European Advisory Board on Cat Diseases (ABCD) is a body of experts in immunology, vaccinology and clinical feline medicine that issues guidelines on prevention and management of feline infectious diseases in Europe, for the benefit of the health and welfare of cats. The guidelines are based on current scientific knowledge of the diseases and available vaccines concerned.

An extended version of the feline herpesvirus infection guidelines presented in this article is available at [www.abcd-vets.org](http://www.abcd-vets.org)



European Advisory Board on Cat Diseases  
[www.abcd-vets.org](http://www.abcd-vets.org)  
Corresponding author: Etienne Thiry  
Email: [Etienne.thiry@ulg.ac.be](mailto:Etienne.thiry@ulg.ac.be)



## Latent chronic infection is the typical outcome of an acute FHV infection, and intermittent reactivation gives rise to viral shedding in oronasal and conjunctival secretions.

shedding. Kittens may therefore acquire the virus very early on. The outcome of the infection depends on the level of maternally derived antibodies (MDA) they possess. When high levels are present, kittens are protected against disease and develop subclinical infection leading to latency; in the absence of sufficient MDA, they may develop clinical signs.<sup>4</sup>

In healthy small populations, the prevalence of viral shedding may be lower than 1%, and in large populations, especially when clinical signs are present, it may reach 20%.<sup>5-7</sup> This low prevalence probably reflects the intermittent nature of viral shedding during latency. In shelters, risks are higher: with 4% of shedders entering the shelter, 50% of cats may excrete the virus 1 week later.<sup>8</sup>

### Pathogenesis

The virus enters the cat's body via the nasal, oral or conjunctival routes. It causes a lytic infection of the nasal epithelium with spread to the conjunctivas, pharynx, trachea, bronchi and bronchioles. Lesions are characterised by multifocal epithelial necrosis with neutrophil infiltration and inflammation. A transient viraemia associated with mononuclear cells has been observed exceptionally in neonates or hypothermic kittens, as FHV replication occurs preferentially at lower temperatures.<sup>2</sup>

Viral excretion starts 24 h after infection and lasts for 1–3 weeks. Acute disease resolves within 10–14 days. Some animals may develop chronic lesions in the upper respiratory tract and ocular tissues.

The virus spreads along the sensory nerves and reaches neurons, particularly in the trigeminal ganglia, which are the main sites of latency. Almost all infected cats become life-long carriers. There is no easy diagnostic method to recognise latency, because the viral genome persists in the nucleus of the infected neurons without replication. Reactivation with virus shedding can be induced experimentally by glucocorticoid treatment in approximately 70% of cats. Other reactivating stressors include lactation (40%) and moving into a new environment (18%).<sup>4,8,9</sup>

Some adult cats may develop lesions at the time of viral reactivation. Disease as a consequence of reactivation is referred to as 'recrudescence'.

Conjunctivitis may be associated with corneal ulcers, which may develop into chron-



ic sequestra. Stromal keratitis is a secondary immune-mediated reaction due to the presence of virus in the epithelium or stroma. Damage to the nasal turbinates in acute disease predisposes some cats to chronic rhinitis.<sup>2</sup>

### Immunity

#### Passive immunity acquired via colostrum

Maternally derived antibodies protect kittens against disease during the first weeks of life, but in general levels are low in FHV infections. Antibody may persist for up to 10 weeks, but in some studies about 25% of the kittens became MDA-negative at only 6 weeks of age.<sup>10,11</sup>

#### Active immune response

Natural FHV infection does not result in solid immunity as seen, for example, in feline panleukopenia virus infections. In general, the immune response protects against disease, but not against infection, and mild clinical signs have been observed following reinfection only 150 days after primary infection. Virus neutralising antibody (VNA) titres are often low and rise slowly – they may still be absent 40 days after infection.<sup>12</sup> It is likely that VNA neutralises incoming virus during acute infection, and contributes to antibody-dependent cellular cytotoxicity and antibody-induced complement lysis.<sup>13</sup>

As with other alphaherpesviruses, cell-mediated immunity plays a very important role in protection, since vaccinated cats without detectable antibody are not necessarily susceptible to disease. By contrast, seroconversion has been shown to correlate with protection against virulent FHV challenge.<sup>14</sup> In these cases, antibodies may serve as an indicator of cellular immune responses, since T lymphocytes are required for the maintenance of B lymphocyte function. Since FHV is a pathogen of the respiratory tract, mucosal cellular and humoral responses are significant.<sup>15</sup>

Although a correlation exists between FHV antibodies and protection against clinical signs, there is no test available to predict protection in individual cats.



**In general, the immune response protects against disease, but not against infection, and mild clinical signs have been observed following reinfection only 150 days after primary infection.**

## Clinical signs

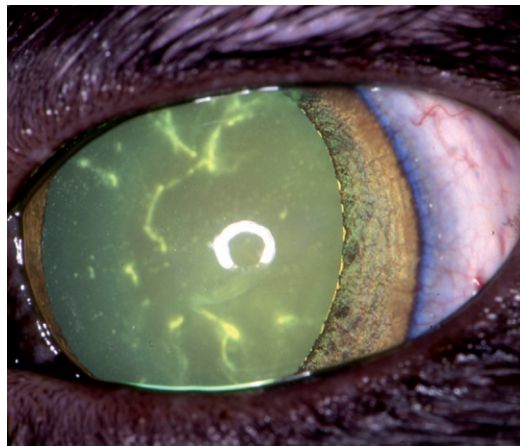
Feline herpesvirus infection typically causes acute upper respiratory and ocular disease (Table 1), which can be particularly severe in young kittens. Erosion and ulceration of mucosal surfaces, rhinitis and conjunctivitis are common; occasionally, corneal dendritic ulcers are seen, which are considered pathognomonic (Fig 1).<sup>16</sup>

Typical clinical signs include fever, depression, anorexia, serous or serosanguineous ocular and/or nasal discharge, conjunctival hyperaemia, sneezing and, less frequently, salivation and coughing (Fig 2). Secondary bacterial infection is common and secretions then become purulent (Fig 3). In particularly susceptible kittens, primary pneumonia and a viraemic state have been identified that can produce severe generalised signs and eventually death (Fig 4).<sup>1</sup>

Less frequently, oral and skin ulcers, dermatitis and neurological signs are observed.<sup>1,17</sup> Abortion is rare and, in contrast to other herpesvirus infections, not a direct consequence of viral replication.

After virus reactivation and recrudescence, some cats may show acute cytolytic disease, as described above; others progress to chronic ocular immune-mediated disease. Experimental evidence suggests that stromal keratitis with corneal oedema, inflammatory cell infiltrates, vascularisation and eventually blindness are the result of this pathogenic mechanism.<sup>16</sup>

Corneal sequestra and eosinophilic keratitis have been linked to the presence of FHV in the cornea and/or blood, but some affected cats have been found to be virus-negative.<sup>18</sup> Viral DNA has also been detected in the aqueous humour of a larger proportion of cats suffering from uveitis, as compared with



**FIG 1** Dendritic ulcerative keratitis is seen in acute infection with feline herpesvirus. It is considered pathognomonic of this ocular infection. Courtesy of Eric Déan

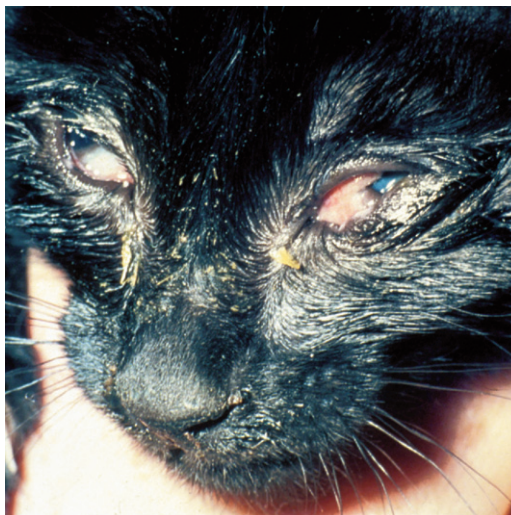
| <b>TABLE 1</b> Feline herpesvirus infection: disease forms, lesions and clinical signs |   |  |
|--|---|--|
| <b>Disease type</b>  | <b>Consequences</b>   | <b>Main clinical manifestations</b>  |
| Classical acute disease (cytolytic disease)  | Rhinitis<br>Conjunctivitis<br>Superficial and deep corneal ulcers, in particular dendritic ulcers | Sneezing<br>Nasal discharge<br>Conjunctival hyperaemia and serous discharge  |
| Atypical acute disease   | Skin disease<br>Viraemia<br>Pneumonia   | Nasal and facial ulcerated and crusting lesions<br>Severe systemic signs (depression, fever, anorexia)<br>Coughing<br>Death (acute death in kittens, 'fading kittens') |
| Chronic disease (immune-mediated disease)  | Stromal keratitis<br>Chronic rhinosinusitis   | Corneal oedema<br>Vascularisation<br>Blindness<br>Chronic sneezing and nasal discharge   |
| FHV-related diseases with no definitive causal association                             | Corneal sequestra<br>Eosinophilic keratitis<br>Neurological disease<br>Uveitis                    |  |

NB. Chronic rhinitis develops as a result of concurrent infection with other agents

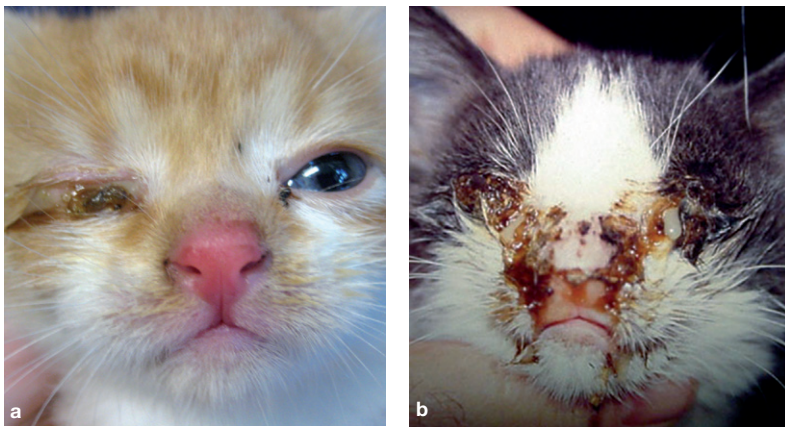
**The virus does not replicate, suggesting that chronic rhinosinusitis is initiated by FHV infection and perpetuated by immune-mediated mechanisms.**

healthy cats, suggesting that FHV may cause uveal inflammation.<sup>19</sup>

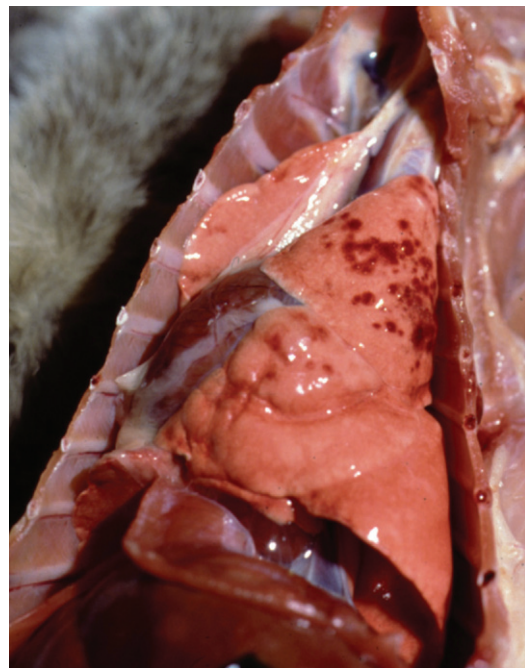
Chronic rhinosinusitis, a frequent cause of sneezing and nasal discharge, has been associated with FHV infection. Viral DNA is detected in some affected cats, but is also found in control animals.<sup>20</sup> The virus does not replicate, suggesting that chronic rhinosinusitis is



**FIG 2** Feline herpesvirus infections cause acute rhinitis and conjunctivitis, usually accompanied by fever, depression and anorexia. Courtesy of The Feline Centre, Bristol, UK



**FIG 3** In kittens with feline herpesvirus infection, respiratory and ocular lesions can be particularly severe, with secondary bacterial infection a common sequela. Courtesy of (a) Faculty of Veterinary Medicine, University of Glasgow, UK; (b) Albert Lloret



**FIG 4** A fatal case of feline herpesvirus infection with pneumonia. Haemorrhagic inflammatory lesions are visible in the apical pulmonary lobe. Courtesy of Merial

initiated by FHV infection and perpetuated by immune-mediated mechanisms. Inflammation and remodelling then lead to the permanent destruction of nasal turbinates and bone, complicated by secondary bacterial infection.<sup>21</sup>

Often, FHV infection occurs in combination with feline calicivirus (FCV) and/or *Chlamydomphila felis*, *Bordetella bronchiseptica*, *Mycoplasma* species, *Staphylococcus* species or *Escherichia coli* infection, causing a multi-agent respiratory syndrome.<sup>1</sup>

## Diagnosis

### Virus and antigen detection

The preferred method for virus detection in biological samples is PCR. Virus isolation is still a valid method for detecting infectious FHV, but is more time consuming. The sensitivity and specificity of the tests differ between laboratories because there is no standardisation.

### Detection of nucleic acid

Conventional PCR, nested PCR and real-time PCR are now routinely used by diagnostic laboratories to detect FHV DNA in conjunctival, corneal or oropharyngeal swabs, corneal scrapings, aqueous humour, corneal sequestra, blood or biopsies.<sup>22-24</sup> Most primers are based on the highly conserved thymidine kinase gene.

Molecular methods seem more sensitive than virus isolation or indirect immunofluorescence [EBM grade I].<sup>22,25</sup>

## EBM ranking used in this article

Evidence-based medicine (EBM) is a process of clinical decision-making that allows clinicians to find, appraise and integrate the current best evidence with individual clinical expertise, client wishes and patient needs (see Editorial on page 529 of this special issue, doi:10.1016/j.jfms.2009.05.001).

This article uses EBM ranking to grade the level of evidence of statements in relevant sections on diagnosis, disease management and control, as well as vaccination. Statements are graded on a scale of I to IV as follows:

- ❖ **EBM grade I** This is the best evidence, comprising data obtained from properly designed, randomised controlled clinical trials in the target species (in this context cats);
- ❖ **EBM grade II** Data obtained from properly designed, randomised controlled studies in the target species with spontaneous disease in an experimental setting;
- ❖ **EBM grade III** Data based on non-randomised clinical trials, multiple case series, other experimental studies, and dramatic results from uncontrolled studies;
- ❖ **EBM grade IV** Expert opinion, case reports, studies in other species, pathophysiological justification. **If no grade is specified, the EBM level is grade IV.**

### Further reading

Roudebush P, Allen TA, Dodd CE, Novotny BJ. Application of evidence-based medicine to veterinary clinical nutrition. *J Am Vet Med Assoc* 2004; 224: 1765-71.

**A positive PCR result may represent low-level shedding or viral latency, and does not necessarily link FHV with the observed clinical signs, although it may predict future recurrence of signs.**



Since minute amounts of viral nucleic acids are detectable by PCR, they may or may not be associated with disease. Positive test results should therefore be interpreted with caution. PCR may even detect viral DNA in scrapings of the cornea and/or tonsils in non-productive infections.<sup>19</sup> Consequently, its diagnostic value may be poor, depending also on the samples analysed (corneal scrapings and biopsies are more frequently positive than conjunctival ones) and the population tested (shelter cats are more likely to test positive than household pets).

Furthermore, PCR detects FHV DNA in modified-live virus vaccines, though it is unknown whether vaccinal strains are detected in recently vaccinated animals and, if so, for how long.<sup>26</sup>

A positive PCR result may represent low-level shedding or viral latency, and does not necessarily link FHV with the observed clinical signs, although it may predict future recurrence of signs. However, when quantitative real-time PCR is used, the virus concentration measured may provide additional information: high viral loads in nasal secretion or tears suggest active replication and FHV involvement in the clinical signs [EBM grade II].<sup>23</sup> If low copy numbers are detected in corneal scrapings, this would indicate a latent infection.

### Virus isolation

Virus isolation – that is, growing FHV in cell culture – is the traditional alternative to PCR. It is less sensitive than PCR but reveals viable virus, not just its DNA. It also allows the simultaneous detection of FCV.

In primary FHV infections, the virus is readily isolated from conjunctival, nasal and pharyngeal swabs or scrapings, or from post-mortem lung samples. When the cause of disease has to be identified in chronic infections, virus isolation is more difficult.

Asymptomatic carriers can be detected by virus isolation, but both positive and negative predictive values of virus isolation are low.<sup>9,19</sup> Samples must be collected before fluorescein or rose bengal stain has been used on the patient.<sup>27</sup> Samples should be sent swiftly or under refrigeration to the laboratory. For these logistical reasons, virus isolation is not used routinely for the diagnosis of FHV infection, despite its sensitivity in cases of acute disease.

### Immunofluorescent antibody assay

Feline herpesvirus-specific proteins can be detected by immunofluorescent antibody (IFA) assay on conjunctival or corneal smears or biopsies. As with virus isolation, fluorescein instillation should be avoided before sampling, as this may give false-positive results. In chronic infections especially, IFA assay is less sensitive than virus isolation or PCR.<sup>25</sup>

For the clinician, PCR diagnosis is more

convenient, because fluorescein can be used and samples can be mailed at ambient temperature.<sup>16</sup> It also allows for simultaneous detection of other feline respiratory and ocular pathogens, especially *C felis* and, less reliably, FCV.<sup>24,28</sup>

### Antibody detection

Antibodies to FHV can be detected in serum, aqueous humour and cerebrospinal fluid by serum neutralisation assay or ELISA.<sup>11,19</sup> Owing to natural infection and vaccination, seroprevalence is high in cats, and the presence of antibodies does not correlate with disease and active infection [EBM grade I].<sup>19</sup> Moreover, serology does not distinguish between infected and vaccinated animals. Neutralising antibodies appear 20–30 days after primary infection, and titres may be low, both in cases of acute and chronic disease. Serology, therefore, is of only limited value in the diagnosis of FHV infection.<sup>16</sup>

## Disease management

### Supportive treatment

Restoration of fluids, electrolytes and acid–base balance (eg, replacement of potassium and bicarbonate losses due to salivation and reduced food intake), preferably by intravenous administration, is required in cats with severe clinical signs. Food intake is extremely important. Many cats will not eat because of loss of their sense of smell or ulcers in the oral cavity. Food should be highly palatable and may be blended and warmed up to increase the flavour. Appetite stimulants (eg, cyproheptadine) may be used. If the cat does not eat for more than 3 days, a feeding tube should be placed.

To prevent secondary bacterial infections, broad-spectrum antibiotics that achieve good penetration into the respiratory tract should be given in all acute cases.

Nasal discharge should be wiped away using saline and a local ointment. Mucolytic drugs (eg, bromhexine) may be helpful. Eye drops or ointments can be administered several times a day. Nebulisation with saline can be used to combat dehydration of the airways. Vitamins are given, though their value is unclear.

### Antiviral therapy

Antiviral drugs recommended for the treatment of acute FHV ocular disease are listed in Table 2. Other drugs have been proposed for the treatment of FHV ocular infections, including bromovinyldeoxyuridine, cidofovir, famciclovir, HPMA (N-[2-hydroxypropyl] methacrylamide), penciclovir, ribavirin, valaciclovir, vidarabine, foscarnet and lactoferrin.<sup>37</sup> The efficacy of these drugs is not supported by published data although recent data demonstrate the efficacy of topical ocular application of cidofovir on primary ocular FHV.<sup>29</sup>

**TABLE 2** Antiviral drugs recommended for the treatment of acute feline herpesvirus ocular disease. The drugs are listed in decreasing order of preference

| Drug                 | Type of drug        | Route of administration  | Efficacy in vitro  | Efficacy in vivo | Published controlled study in vivo | Comments  |
|----------------------|---------------------|--|--|------------------|------------------------------------|---|
| Trifluridine         | Nucleoside analogue | Topical<br>Use every hour for first day and every 4 h thereafter <sup>31</sup>   | Excellent  | ND               | No                                 | Topical treatment of choice in cats with ocular FHV manifestations. Some cats are averse to topical application. Toxic if given systemically <sup>31</sup>  |
| Feline IFN- $\omega$ | Interferon          | Systemic: 1 MU/kg SC sid or eod<br><br>Oral: 50,000–100,000 units daily<br><br>Topical: dilute 10 MU vial in 19 ml 0.9% NaCl and use as eye drops: 2 drops in each eye 5 times a day for 10 days <sup>32</sup> | Yes  | ND               | No                                 | Safe and licensed for use in cats<br><br>No published controlled in vivo studies on the use of this product in FHV infections at the time of writing<br><br>Used along with L-lysine in chronic infections      |
| Human IFN- $\alpha$  | Interferon          | SC high dose<br>PO low dose<br>5–35 units daily  | Yes<br>Yes   | Yes<br>Yes       | Yes<br>Yes                         | Less bioactive than feline interferon. 5–35 units daily reduces clinical disease but not FHV shedding. Used along with L-lysine in chronic infections   |
| L-lysine             | Amino acid          | Oral<br>250 mg bid or 400 mg sid   | Yes  | Yes              | Yes                                | Safe. Reduces spontaneous ocular viral shedding rate in latently infected cats <sup>31,33</sup>   |
| Idoxuridine          | Nucleoside analogue | Topical<br>Use initially every 2–4 h <sup>31</sup>   | Excellent  | ND               | No                                 | Topical treatment for ocular FHV. Difficult to source; pharmacists can formulate a 0.1% ophthalmic solution. Toxic if given systemically  |
| Ganciclovir          | Nucleoside analogue | Topical  | Excellent  | ND               | ND                                 | Topical treatment for ocular FHV. Good in vitro activity against FHV <sup>34</sup>  |
| Aciclovir            | Nucleoside analogue | Topical and oral   | Poor (high doses may be needed to overcome viral resistance) | Some             | Yes                                | Minimum in vitro effect of all the antiherpesvirals; moderate in vivo effect. <sup>34,35</sup> Marked synergy in combination with human IFN- $\alpha$ . <sup>36</sup> Toxic if given systemically <sup>31</sup> |

All treatment recommendations in this table are **EBM grade III** (see box on page 550). ND = not determined, SC = subcutaneously, sid = once daily, bid = twice daily, eod = every other day

### Vaccination

Feline herpesvirus infection is common and may induce severe, and at times fatal, disease. The ABCD therefore considers FHV to be a core vaccine component and recommends that all cats are vaccinated (see box on page 553).

### Disease control in specific situations

#### Shelters

Feline herpesvirus is a particular problem in cat shelters, and management measures to limit or contain the infection are as important as vaccination. Where incoming cats are mixed with residents, high infection rates ensue. As a rule, therefore, newcomers should be quarantined for 2 weeks and kept individually – unless they are from the same household. Shelter design and management should aim to avoid cross-contamination, and new cats should be vaccinated as soon as possible. If there is a

particularly high risk (eg, a recent rhinotracheitis episode), a modified-live virus vaccine is preferable, as it provides earlier protection. If acute respiratory disease is noted, laboratory identification of the agent with differentiation between FHV and FCV can be useful in designing appropriate preventive measures.

#### Breeding catteries

In breeding catteries, FHV can cause major problems. The infection surfaces most often in young kittens before weaning, typically at around 4–8 weeks of age, as MDA wane. The virus source is often the mother whose latent infection (carrier state) has been reactivated following the stress of kitting and lactation.

Clinical signs can be severe and frequently involve all kittens in the litter. Mortality can occur, and some recovered kittens are left with chronic rhinitis. Vaccination of the queen will not prevent this problem, because it will not prevent her from becoming a carrier.

## In breeding catteries, the virus source is often the mother whose latent infection (carrier state) has been reactivated following the stress of kitting and lactation.



However, if she has a high antibody titre, the kittens will benefit from MDA in the colostrum, which should provide protection for the first weeks of life.

Booster vaccinations of queens may therefore be indicated and should be given before mating. Vaccination during pregnancy may be considered only as an exception. Feline herpesvirus vaccines are not licensed for use in pregnant cats and an inactivated product may be preferable in these cases.

Breeding management plays a crucial role in

controlling FHV in catteries. Queens should kitten in isolation, and their litters should not mix with those of other cats until they have been fully vaccinated. Early vaccination should be considered for litters from queens that have had infected litters previously. The earliest age for which FHV vaccines are licensed is 6 weeks, but vaccination from around 4 weeks of age may be considered (kittens are already immunocompetent at that age), with repeated injections every 2 weeks until the normal primary vaccination course is started.

### Vaccination recommendations

#### General considerations

Feline herpesvirus vaccines act by inducing both antibodies and cellular immunity. In common with other localised respiratory tract infections, protection against clinical signs is not complete (soon after vaccination, an approximately 90% reduction in clinical scores to experimental challenge has been achieved).<sup>2</sup> Less protection is expected in situations of extreme challenge and in the face of immunosuppression. There is no evidence of FHV variants that would escape vaccinal protection.

Vaccination protects against disease, but not necessarily against infection. However, it can reduce virus excretion upon infection.<sup>2</sup>

All FHV vaccines currently marketed are divalent products and include FCV components (in some countries) or, more commonly, cocktails of other antigens. Both modified-live and inactivated parenteral vaccines are available. Subunit FHV vaccines and modified-live intranasal vaccines are no longer available in Europe.

There is no reason to choose any particular vaccine over another for routine vaccination, particularly as they are all based on the same single FHV serotype. Modified-live vaccines retain some virulence and may induce clinical signs if administered incorrectly (eg, by accidental aerosolisation or spillage on the skin).

Post-vaccination serology is of limited value for predicting protection. Methodological issues complicate titre comparisons, and cats that have not seroconverted have nevertheless been found to be protected.<sup>14,30</sup> Following exposure to field virus, vaccinated cats usually show an anamnestic response.

#### Primary course

The ABCD recommends that all kittens are vaccinated against FHV. Maternal immunity can interfere with the response, and the primary course is therefore usually started at around 9 weeks of age, although some vaccines are licensed for earlier use. Kittens should receive a second vaccination 2–4 weeks later, at around 12 weeks of age. This protocol has been developed to ensure optimal protection.

Adult or adolescent cats of an uncertain vaccination status should also receive two FHV vaccinations at an interval of 2–4 weeks, irrespective of the vaccine type. This is in contrast to certain other viral infections (eg, feline panleukopenia), where a single vaccination is acceptable.

#### Booster vaccinations

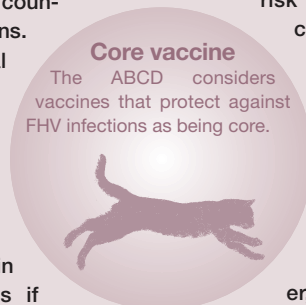
In assessing currently available scientific evidence, the ABCD recommends that boosters are given at annual intervals to protect individual cats against FHV field infection. An informed decision should be taken on the basis of a risk–benefit analysis; annual boosters are particularly important for cats in high-risk situations or environments. However, for cats in low-risk situations (eg, indoor-only cats without contact with other cats), 3-yearly intervals are recommended.

Experimental studies and serological data from the field indicate that immunity against FHV lasts longer than 1 year in most vaccinated cats [EBM grade II].<sup>38</sup> However, for many cats this is not the case. In the field, most cats tested have either had titres against FCV and FPV, or have shown an anamnestic response after booster, but about 30% of the population had no detectable antibody against FHV and about 20% failed to show an anamnestic response after booster vaccinations.<sup>14,30</sup> Assessment of the duration of immunity is complicated: vaccination does not provide complete protection even shortly after vaccination, and the degree of protection decreases with time.

If booster vaccinations have lapsed, a single injection suffices if the interval since the last vaccination is less than 3 years; if it is more than 3 years, two vaccinations are recommended.

Boosters using FHV products from another manufacturer are acceptable.

Cats that have recovered from feline viral rhinotracheitis may not be protected against new disease episodes. Because the cause of the clinical signs will not have been identified, and the cat may experience infections with other respiratory tract pathogens, vaccination of recovered cats is also recommended.





**Immunocompromised cats**

Vaccines cannot immunise animals with a compromised immune function, such as those with systemic disease, virus-induced immunodeficiency, nutritional deficits or combined genetic immunodeficiency, those receiving immunosuppressive drug therapy, or experiencing prolonged stress. Although such patients should preferably be shielded from exposure to pathogens, this may be unattainable, and hence vaccination is considered. Based on safety considerations, inactivated preparations are recommended in this situation.

❖ **Feline leukaemia virus (FeLV) or feline immunodeficiency virus (FIV) positive cats**

Healthy FeLV- or FIV-positive cats should be protected against rhinotracheitis. As indoor confinement is often impossible, vaccination is required. Concerns that vaccination may contribute to FIV disease progression are outweighed by the benefits of protection against upper respiratory disease; indeed, other infections may also contribute to FIV progression.

Vaccination should be considered for

**Vaccination should be considered for FIV-seropositive cats with a history of respiratory problems, provided the animals are in a stable condition.**



FIV-seropositive cats with a history of respiratory problems, provided the animals are in a stable condition. For sick cats with FIV-related disease, vaccination is discouraged, as in any systemically ill cat.

- ❖ **Cats with chronic disease** Booster vaccination should be continued in (often elderly) cats with stable chronic medical conditions, such as hyperthyroidism and renal disease.
- ❖ **Cats receiving corticosteroids or other immunosuppressive drugs** Depending on dosage and length of treatment, corticosteroids cause immune suppression, and concurrent use of corticosteroids at the time of vaccination should be avoided.

**KEY POINTS**

- ❖ Feline viral rhinotracheitis is caused by feline herpesvirus (FHV).
- ❖ In most cats, FHV remains latent after recovery, and they become lifelong virus carriers.
- ❖ Due to the highly contagious nature of FHV, infection and disease are common in multi-cat situations such as boarding and breeding catteries, shelters and multi-cat households.
- ❖ FHV infections cause acute rhinitis and conjunctivitis, usually accompanied by fever, depression and anorexia.
- ❖ Affected cats may also develop typical ulcerative, dendritic keratitis.
- ❖ Positive PCR results should be interpreted with caution, as they may be due to low-level shedding or viral latency.
- ❖ Supportive therapy and good nursing care are essential.
- ❖ Broad-spectrum antibiotics should be given to prevent secondary bacterial infections.
- ❖ Topical antiviral drugs may be used for the treatment of acute FHV ocular disease.
- ❖ Two vaccine injections, at 9 and 12 weeks of age, are recommended, and a first booster 1 year later.
- ❖ Adult cats with an unknown or uncertain vaccination status should also receive two doses at an interval of 2–4 weeks.
- ❖ Boosters should be given at yearly intervals to at-risk cats.
- ❖ For cats in low-risk situations (eg, indoor-only cats), 3-yearly booster intervals suffice.

**Acknowledgements**

The European Advisory Board on Cat Diseases (ABCD) is indebted to Dr Karin de Lange for her judicious assistance in organising this special issue, her efforts at coordination, and her friendly deadline-keeping. The tireless editorial assistance of Christina Espert-Sanchez is gratefully acknowledged. The groundwork for this series of guidelines would not have been possible without financial support from Merial. The ABCD particularly appreciates the support of Dr Jean-Christophe Thibault, who respected the team's insistence on scientific independence.

**References**

- 1 Gaskell R, Dawson S, Radford A. Feline respiratory disease. In: Greene CE, ed. *Infectious disease of the dog and cat*. Missouri: WB Saunders, 2006: 145–54.
- 2 Gaskell R, Dawson S, Radford A, Thiry E. Feline herpesvirus. *Vet Res* 2007; **38**: 337–54.
- 3 Pedersen NC. Feline herpesvirus type 1 (feline rhinotracheitis virus). In: Appel MJ, ed. *Virus infections of carnivores*. Amsterdam: Elsevier, 1987: 227–37.
- 4 Gaskell RM, Povey RC. Transmission of feline viral rhinotracheitis. *Vet Rec* 1982; **111**: 359–62.
- 5 Coutts AJ, Dawson S, Willoughby K, Gaskell RM. Isolation of feline respiratory viruses from clinically healthy cats at UK cat shows. *Vet Rec* 1994; **135**: 555–56.
- 6 Binns SH, Dawson S, Speakman AJ, et al. A study

- of feline upper respiratory tract disease with reference to prevalence and risk factors for infection with feline calicivirus and feline herpesvirus. *J Feline Med Surg* 2000; **2**: 123–33.
- 7 Helps CR, Lait P, Damhuis A, et al. Factors associated with upper respiratory tract disease caused by feline herpesvirus, feline calicivirus, *Chlamydomphila felis* and *Bordetella bronchiseptica* in cats: experience from 218 European catteries. *Vet Rec* 2005; **159**: 669–73.
  - 8 Pedersen NC, Satop R, Foley JE, Poland AM. Common virus infections in cats, before and after being placed in shelters, with emphasis on feline enteric coronavirus. *J Feline Med Surg* 2004; **6**: 83–8.
  - 9 Gaskell RM, Povey RC. Experimental induction of feline viral rhinotracheitis (FVR) virus re-excretion in FVR-recovered cats. *Vet Rec* 1977; **100**: 128–33.
  - 10 Johnson RP, Povey RC. Vaccination against feline viral rhinotracheitis in kittens with maternally derived feline viral rhinotracheitis antibodies. *J Am Vet Med Assoc* 1985; **186**: 149–52.
  - 11 Dawson DA, Carman J, Collins J, Hill S, Lappin MR. Enzyme-linked immunosorbent assay for detection of feline herpesvirus 1 IgG in serum, aqueous humour, and cerebrospinal fluid. *J Vet Diagn Invest* 1998; **10**: 315–19.
  - 12 Gaskell RM, Povey RC. The dose response of cats to experimental infection with feline viral rhinotracheitis virus. *J Comp Pathol* 1979; **89**: 179–91.
  - 13 Wardley RC, Rouse BT, Babiuk LA. Observations on recovery mechanisms from feline viral rhinotracheitis. *Can J Comp Med* 1976; **40**: 257–64.
  - 14 Lappin MR, Andrews J, Simpson D, Jensen WA. Use of serologic tests to predict resistance to feline herpesvirus 1, feline calicivirus, and feline parvovirus infection in cats. *J Am Vet Med Assoc* 2002; **220**: 38–42.
  - 15 Lappin MR, Sebring RW, Porter M, Radecki SJ, Veir J. Effects of a single dose of an intranasal feline herpesvirus 1, calicivirus, and panleukopenia vaccine on clinical signs and virus shedding after challenge with virulent feline herpesvirus 1. *J Feline Med Surg* 2006; **8**: 158–63.
  - 16 Maggs DJ. Update on pathogenesis, diagnosis, and treatment of feline herpesvirus type 1. *Clin Tech Small Anim Pract* 2005; **20**: 94–101.
  - 17 Hargis AM, Ginn PE. Ulcerative facial and nasal dermatitis and stomatitis in cats associated with feline herpesvirus-1. *Vet Dermatol* 1999; **10**: 267–74.
  - 18 Nasisse MP, Glover TL, Moore CP, Weigler BJ. Detection of feline herpesvirus 1 DNA in corneas of cats with eosinophilic keratitis or corneal sequestration. *Am J Vet Res* 1998; **59**: 856–58.
  - 19 Maggs DJ, Lappin MR, Reif JS, et al. Evaluation of serologic and viral detection methods for diagnosing feline herpesvirus-1 infection in cats with acute respiratory tract or chronic ocular disease. *J Am Vet Med Assoc* 1999; **214**: 502–7.
  - 20 Henderson SM, Bradley K, Day MJ, et al. Investigation of nasal disease in the cat – a retrospective study of 77 cases. *J Feline Med Surg* 2004; **6**: 245–57.
  - 21 Johnson LR, Foley JE, De Cock HE, Clarke HE, Maggs DJ. Assessment of infectious organisms associated with chronic rhinosinusitis in cats. *J Am Vet Med Assoc* 2005; **227**: 579–85.
  - 22 Weigler BJ, Babineau A, Sherry B, Nasisse MP. High sensitivity polymerase chain reaction assay for active and latent feline herpesvirus-1 infections in domestic cats. *Vet Rec* 1997; **140**: 335–38.
  - 23 Vögtlin A, Fraefel C, Albini S, et al. Quantification of feline herpesvirus 1 DNA in ocular fluid samples of clinically diseased cats by real-time TaqMan PCR. *J Clin Microbiol* 2002; **40**: 519–23.
  - 24 Marsilio F, Di Martino B, Aguzzi I, Meridiani I. Duplex polymerase chain reaction assay to screen for feline herpesvirus-1 and *Chlamydomphila* spp. in mucosal swabs from cats. *Vet Res Commun* 2004; **28**: 295–98.
  - 25 Burgesser KM, Hotaling S, Schiebel A, Ashbaugh SE, Roberts SM, Collins JK. Comparison of PCR, virus isolation, and indirect fluorescent antibody staining in the detection of naturally occurring feline herpesvirus infections. *J Vet Diagn Invest* 1999; **11**: 122–26.
  - 26 Maggs DJ, Clarke HE. Relative sensitivity of polymerase chain reaction assays used for detection of feline herpesvirus type 1 DNA in clinical samples and commercial vaccines. *Am J Vet Res* 2005; **66**: 1550–55.
  - 27 Storey ES, Gerding PA, Scherba G, Schaeffer DJ. Survival of equine herpesvirus-4, feline herpesvirus-1, and feline calicivirus in multidose ophthalmic solutions. *Vet Ophthalmol* 2002; **5**: 263–67.
  - 28 Helps C, Reeves N, Egan K, Howard P, Harbour D. Detection of *Chlamydomphila felis* and feline herpesvirus by multiplex real-time PCR analysis. *J Clin Microbiol* 2003; **41**: 2734–36.
  - 29 Fontenelle JP, Powell CC, Veir JK, Radecki SV, Lappin MR. Effect of topical ophthalmic application of cidofovir on experimentally induced primary ocular feline herpesvirus-1 infection in cats. *Am J Vet Res* 2008; **69**: 289–93.
  - 30 Mouzin DE, Lorenzen MJ, Haworth JD, King VL. Duration of serologic response to three viral antigens in cats. *J Am Vet Med Assoc* 2004; **224**: 61–6.
  - 31 Maggs DJ. Update on the diagnosis and management of feline herpesvirus-1 infection. In: August JR, ed. Consultations in feline internal medicine. Vol 4. Philadelphia: WB Saunders, 2001: 51–61.
  - 32 Jongh O. A cat with herpetic keratitis (primary stage of infection) treated with feline omega interferon. In: de Mari K, ed. Veterinary interferon handbook. Carros: Virbac, 2004: 138–47.
  - 33 Maggs DJ, Nasisse MP, Kass PH. Efficacy of oral supplementation with L-lysine in cats latently infected with feline herpesvirus. *Am J Vet Res* 2003; **64**: 37–42.
  - 34 Van der Meulen K, Garre B, Croubels S, Nauwynck H. In vitro comparison of antiviral drugs against feline herpesvirus 1. *BMC Vet Res* 2006; **2**: 13.
  - 35 Williams DL, Robinson JC, Lay E, Field H. Efficacy of topical aciclovir for the treatment of feline herpetic keratitis: results of a prospective clinical trial and data from in vitro investigations. *Vet Rec* 2005; **157**: 254–57.
  - 36 Weiss RC. Synergistic antiviral activities of acyclovir and recombinant human leukocyte (alpha) interferon on feline herpesvirus replication. *Am J Vet Res* 1989; **50**: 1672–77.
  - 37 Malik R, Lessels NS, Webb S, et al. Treatment of feline herpesvirus-1 associated disease in cats with famciclovir and related drugs. *J Feline Med Surg* 2009; **11**: 40–8.
  - 38 Scott FW, Geissinger CM. Long-term immunity in cats vaccinated with an inactivated trivalent vaccine. *Am J Vet Res* 1999; **60**: 652–58.