

# Kirschner wire fixation versus suture anchor technique for mallet finger

## A meta-analysis

Yongjing Huang, Ke Wu, Haifeng Shi\*<sup>ID</sup>, Yong Shen\*, Zhihai Zhang, Yongjun Rui

### Abstract

**Purpose:** Though the previous studies had described various surgical techniques for the treatment of mallet finger injuries, consensus on which technique was the most effective and appropriate surgical methods had not yet reached. This review aimed to systematically compare the effectiveness and safety of the treatment for mallet finger injuries via Kirschner wire fixation versus suture anchor technique to recommend an optimum option.

**Methods:** All literatures published until December 31, 2019 compared Kirschner wire fixation versus suture anchor technique to treat mallet finger were acquired through a comprehensive search in multiple databases. A meta-analysis was performed by the Cochrane Collaboration's RevMan 5.3 software.

**Results:** A total of 8 trials with 362 cases consisted of 4 randomized controlled trials and 4 prospective studies. The results suggested that the groups treated with kirschner wire fixation experienced more significant advantage in less complications than suture anchor groups ( $P < .05$ ). On the other hand, no significant differences were found in terms of the total active range motion of the distal interphalangeal joint, the average distal interphalangeal joint extensor lag, Visual Analogue Scale scores, recurrence, as well as functional assessment at the final follow-up ( $P > .05$ , respectively) between the two surgical procedures.

**Conclusions:** No obvious superiority were shown for the effectiveness between the two surgical interventions based on the above results. But in view of the less economic spending and complications, Kirschner wire fixation should be a better alternative relative to the suture anchor technique for inevitable surgical treatment of mallet finger lesions. However, a prudent attitude is still necessary to choose the two operative managements before a large sample and high-quality randomized controlled trials had been performed.

**Abbreviations:** CBRG = cochrane back review group, CI = confidence interval, DIP = distal interphalangeal, FEM = fixed-effects model, MD = mean difference, NOQAS = newcastle ottawa quality assessment scale, OR = odds ratio, PIP = proximal interphalangeal, RCTs = randomized controlled trials, REM = random-effects model, RoB = risk of bias, TAM = total active motion, VAS = visual analogue scale.

**Keywords:** Kirschner wire fixation, mallet finger, meta-analysis, outcomes, suture anchor technique

Editor: Atul Dwivedi.

This article does not contain any studies with human participants or animals performed by any of the authors.

The authors declare that they have no conflict of interest.

The datasets generated during and/or analyzed during the current study are publicly available.

Department of Hand Surgery, Wuxi 9th People's Hospital Affiliated to Soochow University, Wuxi, China.

\* Correspondence: Haifeng Shi, Yong Shen, Department of hand surgery, Wuxi 9th People's Hospital Affiliated to Soochow University, Wuxi, China (e-mail: h13771068703@163.com, 2315546143@qq.com).

Copyright © 2021 the Author(s). Published by Wolters Kluwer Health, Inc. This is an open access article distributed under the terms of the Creative Commons Attribution-Non Commercial License 4.0 (CCBY-NC), where it is permissible to download, share, remix, transform, and buildup the work provided it is properly cited. The work cannot be used commercially without permission from the journal.

How to cite this article: Huang Y, Wu K, Shi H, Shen Y, Zhang Z, Rui Y. Kirschner wire fixation versus suture anchor technique for mallet finger: a meta-analysis. *Medicine* 2021;100:11(e24996).

Received: 16 May 2020 / Received in final form: 10 February 2021 / Accepted: 11 February 2021

<http://dx.doi.org/10.1097/MD.00000000000024996>

## 1. Introduction

Mallet finger injuries which usually resulted from a traumatic zone I lesion of the extensor tendon with either tendon rupture or bony avulsion at the base of the distal phalanx leading to a limited active extension of distal interphalangeal joint (DIP) commonly happened in sports.<sup>[1,2]</sup> Which is also called “drop finger,” as a result of consequences of the lesion<sup>[3]</sup> or “baseball finger,” in the light of the mechanism of injury.<sup>[4]</sup> The injury mechanism is an axial force applied to a straight digit tip, then followed by passive extreme DIP hyperextension or hyperflexion.<sup>[5,6]</sup> Previous studies found the prevalence is 5.6% of all tendinous lesions in hand and wrist injuries.<sup>[7]</sup> Most mallet injuries are closed, the terminal extensor tendon may also be disrupted owing to crash injuries or lacerations in the dorsal aspect of the distal phalanx.<sup>[8]</sup> Mallet injuries were usually classified as “bony mallet,” and “soft-tissue mallet or tendinous mallet finger” according to whether or not combined with avulsion fracture occurs at the insertion of the extensor tendon on the distal phalanx.<sup>[5]</sup> Classification based on the Doyle system<sup>[9]</sup> including 4 types were usually recommended in clinical practice: type 1, closed injury (with or without avulsion fracture;

type 2, open injury with tendon laceration; type 3, open injury with tendon substance and soft tissue loss; type 4, mallet fracture, which is further subdivided into three types: transphyseal fracture in children (type A), hyperflexion injury with involvement of 20% to 50% of the articular surface (type B), and hyperextension injury involving more than 50% of the articular surface (type C). What's more, Wehbe et al<sup>[10]</sup> proposed another frequently-used classification system which described the severity of the injuries: no distal interphalangeal joint subluxation (type 1), distal interphalangeal joint subluxation (type 2), and physeal or epiphyseal injuries (type 3), while all injuries are further subdivided based on the involvement of articular surface: less than 30% (subtype A), 30% to 60% (subtype B), and more than 60% (subtype C). Mallet finger injuries can be complicated by development of osteoarthritis at the DIP joint or possibly hyperextension (swan-neck) deformity at the level of the proximal interphalangeal (PIP) joint if without well-timed and appropriate interventions.<sup>[11]</sup> It is critical to restore active DIP joint extension and prevent a swan neck deformity for mallet finger treatment. As far as the current mainstream view, conservative management such as finger splints could treat most closed mallet finger injuries successfully. However, surgical options is necessary for open injuries, or mallet finger with further subluxation of the DIP joint, and moreover, patients without good compliance during the continuous splint immobilization phase.<sup>[12–14]</sup> Closed or open reduction with Kirschner wire fixation, or suture anchor technique was commonly used for surgical managements to treat mallet fingers in clinical practice. Other methods included tension band wiring, hook plate or pullout wire technique and so on. As far as we know, although several previous studies compared Kirschner wire fixation versus suture anchor technique to treat mallet finger have been reported, it's still inconsistent for which is a better choice to treat mallet finger injuries. Therefore, this meta-analysis was performed to collect more reliable evidence to comprehensively compare the two different surgical techniques for a consensus.

## 2. Materials and methods

### 2.1. Search strategy

All articles referred to comparison of Kirschner wire fixation versus suture anchor technique to treat mallet finger published in English or Chinese were electronically retrieved from PubMed, Cochrane Central Registry, Web of Science, MEDLINE, BIOSIS, Wan Fang and CNKI EMBASE. Cochrane databases and reference lists in the selected studies were manually screened. The combinations of the following keywords were used during retrieval: (mallet finger or tendinous mallet finger or bony mallet finger) and (Kirschner wire or pinning) and (micro suture anchor).

### 2.2. Inclusion criteria

Studies were included if they met the following criteria:

- 1) participants subjected to surgical treatment and diagnosed with tendinous mallet finger or bony mallet finger.
- 2) randomized or non-randomized controlled clinical studies.
- 3) all studies compared Kirschner wire fixation versus suture anchor technique.
- 4) minimum sample size of 10 and follow-up period of 4 months.

**Table 1**

### Risk of bias assessment of the randomized studies by the Cochrane Back Review Group (CBRG).

- A. Was the method of randomization adequate?
- B. Was the treatment allocation concealed?
- C. Were the groups similar at baseline regarding the most important prognostic factors?
- D. Was the patient blinded to the intervention?
- E. Was the care provider blinded to the intervention?
- F. Was the outcome assessor blinded to the intervention?
- G. Were co-interventions avoided or similar?
- H. Was adherence acceptable in all groups?
- I. Was the dropout rate described and acceptable?
- J. Was the timing of the outcome assessment in all groups similar?
- K. Did the analysis include an intention-to-treat analysis?

### 2.3. Exclusion criteria

Literatures were excluded if they met the following criteria:

- 1) open mallet finger, chronic lesions, or combined with infection, tumour, deformity, osteoporosis or rheumatoid arthritis.
- 2) tendinous injuries other than mallet fingers.
- 3) duplicate studies, conference abstracts, review articles, case reports, biomechanical and cadaveric studies.

### 2.4. Data extraction

Two reviewers (YH and KW) independently extracted the relevant data from the reports. The extracted data described the characteristics of the investigations regarding study design, mean age, gender, sample size, and follow-up period. The outcomes pooled in this analysis included complications, recurrence, Visual Analogue Scale (VAS) scores, DIP joint extensor lag angle, total active range motion of DIP joint, the choiceness rate according to Crawford criteria<sup>[15]</sup> and Total Active Motion (TAM) System<sup>[16]</sup> as functional assessment at the final follow-up. Disagreements were resolved by a third referee.

### 2.5. Risk of bias assessment

The quality of the studies were estimated by the two independent authors. The randomized controlled studies were assessed in the light of the Cochrane Back Review Group (CBRG)<sup>[17]</sup> (Table 1). If the study met at least six of the eleven criteria, the study was regarded as low risk of bias (RoB), otherwise the study was labeled as high RoB. While the quality of non-randomized controlled trials and cohort studies were assessed according to the Newcastle Ottawa Quality Assessment Scale (NOQAS)<sup>[18]</sup> (Table 2). A maximum of 9 points is allocated for quality of selection (four points), comparability (two points), exposure (3 points), or outcome of study participants (three points). If the study met at least 5 points out of the nine criteria, the study was considered to have low RoB. Conversely, the study was labeled as high RoB with only four or less met the nine criteria.

### 2.6. Statistical analysis

RevMan 5.3 software (Cochrane IMS) was performed for the statistical analysis. The results were expressed in terms of odds

**Table 2****The Newcastle Ottawa Quality Assessment Scale (NOQAS).**

## Case Control Studies

## Selection

1) Is the case definition adequate?

- a) Yes, with independent validation<sup>1</sup>
- b) Yes, eg record linkage or based on self reports
- c) No description

2) Representativeness of the cases

- a) Consecutive or obviously representative series of cases
- b) Potential for selection biases or not stated

3) Selection of Controls

- a) Community controls
- b) Hospital controls
- c) No description

4) Definition of Controls

- a) no history of disease (endpoint)
- b) no description of source

## Comparability

1) Comparability of cases and controls on the basis of the design or analysis

- a) study controls for \_\_\_\_\_ (Select the most important factor.)
- b) study controls for any additional factor —(This criteria could be modified to indicate specific control for a second important factor.)

## Exposure

1) Ascertainment of exposure

- a) secure record (e.g., surgical records)
- b) structured interview where blind to case/control status
- c) interview not blinded to case/control status
- d) written self report or medical record only
- e) no description

2) Same method of ascertainment for cases and controls

- a) Yes
  - b) No
- 3) Non-Response rate
- a) same rate for both groups
  - b) non respondents described
  - c) rate different and no designation

## Cohort Studies

## Selection

1) Representativeness of the exposed cohort

- a) truly representative of the average \_\_\_\_\_ (describe) in the community
- b) somewhat representative of the average \_\_\_\_\_ in the community
- c) selected group of users eg nurses, volunteers
- d) no description of the derivation of the cohort

2) Selection of the non exposed cohort

- a) drawn from the same community as the exposed cohort
- b) drawn from a different source
- c) no description of the derivation of the non exposed cohort

3) Ascertainment of exposure

- a) secure record (e.g., surgical records)
- b) structured interview
- c) written self report
- d) no description

4) Demonstration that outcome of interest was not present at start of study

- a) yes<sup>1</sup>
- b) no

## Comparability

1) Comparability of cohorts on the basis of the design or analysis

- a) study controls for \_\_\_\_\_ (select the most important factor)
- b) study controls for any additional factor \_ (This criteria could be modified to indicate specific control for a second important factor.)

## Outcome

1) Assessment of outcome

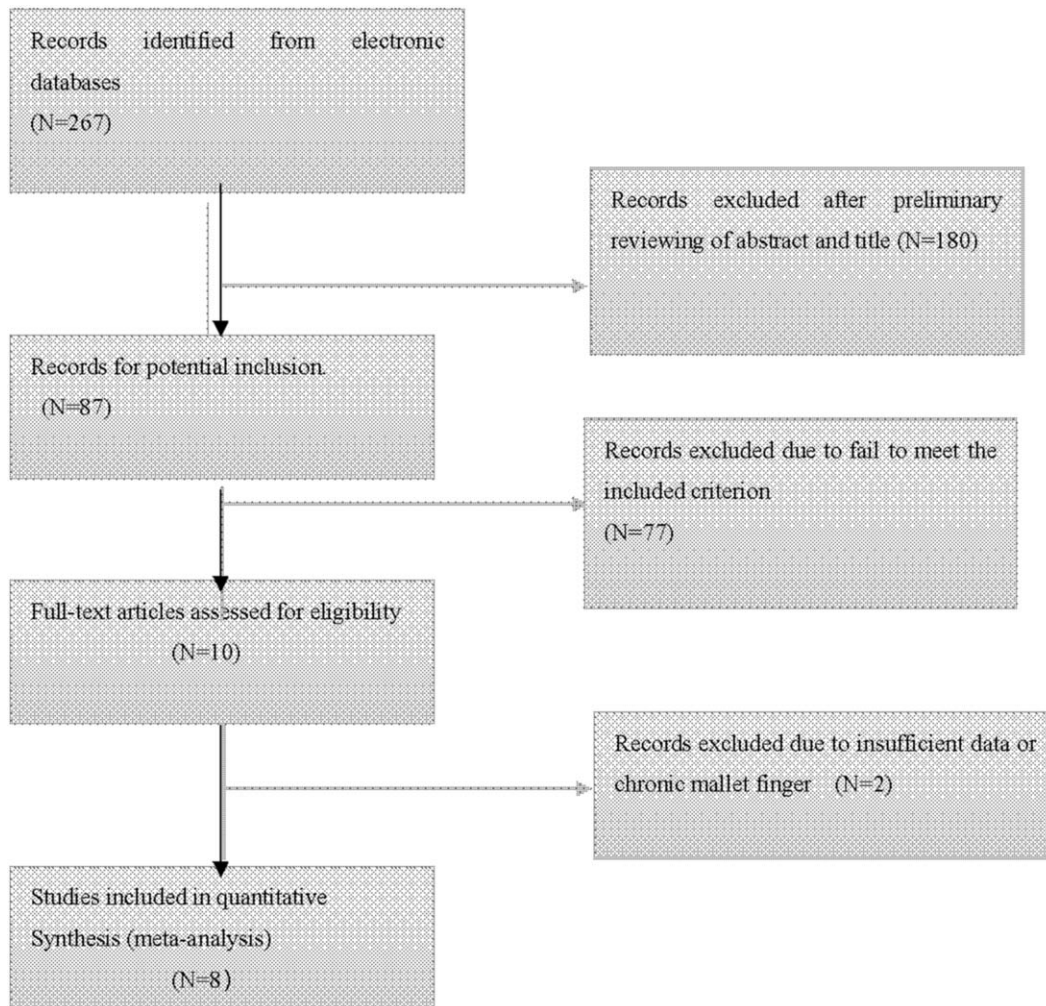
- a) independent blind assessment
- b) record linkage<sup>1</sup>
- c) self report
- d) no description

2) Was follow-up long enough for outcomes to occur

- a) yes (select an adequate follow up period for outcome of interest)
- b) no

3) Adequacy of follow up of cohorts

- a) complete follow up - all subjects accounted for
- b) subjects lost to follow up unlikely to introduce bias - small number lost > \_\_\_\_ % (select an adequate %) follow up, or description provided of those lost)
- c) follow up rate < \_\_\_\_% (select an adequate %) and no description of those lost
- d) no statement



**Figure 1.** The process of searching relevant literature.

ratio (OR) and 95% confidence interval (95% CI) for dichotomous outcomes and mean difference (MD) and 95% CI for continuous outcomes. When the same continuous outcomes were measured in different scales, standardized mean difference and 95% CI were calculated. Heterogeneity was estimated by the  $I^2$  statistic. If the value of  $I^2 > 50\%$ , the Random-Effects Model (REM) was employed, the source of heterogeneity was investigated by a subgroup analysis and a sensitivity analysis. Alternately, the Fixed-Effects Model (FEM) was applied. The sensitivity analysis was performed by rejecting each article with high statistical heterogeneity.<sup>[19]</sup> A  $P < .05$  was defined as statistically significant.

### 3. Results

#### 3.1. Search results

The detailed search process and relevant results based on the strategy described above was shown in Figure 1. A total of 8 Chinese scholars performed related research<sup>[20–27]</sup> that enrolled 362 patients met the inclusion criteria. Which included 183 cases for Kirschner wire fixation group and 179 cases for suture anchor group. All of the above literatures recruited Chinese. Of

which, 4 articles<sup>[20,21,24,26]</sup> were randomized studies and 4 articles<sup>[22,23,25,27]</sup> were prospective cohort studies. Participants included of all studies had at least four-month follow-up. The concrete characteristics of the included studies were summarized in Table 3.

#### 3.2. Study quality assessment

According to the CBRG, The methodological quality score of four randomized controlled trials (RCTs) had quality scores of 6–8 (low RoB). The quality of non-randomized trials were assessed by NOQAS. Three of the nonrandomized studies ranged from 5 to 7 points (low RoB) but the remaining one study<sup>[23]</sup> was four points (high RoB), (shown in Table 4). In general, the quality of included studies was moderate to high.

#### 3.3. Meta-analysis results

**3.3.1. Complications.** A total of 8 studies<sup>[20–27]</sup> including 183 cases for Kirschner wire fixation group and 179 cases for suture anchor group reported complications in this meta-analysis. Among them, one study<sup>[20]</sup> included 24 patients with 25 mallet finger injuries for Kirschner wire fixation group and 24 patients



**Table 3**  
The concrete characteristics of the included studies.

Study ID	Study design	Case		Sex (M/F <sup>*</sup> )		Mean age (yr)		Bony mallet finger?	Follow-up (month)
		K-W <sup>*</sup>	S-A <sup>*</sup>	K-W	S-A	K-W	S-A		
Leng, 2014	RCT <sup>*</sup>	24	24	UA <sup>*</sup>	UA <sup>*</sup>	UA <sup>*</sup>	UA <sup>*</sup>	Yes	4
Du, 2019	RCT <sup>*</sup>	33	33	19/14	21/12	39.47 ± 3.52	38.05 ± 4.11	No <sup>*</sup>	12
Wang, 2017	PCS <sup>*</sup>	19	21	UA <sup>*</sup>	UA	UA	UA	Both <sup>*</sup>	6
Gu, 2018	PCS	16	17	13/3	10/7	42.3	38.5	No	13.1
Zheng, 2018	RCT	20	21	UA	UA	UA	UA8	Both	12.3
Xing, 2013	PCS	27	25	16/11	17/8	35.7	36.9	Both	12
Hu, 2013	RCT	12	12	10/2	7/5	UA	UA	Yes	8
Zhang, 2018	PCS	32	26	UA	UA	UA	UA	Yes	9.6

\*K- W = Kirschner-Wire Group.  
 \*S-A = Suture-Anchor Group.  
 \*No = only tendinous mallet finger.  
 \*Both = both bony and tendinous mallet finger.  
 \*UA = data are unavailable.  
 \*M/F = male/female.  
 \*PCS = Prospective Cohort Study.  
 \*RCT = Randomized Controlled Trials.

with 26 mallet finger injuries for suture anchor group. Postoperative nail deformity, infection, skin necrosis, and suture exposure were the most regular complications, while mallet finger recurrence, skin breakdown, arthritis, tendon rupture, and swan neck deformity were comparatively rare or unmentioned in above literatures. All complications described in all researches were included in this meta-analysis. The pooled results showed no significant heterogeneity was detected from these trials ( $I^2=19\%$ ;  $P=.28$ ), the FEM was adopted and the statistical incidence of total complications suggested patients treated with Kirschner wire fixation had obviously less complications than those with suture anchor (OR=0.54, 95% CI: 0.30 to 0.97;  $P=0.04$ ), (Fig. 2).

**3.3.2. Recurrence.** Postoperative recurrence of mallet finger was reported in only 2 trials.<sup>[20,24]</sup> A total of 92 patients, in which 45 patients for kirschner wire fixation group and 47 patients for suture anchor group, were included for recurrence analysis. No significant heterogeneity was found ( $I^2=0\%$ ;  $P=.36$ ) and no significant difference was seen on the incidence of recurrence between the two surgical groups (OR=1.05, 95% CI: 0.17 to 6.28,  $P=.96$ ), (Fig. 3).

**3.3.3. VAS at the final follow-up.** The intensity of pain was measured in a VAS scale of 0 to 10, with a lower score representing a better condition. Data regarding VAS at the final follow-up was available in 3 articles<sup>[21,23,25]</sup> with 151 cases while 76 patients for Kirschner wire fixation group and the leftover patients for suture anchor group. The statistical results demonstrated no significant heterogeneity existing among the 3 studies ( $I^2=0\%$ ;  $P=.56$ ), so the FEM was applied and the

pooled results revealed the patients treated with the two surgical options had equivalent relief at the final follow-up (MD=0.11, 95% CI: -0.15 to 0.37;  $P=.42$ ), (Fig. 4).

**3.3.4. Total active range motion.** Data regarding total active range motion of DIP joint was available in 4 trials<sup>[21,23-25]</sup> except for one study<sup>[27]</sup> with no useful date, which enrolled 96 patients in each group. Significant heterogeneity ( $I^2=99\%$ ;  $P<.00001$ ) was detected among the studies. The FEM was performed and the pooled results showed mallet fingers treated with Kirschner wire fixation had no better total active range motion of DIP joint than who treated with suture anchor (MD=5.50, 95% CI: -15.09 to 30.8;  $P=.66$ ), (Fig. 5). No study was found significantly influenced the results by sensitivity analysis. Subgroup analysis could not be performed because of too little samples.

**3.3.5. DIP joint extensor lag angle.** A total of 4 trials<sup>[21,23-25]</sup> included 192 cases had discussed the extensor lag angle of DIP joint after mallet fingers surgery. Each group included 96 patients treated separately with kirschner wire or suture anchor. The overall estimate revealed no heterogeneity existed ( $I^2=0\%$ ;  $P=.91$ ). At the same time, the pooled results showed the two groups had similar DIP joint extensor lag angle after surgery compared with each other (MD=0.89, 95% CI: -0.78 to 0.57;  $P=.30$ ), (Fig. 6).

**3.3.6. Functional assessment.** There were 5 studies including 216 cases<sup>[21,23-26]</sup> used Crawford criteria while only 2 articles<sup>[20,22]</sup> enrolled 91 patients used TAM system to assess the postoperative functional outcomes and effectiveness of the two operative methods. What's more, just one literature<sup>[27]</sup> used

**Table 4**  
Quality assessment according to the Newcastle–Ottawa scale of the non-randomized studies.

References	Selection	Comparability	Exposure	Outcome of study participants	Total score
Wang 2017	3	0	–	3	6
Gu 2018	2	0	–	2	4
Xing 2013	4	0	–	3	7
YJ Zhang 2018	3	0	–	3	6

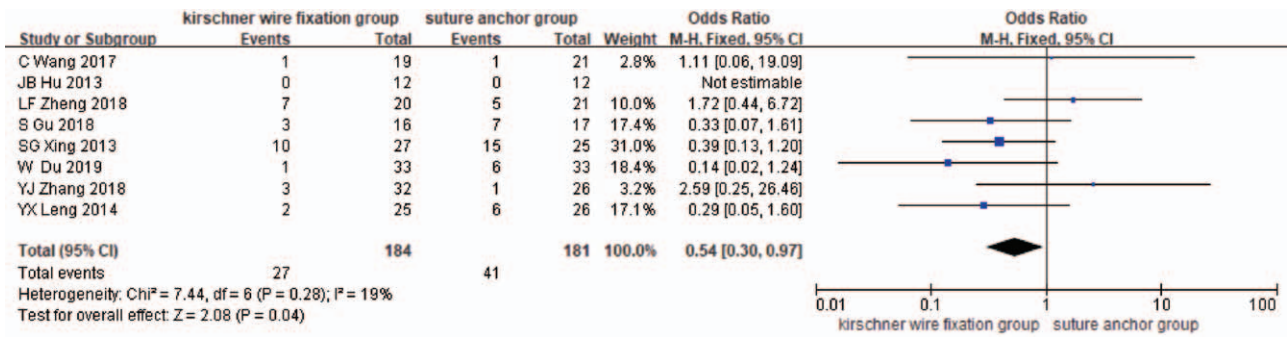


Figure 2. The forest plot for comparison of complications between kirschner wire fixation group versus suture anchor group.

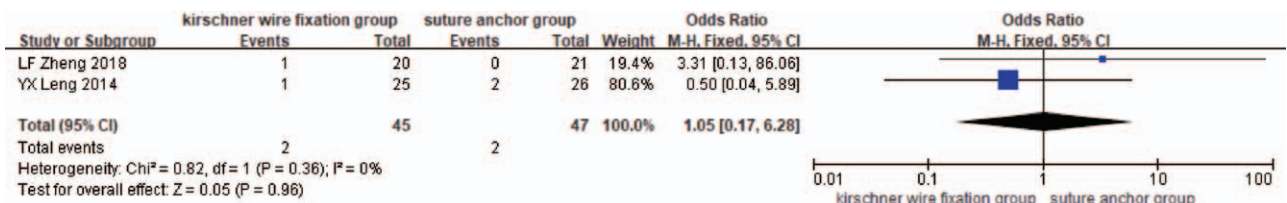


Figure 3. The forest plot for comparison of recurrence between kirschner wire fixation group versus suture anchor group.

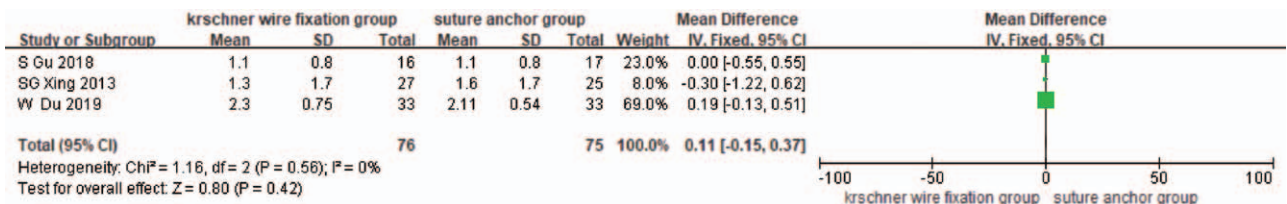


Figure 4. The forest plot for comparison of VAS between kirschner wire fixation group versus suture anchor group.

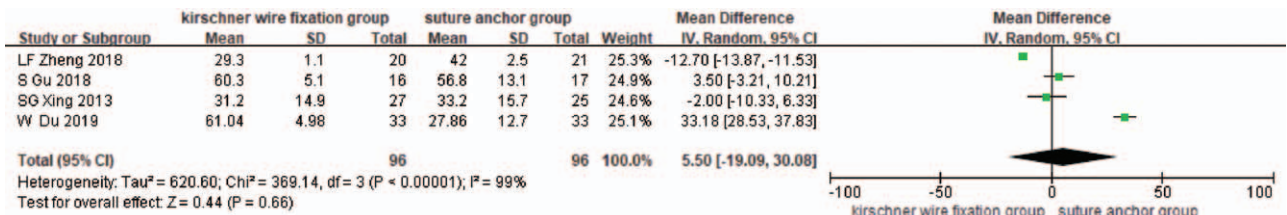


Figure 5. The forest plot for comparison of total active range motion of DIP joint between kirschner wire fixation group versus suture anchor group.

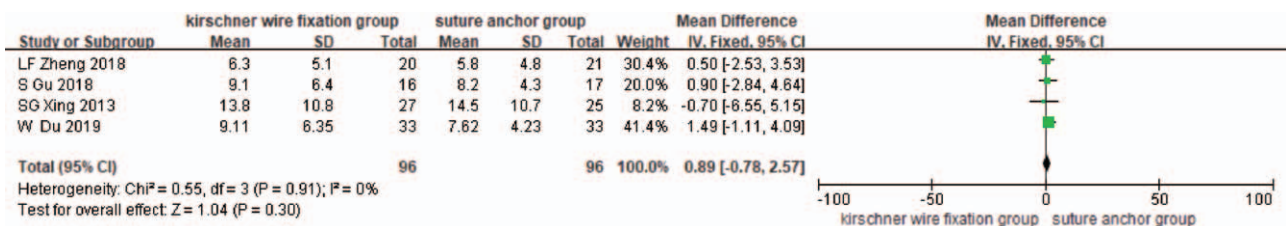
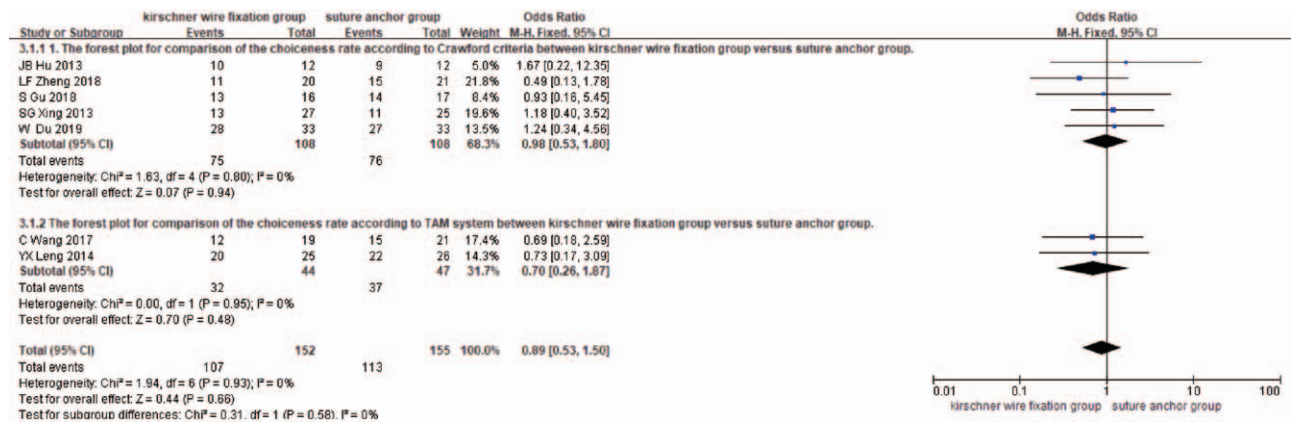


Figure 6. The forest plot for comparison of postoperative DIP joint extensor lag angle between kirschner wire fixation group versus suture anchor group.



**Figure 7.** The forest plot for comparison of functional assessment between kirschner wire fixation group versus suture anchor group. 1. Subgroup analysis of the forest plot for comparison of the choiceness rate according to Crawford criteria between kirschner wire fixation group versus suture anchor group. 2. Subgroup analysis of the forest plot for comparison of the choiceness rate according to TAM system between kirschner wire fixation group versus suture anchor group.

Patel’s functional evaluation criteria was eliminated in this review. Significant heterogeneity ( $I^2=0\%$ ;  $P=.56$ ) was not detected among the studies, the overall statistical results (OR= 0.89, 95% CI: 0.53 to 1.50;  $P=.66$ ), (Fig. 7) suggested no significant difference about the the choiceness estimated by the functional evaluation criteria were found between the two groups. Subgroup analysis was performed in base of the different functional evaluation criteria. There was no significant heterogeneity from the both two subgroups. Evaluated singly by no matter Crawford criteria or TAM system at the final follow-up, the groups treated with Kirschner wire showed no more advantageous functional outcomes than those treated with suture anchor based on the pooled results (OR=0.98, 95% CI: 0.53 to 1.80;  $P=.94$ ) and (OR=0.20, 95% CI: 0.26 to 1.87;  $P=.46$ ), (Fig. 7).

#### 4. Discussion

Common view on optimal treatment for mallet finger lesions was still a controversial issue. A Cochran meta-analysis of four randomized controlled trials by Handoll and Vaghela<sup>[4]</sup> concluded there was inadequate evidence to recommend specific surgical indications compared with conservative treatment. Another systematic review by James et al<sup>[28]</sup> thought both surgical and nonsurgical treatments of mallet finger injuries lead to excellent clinical outcomes, treatment options should be individualized to the patients. However, surgical intervention is necessary under the following circumstances in our opinion:

- 1) mallet finger injuries involving more than one-third of the DIP joint articular surface and those with subluxation or displacement
- 2) the patients couldn’t suffer the external fixation for long term which hinders optimal results.<sup>[29,30]</sup>

Surgical treatment involved the repair of the tendon and fracture reduction and fixation. Even to this day, numerous surgical techniques had been described on the basis of the approach, reduction technique, and means of fixation apparatus. Among them, Kirschner wire and suture anchor had been the two most common fixation devices for mallet finger treatment in clinical practice.<sup>[13,31–33]</sup> Since the extension-block pinning technique reported by Ishiguro et al,<sup>[34]</sup> smooth kirschner wires had become

the most popular treatment methods for mallet fractures as operated simply, fixed relatively stable, spent less. Meanwhile, which also associated with several potential problems like loosening, displacement of the fixation, iatrogenic nail bed injury, chondral damage, or osteoarthritis.<sup>[35]</sup> On the other side, suture anchor technique had been gradually applied to reconstruction of tendon insertion for the treatment of mallet fingers, which could provide more stability and less time for fixation.<sup>[36]</sup> However, some scholars proposed the use of suture anchor may accompany with more complications relative to Kirschner wire. A few previous studies had compared the two surgical methods to determine which was the optimum option but no consensus was achieved. Thus, this meta-analysis was performed to comprehensively examine the evidence for the effectiveness and safety of the different treatment for mallet finger injuries.

In this meta-analysis, we used strict eligibility criteria. Clinical outcomes included complications, recurrence, Visual Analogue Scale (VAS) scores, DIP joint extensor lag angle, total active range motion of DIP joint, the choiceness rate as functional assessment at the final follow-up were assessed in this study. Given the above-mentioned results, no significant difference were found in term of the Visual Analogue Scale (VAS) scores, DIP joint extensor lag angle, total active range motion of DIP joint, functional assessment employed Crawford criteria and TAM system at the final follow-up between the Kirschner wire fixation group and suture anchor group, which suggested both the two surgical interventions could lead to equivalent excellent clinical outcomes for mallet finger lesions. On the flip side, The pooled results showed patients treated with suture anchor had obvious more complications than those treated with Kirschner wire mainly included nail deformity, infection and skin necrosis. While no difference was found on the recurrence, which was consistent with the most included studies. Which suggested the application of Kirschner wire for mallet finer injuries may be safer than suture anchor. We inferred that compared with Kirschner pin, suture anchor technique had some inferiorities which needed more soft tissue stripping and destroyed blood supply around tendon insertion seriously, besides, too many suture knot lead higher risk of infection and skin necrosis. Moreover, a surgical procedure with suture was more closed to nail root which was prone to nail deformity.



Meta-analysis has been recognized as an effective method to resolve a wide variety of clinical questions by summarizing and reviewing published quantitative studies. However, several potential limitations existed in the present analysis:

- 1) This meta-analysis was comprised of some variable quality studies included randomized and non-randomized observational trials. Studies with low evidence levels may introduce selection bias more easily.
- 2) Some clinical heterogeneity were inevitable in this article. For example, the classification of included mallet finger lesions were not always coincident. In addition, the time for removal of Kirschner wires postoperatively was not consistent in each included study. What's more, additional splint fixation after surgery was applied in some studies while others not. Last but not the least, postoperative rehabilitation exercises varied from different centers.
- 3) The sample of cases in this review was small and only Chinese recruited.

## 5. Conclusion

In summary, this meta-analysis was firstly to compare the effectiveness and safety of the treatment for mallet finger via Kirschner wire fixation versus suture anchor technique. Although both the two surgical treatments lead to excellent clinical outcomes for mallet finger lesions, Kirschner wire fixation should be a better alternative for less complications and less economic spending for essential surgical treatment. Of course, a large sample of cases and high-quality randomized controlled trials should be recruited to further confirm the conclusion.

## Author contributions

**Data curation:** Yongjun Rui.

**Formal analysis:** Haifeng Shi.

**Methodology:** Ke Wu, Yong Shen.

**Software:** Zhihai Zhang.

**Validation:** Haifeng Shi.

**Writing – original draft:** Yongjing Huang.

## References

- [1] Ramponi DR, Hellier SD. Mallet Finger. *Adv Emerg Nurs J* 2019; 41:198–203.
- [2] Stack HG. Mallet finger. *Hand* 1969;1:83–9.
- [3] Alla SR, Deal ND, Dempsey IJ. Current concepts: mallet finger. *Hand (N Y)* 2014;9:138–44.
- [4] Handoll HH, Vaghela MV. Interventions for treating mallet finger injuries. *Cochrane Database Syst Rev*.
- [5] Salazar Botero S, Hidalgo Diaz JJ, Benaída A, et al. Review of acute traumatic closed mallet finger injuries in adults. *Arch Plast Surg* 2016; 43:134–44.
- [6] Eddy M. Hands, fingers, thumbs assessment and management of common hand injuries in general practice. *Aust Fam Physician* 2012; 41:202e209.
- [7] Hamas RS, Horrell ED, Pierret GP. Treatment of mallet finger due to intra-articular fracture of the distal phalanx. *J Hand Surg Am* 1978; 3:361–3.
- [8] Cheung JP, Fung B, Ip WY. Review on mallet finger treatment. *Hand Surg* 2012;17:439–47.
- [9] Hanz KR, Saint-Cyr M, Semmler MJ, et al. Extensor tendon injuries: acute management and secondary reconstruction. *Plast Reconstr Surg* 2008;121:109e–20e.
- [10] Webbé MA, Schneider LH. Mallet fractures. *J Bone Joint Surg Am* 1984;66:658–69.
- [11] Rockwell WB, Butler PN, Byrne BA. Extensor tendon: anatomy, injury, and reconstruction. *Plast Reconstr Surg* 2000;106:1592–603. quiz 1604, 1673.
- [12] Batbay SG, Akgül T, Bayram S, et al. Conservative management equally effective to new suture anchor technique for acute mallet finger deformity: A prospective randomized clinical trial. *J Hand Ther* 2018;31:429–36.
- [13] Smit JM, Beets MR, Zeebregts CJ, et al. Treatment options for mallet finger: a review. *Plast Reconstr Surg* 2010;126:1624–9.
- [14] Toker S, Türkmen F, Pekince O, et al. Extension block pinning versus hook plate fixation for treatment of mallet fractures. *J Hand Surg Am* 2015;40:1591–6.
- [15] Crawford GP. The molded polythene splint for mallet finger deformities. *J Hand Surg Am* 1984;9:231–7.
- [16] Pan DD, Gu YG, Shi D, et al. The standard for assessment of upper limb functions issued by the hand surgery society of Chinese Medical Association. *Chin J Hand Surg* 2000;16:130–5.
- [17] Furlan AD, Pennick V, Bombardier C, et al. Editorial Board, Cochrane Back Review Group 2009 updated method guidelines for systematic reviews in the Cochrane Back Review Group. *Spine (Phila Pa 1976)* 2009;34:1929–41.
- [18] Stang A. Critical evaluation of the Newcastle-Ottawa scale for the assessment of the quality of nonrandomized studies in meta-analyses. *Eur J Epidemiol* 2010;25:603–5.
- [19] Higgins JP, Thompson SG. Quantifying heterogeneity in a meta-analysis. *Stat Med* 2002;21:1539–58.
- [20] Leng YX, Le Z, Deng X, et al. Comparison of clinical efficacy of two surgical procedures for mallet fingers. *Pract Clin Med* 2014;15:40–2. [In Chinese].
- [21] Du W, Li XF, Zhang WX, et al. Comparison of the clinical effect of different surgical methods for the treatment of Doyle type I mallet fingers. *ZH J J Traumatic* 2019;24:1018–9.
- [22] Wang C, XZ Shao Individualized treatment and clinical analysis of mallet finger. [Master Dissertation By Hebei Medical University.
- [23] Gu S, Xie RG. Comparison of clinical efficacy between only Kirschner wire and mini bone anchor combined with Kirschner wire for treatment of Doyle type I a mallet fingers. *Chin J Hand Surg* 2018;34:367–9.
- [24] Zheng LF, Xie J, Ye JJ. Comparative study on the treatment of mallet fingers: micro bone anchor combined with Kirschner wire versus only Kirschner wire. *Chin J Hand Surg* 2018;34:329–32.
- [25] Xing SG, Xie RG, Tang JB, et al. Clinical evaluation of two operative treatment methods for acute mallet frager: functional outcomes and complications. *Chin J Hand Surg* 2013;29:104–7.
- [26] Hu JB, Jiang XD, Li DW, et al. Comparison of clinical efficacy of three surgical procedures for mallet fingers. *ZH J J Traumatic* 2013;18:175–6.
- [27] Zhang YJ, Ju JH, Zhou LG, et al. Clinical efficacy analysis of three kinds of surgical treatment for bony mallet fingers. *Chin J Hand Surg* 2018; 34:24–6.
- [28] Lin JS, Samora JB. Surgical and nonsurgical management of mallet finger: a systematic review. *J Hand Surg Am* 2018;43:146–63. e2.
- [29] Takami H, Takahashi S, Ando M. Operative treatment of mallet finger due to intra-articular fracture of the distal phalanx. *Arch Orthop Trauma Surg* 2000;120:9–13.
- [30] Lubahn JD. Mallet finger fractures: a comparison of open and closed technique. *J Hand Surg Am* 1989;14(2 Pt 2):394–6.
- [31] Chung DW, Lee JH. Anatomic reduction of mallet fractures using extension block and additional intrafocal pinning techniques. *Clin Orthop Surg* 2012;4:72–6.
- [32] Shimura H, Wakabayashi Y, Nimura A. A novel closed reduction with extension block and flexion block using Kirschner wires and microscrew fixation for mallet fractures. *J Orthop Sci* 2014;19:308–12.
- [33] Tetik C, Gudemez E. Modification of the extension block Kirschner wire technique for mallet fractures. *Clin Orthop Relat Res* 2002;284–90.
- [34] Ishiguro T, Itoh Y, Yabe Y, et al. Extension block with Kirschner wire for fracture dislocation of the distal interphalangeal joint. *Tech Hand Up Extrem Surg* 1997;1:95–102.
- [35] Çapkın S, Buyuk AF, Sürücü S, et al. Extension-block pinning to treat bony mallet finger: Is a transfixation pin necessary? *Ulus Travma Acil Cerrahi Derg* 2019;25:281–6.
- [36] Koss S, Richmond JC, Woodward JS Jr. Two- to five-year followup of arthroscopic Bankart reconstruction using a suture anchor technique. *Am J Sports Med* 1997;25:809–12.