



## Clinical Studies

## Obturator inlet and iliac oblique technique for safe, convenient, and reliable iliac screw placement



Ashraf N. El Naga, MD, David Gendelberg, MD\*

Orthopaedic Trauma Institute, Department of Orthopaedic Surgery, University of California, 2540 23rd St, Building 7, 3rd Floor, San Francisco, CA 94110, United States

## ARTICLE INFO

## Keywords:

Lumbopelvic fixation  
Fluoroscopy  
Iliac screws  
Iliac bolts  
Obturator inlet  
Iliac oblique

## ABSTRACT

**Background:** There are many described techniques for the placement of posterior iliac screws for extension of lumbar posterior spinal instrumentation to the pelvis. However, each one has its limitations. We describe our technique for fluoroscopic guidance of iliac screw placement utilizing the obturator inlet and iliac oblique views as well as a detailed review of how to obtain and interpret these views for safe iliac screw placement.

**Methods:** Retrospective chart review of patients undergoing iliac screw placement utilizing the obturator inlet and iliac oblique views as part of spine instrumentation between January 2019 and March 2022. Screw length and bony breaches are reported utilizing this technique.

**Results:** Twelve patients underwent posterior lumbopelvic fixation with a total of 23 screws placed via either open or percutaneous technique. The mean screw length was 96.5 mm (Range 80–110, standard dev 7.75). There were no recorded breaches or recannulation attempts.

**Conclusions:** We show how this technique is a much more convenient alternative to the placement of iliac screws under the obturator outlet oblique (“teardrop” view) which necessitates that the C-arm is in line with the instruments being placed. These described views can be used to place screws with either open or percutaneous techniques and with either the posterior superior iliac spine (PSIS) or S2 alar iliac (S2AI) starting points.

## Introduction

Posterior spinal instrumentation is often extended distally to the pelvis whenever more robust distal fixation is required or for stabilization of lumbosacral injuries. Pelvic fixation may be indicated in trauma, deformity, degenerative, and oncologic procedures. Safe placement of these screws is of the utmost importance. The corridor of bone utilized, often named the supraacetabular corridor or the sciatic buttress, spans the area between the anterior inferior iliac spine (AIIS) ventrally and the posterior superior iliac spine (PSIS) dorsally. There are several described techniques for placement of these screws [1–4]. The 2 commonly described start points for these screws are the PSIS and S2 alar iliac (S2AI) starting points. The PSIS start point starts directly on the PSIS while the S2AI starting point is lateral to the area between the S1 and S2 foramen but medial to the iliac crest.

## Placement techniques

There are several described placement techniques once a desired starting point has been decided on. Regardless of the technique used,

safe screw placement relies on the screw not breaching medially, laterally, cranially, or caudally. Medial or cranial breaches risk injury to the iliac vessels or their branches within the pelvis [5,6]. A caudal breach may violate the hip joint or breach the sciatic notch risking injury to the sciatic nerve or the superior gluteal artery.

## Freehand technique

The current standard of care is a freehand technique with fluoroscopic confirmation on the teardrop view (obturator outlet) [4]. With this technique, the starting point, whether the PSIS or S2AI, is confirmed on the teardrop view. Despite the usefulness of the teardrop as a confirmatory view, it cannot be used practically to guide iliac screw placement as the fluoroscopy unit is in the way of the trajectory of the screw and preparation tools (Fig. 1A). As a result, the C-arm is in the way and needs to either be moved when instrumenting or the surgeon needs to non-ergonomically work around it. The sciatic buttress corridor is then cannulated by directing a pedicle finder in the direction of the palpated ipsilateral greater trochanter. Differing patient habitus makes this quite imprecise and risks medial and lateral breaches. Using this technique,

FDA device/drug status: Not applicable.

Author disclosures: **ANEN:** Nothing to disclose. **DG:** Nothing to disclose.

\* Corresponding author. David Gendelberg, MD, Orthopaedic Trauma Institute, Department of Orthopaedic Surgery, University of California, 2540 23rd St, Building 7, 3rd Floor, San Francisco, CA 94110 USA. Tel.: (628) 206-8812, fax: (415) 647-3733.

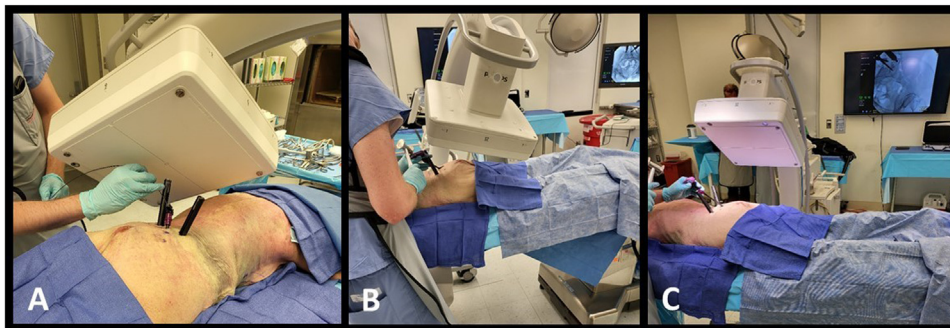
E-mail address: [David.Gendelberg@ucsf.edu](mailto:David.Gendelberg@ucsf.edu) (D. Gendelberg).

<https://doi.org/10.1016/j.xnsj.2023.100298>

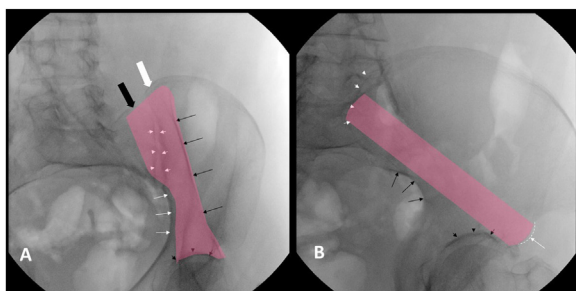
Received 11 September 2023; Received in revised form 20 November 2023; Accepted 21 November 2023

Available online 26 November 2023

2666-5484/© 2023 The Author(s). Published by Elsevier Inc. on behalf of North American Spine Society. This is an open access article under the CC BY-NC-ND license (<http://creativecommons.org/licenses/by-nc-nd/4.0/>)



**Fig. 1.** Surgeon with c-arm in the teardrop view (A), inlet obturator view (B), and iliac oblique view (C). Note that in the teardrop view, the surgeon’s access to the instruments is obscured.



**Fig. 2.** Obturator inlet (A) and the iliac oblique (B) shown with the safe zones for cannulation highlighted (pink).

surgeons often settle for a shorter screw than what would be achievable if the full corridor was visualized and cannulated despite studies demonstrating that a 100 mm screw can fit in the majority of patients without concern for a cortical breach [7].

*Navigated technique*

In response to the above shortcomings of freehand techniques, there is literature describing placement under navigation or use of three-dimensional printed navigation guides [2,3,8,9]. This technique allows for cannulation of the entire available corridor. However, navigation may not be widely available, necessitates increased radiation to the patient, and adds to the surgical duration.

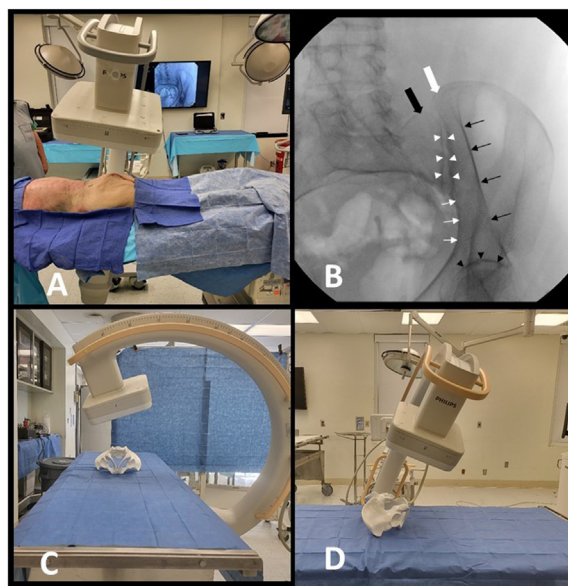
As a result of the disadvantages involved with utilizing the teardrop view in guiding screw placement, this article aims to describe the utility and technique for using the obturator inlet (OI) and iliac oblique (IO) views when placing posterior iliac screws using a mobile C-arm. We describe the use of two fluoroscopic views that can be used in placing posterior iliac screws of at least 100 mm in length.

1. Medial/lateral trajectory are based on the OI (Fig. 2).
2. Cranial/caudal trajectory is guided by the IO (Fig. 2).
3. The teardrop view is optional and used solely as a confirmatory view of the start point or location for a percutaneous incision if the percutaneous technique is used and as a confirmatory view after screw placement.

**Materials and methods**

*Fluoroscopic view technique*

Fundamentally, the placement of any screw in the pelvis consists of identifying a safe start point and directing in an appropriate medial/lateral trajectory and cranial/caudal trajectory.



**Fig. 3.** Obturator inlet view. C-Arm relative to the patient (A). Obturator inlet view demonstrating visualization of the outer iliac cortex (thin black arrows), medial border (thin white arrows), sacroiliac joint (white arrowheads), hip joint (black arrowheads), posterior sacral ala (large black arrow) and PSIS (large white arrow) (B). Photos demonstrating the c-arm position for the obturator inlet view relative to the pelvis in the prone position (C) and (D).

*Obturator inlet view*

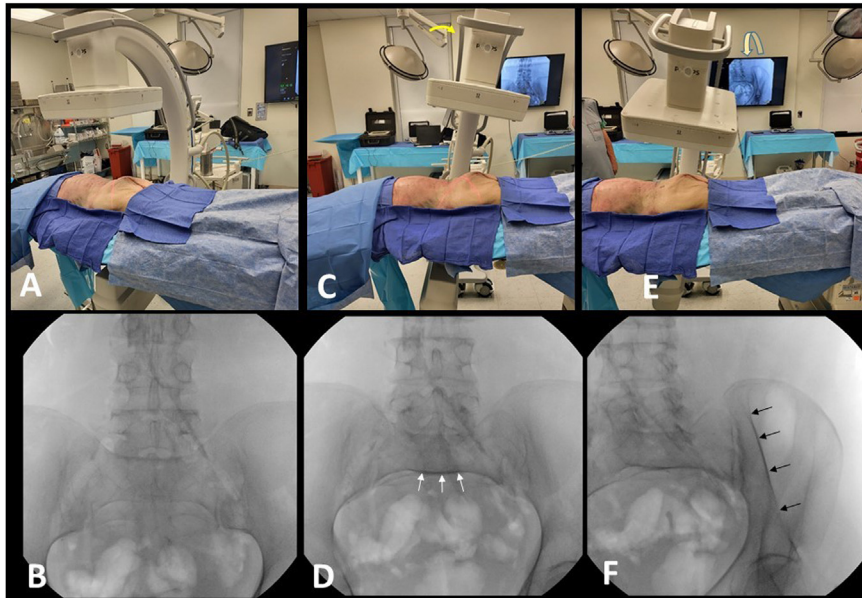
The OI view is tangential to both the inner and outer cortices of the ilium at the level of the PSIS-AIIS corridor (Fig. 3). This view also provides an assessment of the sacroiliac joint and is used to guide the medial and lateral trajectory.

*Technique for obtaining the obturator inlet view:*

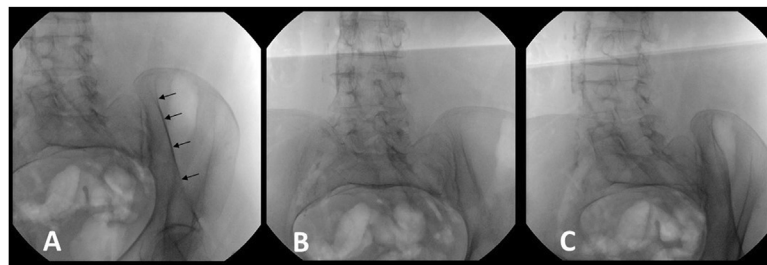
From the AP view of the pelvis (Fig. 4A and B), the stepwise approach for obtaining an adequate OI view in the prone position is as follows:

1. Tilt caudally towards a pelvic inlet view until the anterior S1 and S2 vertebral bodies overlap (Fig. 4C and D)
2. Roll over the top away from the side of the hemipelvis being instrumented (Fig. 4E).
3. Continue to roll over until the outer table of the PSIS is well-delineated (Fig. 4F).

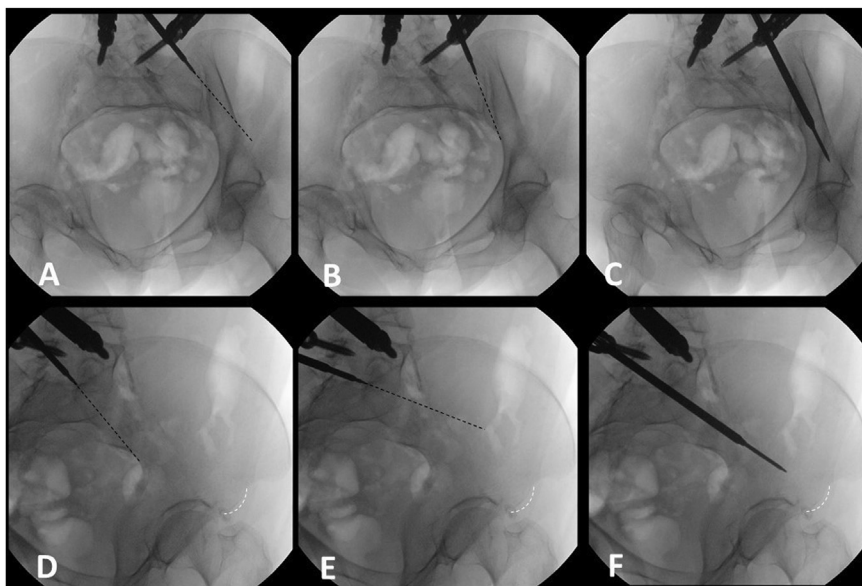
Fig. 5 demonstrates the appearance of this view if the flat panel detector is rolled over too little or too much. Fig. 6A–C demonstrate the use of this view in guiding medial and lateral trajectory.



**Fig. 4.** Obtaining the obturator inlet view. C-arm is first positioned for the AP view (A) and (B). Then the c-arm is tilted caudally (C) to obtain inlet view until a crisp anterior vertebral cortex (white arrows) is visualized (D), as the inlet beam is tangential to the anterior S1 and S2 vertebral bodies in this position. Then the c-arm position is rotated away from the side to be instrumented (E) to obtain the obturator inlet view until the obturator inlet view demonstrates a crisp outer iliac cortex (black arrows) (F).

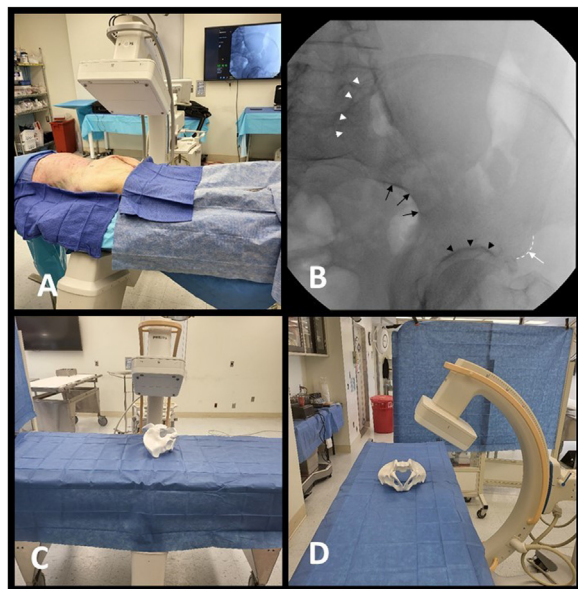


**Fig. 5.** Fluoroscopic obturator inlet view demonstrating a crisp outer cortical line (black arrows) (A). This is obscured if there is too little (B) or too much (C) obturator tilt.



**Fig. 6.** Obturator inlet view. Cannulation instrument aiming too lateral (A), too medial (B), and with a cannulation instrument safely down the sciatic buttress corridor (C). Iliac oblique view with cannulation instrument aiming too caudal (D) and too cranial (E) relative to the AIIS (white dashed line). (F) The cannulation instrument shown was directed safely down the sciatic buttress corridor toward the AIIS.





**Fig. 7.** Iliac oblique view. C-arm relative to the patient (A). Inlet oblique view demonstrating visualization of the sciatic notch (black arrows), AIIS (dashed white line), PSIS (white arrowheads), and hip joint (black arrowheads) (B). Photos demonstrating the c-arm position for the iliac oblique view relative to the pelvis in the prone position (C) and (D).

*Iliac oblique view*

The IO view provides an *en face* of the instrumented iliac wing clearly delineating the sciatic notch, the hip joint, and the AIIS (Fig. 7B). This view is used to guide the cranial-caudal trajectory. On this view the screw should not be aiming any more cranial than the superior aspect of the AIIS) (Fig. 7).

*Technique for obtaining iliac oblique view*

From the AP view of the pelvis, the stepwise approach for obtaining an adequate OI view in the prone position is as follows: (Fig. 7)

1. Roll back towards the side of the hemiplevis being instrumented until the sciatic notch and the anterior inferior iliac spine can be clearly delineated.

In this view, the screw should be directed to the area between the proximal and distal aspects of the AIIS. Fig. 6D–F demonstrates the use of this view in guiding cranial and caudal trajectory.

Alternating between these 2 views can be done without interfering with the surgical instrumentation (Fig. 1B–C). As placement of screws in this corridor requires alternating between these views as corrections are made, functions of position memory in the fluoroscopy unit and a reliable fluoroscopy technician are incredibly valuable adjuncts.

Images and figures were generated using a cadaver specimen. Images were obtained using a C-arm (Zenith 70, Philips).

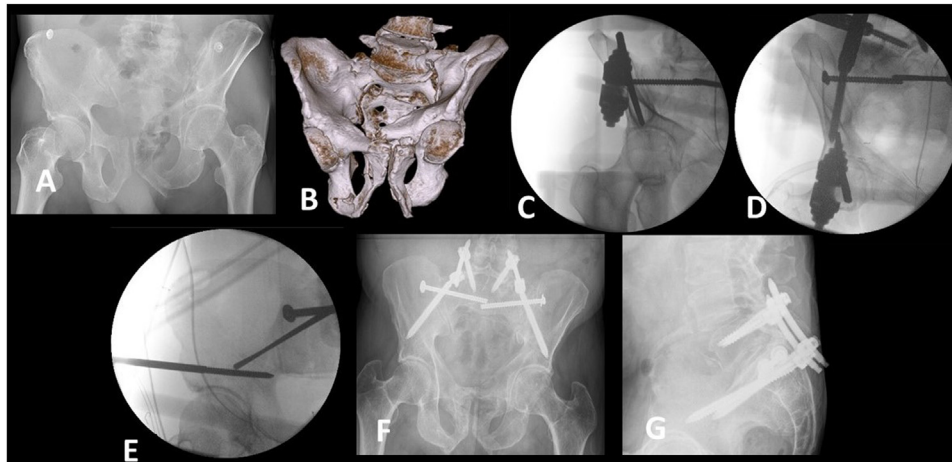
*Study design*

This study was approved by our institution’s IRB board. A retrospective chart review was conducted for all patients undergoing posterior sacropelvic fixation between January 2019 and March 2022 at a Level 1 trauma center. The intraoperative records were reviewed for implanted screw length and diameter. Radiation time and exposure were collected. The intra or postoperative CT was reviewed for any cortical breach or breach of the hip joint. Screws were determined to be S2AI screws if they involved the SI joint and iliac screws if their entire trajectory was

Case	Right screw Length (mm)	Right screw S2AI vs Iliac	Left screw Length (mm)	Left screw S2AI vs Iliac	Mean screw Length (mm)	Screw Diameter (mm)	Levels	Indications	Instrumentation technique	Intraop CT	Radiation Exposure (mGy)	Radiation time (min)
1	80	Iliac	80	Iliac	80	8.0	L3-iliolum	Trauma	Open	Yes	66.3*	2.6*
2	90	Iliac	90	Iliac	90	7.5	L5-iliolum	Trauma	Open	Yes	37.1*	3.1*
3	110	S2AI	110	Iliac	110	8.0	L5-iliolum	Trauma	Open	Yes	147.2*	8.0*
4	90	S2AI	90	Iliac	90	7.5	L4-iliolum	Trauma	Perc	Yes	114	5.3
5	100	S2AI	100	S2AI	100	8.5	L5-iliolum	Trauma	Perc	Yes	140*	6.7*
6	100	S2AI	100	Iliac	100	8.5	L5-iliolum	Trauma	Perc	Yes	44.9	2.9
7	100	S2AI	100	S2AI	100	8.5	L5-iliolum	Trauma	Perc	No	56.5	3.4
8	100	S2AI	100	S2AI	100	8.0	L2-iliolum	Degen	Open	Yes	339.0*	5.2*
9	90	Iliac	90	Iliac	90	8.0	S1-iliolum	Trauma	Perc	Yes	110	2.6
10	100	S2AI	100	S2AI	100	8.5	L5-iliolum	Trauma	Perc	Yes	96.2*	4.3*
11	-	-	100	Iliac	100	8.5	L5-iliolum	Trauma	Perc	Yes	201.0*	4.7*
12	100	S2AI	100	S2AI	100	8.5	L5-iliolum	Trauma	Perc	Yes	88.7	6.2*

**Table 1**  
Case characteristics.

\* Indicates that other procedures involving fluoroscopy were also performed during this radiation period.



**Fig. 8.** A 62-year-old poly-trauma patient presenting with pelvic ring disruption and a spinopelvic dissociation (A and B). After pelvic ring stabilization with iliosacral screws and an anterior pelvic external fixator, the teardrop view (C) of the right hemipelvis is shown. The obturator inlet (D) and iliac oblique (E) are used to cannulate and place iliac screws below the iliosacral screws and lateral to the external fixator pin. Six month postoperative images are shown (F and G).

within the ilium. Of note, obtaining intraoperative or postoperative CTs are unrelated to the described technique. They are obtained as a matter of routine at our institution to evaluate fracture reduction (in trauma cases) and confirm the safe placement of hardware. Whether to obtain intraoperative or postoperative CT is at the surgeon's discretion. The operative note was reviewed for any recannulation attempts. The statistical analysis was done using Excel.

## Results

Between January 2019 and March 2022, 12 patients underwent posterior lumbopelvic fixation with a total of 23 screws placed via either open or percutaneous technique by 2 spine fellowship-trained surgeons. All patients had their pelvis instrumented with the described fluoroscopic technique and without the use of navigation or robotic assistance. The mean screw length was 96.5 mm (Range 80–110, standard dev 7.75). There were no recorded breaches or recannulation attempts. No changes were made after obtaining CT imaging. In Table 1 we have provided the details of each of the cases, including whether iliac fixation or S2AI fixation was performed. Of note, the cases with the asterisk had other procedures, such as transiliac transsacral screws, done under the same fluoroscopy time. Therefore, in those cases, the radiation values do not represent this technique alone.

## Discussion

Placement of iliac or S2AI screws in spinal surgery is commonly performed when extending constructs down to the pelvis. It is important to do so in a safe manner. Therefore, surgeons will often use anatomical landmarks, fluoroscopic assisted techniques utilizing the teardrop view, or CT navigation, which all have their advantages and disadvantages.

The freehand technique utilizes anatomic landmarks to guide screw placement with confirmation on the teardrop view (obturator outlet) [4]. The sciatic buttress corridor is then cannulated by directing a pedicle finder in the direction of the palpated ipsilateral greater trochanter. Described complications for S2AI screws placed with the freehand technique include screw misplacement, breach of cortical bone, and injury to neurovascular structures [6,10]. Differing patient habitus and variations in sacroiliac joint anatomy makes this quite imprecise and risk medial and lateral breaches [6]. With difficulty in judging the medial and lateral trajectory, surgeons often settle for a shorter screw than what would be achievable if the full corridor was visualized and cannulated. In this article, we present 2 nearly orthogonal views that can be used to guide both the cranial-caudal trajectory and medial-lateral trajectory

for safe iliac screw placement and maximize obtainable screw length. Of note, though our average screw length was slightly below 100 mm, we were frequently using the longest length available with the given system being used.

The fluoroscopic assisted technique utilizes the teardrop and lateral views to assist with screw placement. In this technique, the starting point, whether the PSIS or S2AI, is determined anatomically or by using the teardrop [11]. In our experience it is incredibly difficult to obtain real-time fluoroscopy on the teardrop view while instrumenting the pelvis since the C-arm is in the way (Fig. 1A). Therefore, the teardrop view is obtained after a cannulation attempt has already been made and the pedicle probe may be found to already be headed too medial or too lateral. Subsequently, correcting the trajectory may be more challenging and the surgeon may accept a shorter screw.

If the patient already has hardware in the sciatic buttress, such as in the case of pelvic external fixation or when there is the need for an additional iliac screw, the teardrop view may be insufficient to guide the safe placement of the iliac screw (Fig. 8). Furthermore, the teardrop view would be of little use to help navigate iliac screw placement around the pre-existing hardware (Fig. 8C).

In light of these disadvantages, several have advocated for screw placement under navigation or using 3D-printed navigation guides [2,3,8,9]. These techniques do allow for cannulation of the entire available corridor. However, navigation may not be widely available, necessitates increased radiation to the patient, and adds to the surgical duration if it is based off an intraoperative CT. Furthermore, if a drill or instrument deflects off a cortex or the SI joint when using the navigated technique this may go unnoticed, as the images are projections as opposed to real-time images obtained during fluoroscopically guided placement [6]. In a study by Tamaki et al., they evaluated the accuracy of S2AI screw insertion using navigation. While they concluded it to be safe, they found that among their breached screws the location of the breach was anterior to the cortex of the sacrum. Their proposed mechanism for this breach was that the navigation probe slips anteriorly due to the hard cortical bone of the ilium and sharp anterior slant of the iliac cortex [12]. Presumably, using our described technique, one would be able to detect this in real-time and subsequently correct it.

In this article, we describe the use of two fluoroscopic views that can be used to guide placement of posterior iliac screws that will maximize the usage of the entire length of the sciatic buttress and decrease the risk of a breach.

Benefits of the described technique include the fact that cannulation of the sciatic buttress and screw placement is not impeded by the position of the fluoroscopy machine as is the case with placement under

the traditional “teardrop” view. Furthermore, the obturator inlet view helps guide the medial and lateral trajectory to prevent medial or lateral cortical breaches. Utilizing these views also allows for maximal screw length and the ability to navigate around any existing hardware (total hip arthroplasty, previously placed sacroiliac screws). In addition, one is not reliant on navigation where a deflected drill bit would not be recognized in real-time. This technique can be used in both open and percutaneous procedures and could be used for either PSIS or S2AI start points. Despite the small number of patients presented in this study, our goal was to demonstrate the feasibility, safety, and ease of this fluoroscopic-guided technique. It addresses the common difficulties when solely relying on the teardrop view in the absence of CT-guided navigation. We conclude that this technique is easy to adopt and addresses the shortcomings inherent to all common methods of iliac screw placement, making its use a powerful aide when instrumenting the pelvis.

### Declaration of competing interests

The authors declare that they have no known competing financial interests or personal relationships that could have appeared to influence the work reported in this paper.

### Funding

No financial support was provided for this study.

### Acknowledgments

The authors thank Philips and Nuvasive for their material support for this study.

### References

- [1] Sohn S, Chung CK, Kim YJ, Kim CH, Park SB, Kim H. Modified iliac screw fixation: technique and clinical application. *Acta Neurochir (Wien)* 2016;158(5):975–80. doi:10.1007/s00701-016-2772-x.
- [2] Matsukawa K, Abe Y, Mobbs RJ. Novel technique for sacral-alar-iliac screw placement using three-dimensional patient-specific template guide. *Spine Surg Relat Res* 2021;5(6):418–24. doi:10.22603/ssrr.2020-0221.
- [3] Tanasansomboon T, Tejapongvorachai T, Yingsakmongkol W, Limthongkul W, Kotheeranurak V, Singhatanadgige W. Minimally invasive percutaneous modified iliac screw placement using intraoperative navigation: a technical note. *World Neurosurg* 2021;146:240–5. doi:10.1016/j.wneu.2020.11.112.
- [4] Fang T, Russo GS, Schroeder GD, Kepler CK. The Accurate Free-hand Placement of S2 Alar Iliac (S2AI) Screw. *Clin Spine Surg* 2020;33(3):102–3. doi:10.1097/BSD.0000000000000623.
- [5] Abdul-Jabbar A, Yilmaz E, Iwanaga J, et al. Neurovascular relationships of S2AI screw placement: anatomic study. *World Neurosurg* 2018;116:e108–12. doi:10.1016/j.wneu.2018.04.095.
- [6] Arora A, Berven S. Challenges and complications in freehand S2-alar-iliac spinopelvic fixation and the potential for robotics to enhance patient safety. *Glob Spine J* 2022;12(2\_suppl) 45S–52S. doi:10.1177/21925682211036664.
- [7] Weisenthal BM, Doss DJ, Henry AL, Stephens BF. Optimal trajectory and length of S2 alar iliac screws: a 3-dimensional computed-aided design study. *Clin Spine Surg* 2019;32(7):E335–9. doi:10.1097/BSD.0000000000000837.
- [8] Yu T, Cheng XL, Qu Y, Dong RP, Kang MY, Zhao JW. Computer navigation-assisted minimally invasive percutaneous screw placement for pelvic fractures. *World J Clin Cases* 2020;8(12):2464–72. doi:10.12998/wjcc.v8.i12.2464.
- [9] Zhao Y, Ma Y, Liang J, et al. Comparison of the 3D-printed operation guide template technique and the free-hand technique for S2-alar-iliac screw placement. *BMC Surg* 2020;20(1):258. doi:10.1186/s12893-020-00930-5.
- [10] Park YS, Hyun SJ, Park JH, Kim KJ, Jahng TA, Kim HJ. Radiographic and clinical results of freehand S2 alar-iliac screw placement for spinopelvic fixation: an analysis of 45 consecutive screws. *Clin Spine Surg* 2017;30(7):E877–82. doi:10.1097/BSD.0000000000000520.
- [11] Nowak S, Müller J, Weidemeier ME, Schroeder HWS, Müller JU. Tear-drop technique in iliac screw placement: a technical analysis. *Acta Neurochir (Wien)* 2021;163(6):1577–81. doi:10.1007/s00701-021-04788-1.
- [12] Tamaki R, Wada K, Okazaki K. Surgical technique and accuracy of S2 alar-iliac screw insertion using intraoperative o-arm navigation: an analysis of 120 screws. *World Neurosurg* 2020;144:e326–30. doi:10.1016/j.wneu.2020.08.123.