

# PHACOSIT: A sitting phacoemulsification technique for patients unable to lie down flat during cataract surgery

Jebinth Brayan, Prithvi Chandrakanth<sup>1</sup>, Siddharth Narendran, Kalpana Narendran<sup>1</sup>, Venkatapathy Narendran<sup>1</sup>

Phacoemulsification is routinely performed with the patient lying supine on the surgical table with his or her head flat and facing the overhead microscope. This routine technique can be a challenge in medical conditions such as kyphosis, scoliosis, orthopnea, Meniere's disease, and CNS abnormality. Some cardiovascular and respiratory conditions make the patients breathless when they lie down, whereas other neurological and spinal problem patients are also equally uncomfortable. The only reasonable solution to conduct surgery on a patient who cannot lie down flat on the operating table is to position them face to face in a sitting position. We describe an innovative phacoemulsification technique in a sitting position called "phacosit" in an 80-year-old wheelchair-bound female patient who was denied cataract surgery by other eye surgeons owing to her medical condition.

**Key words:** Cataract surgery, face to face, IOL implantation, phacoemulsification, sitting phacoemulsification

### Access this article online

**Website:**

www.ijo.in

**DOI:**

10.4103/ijo.IJO\_2639\_21

### Quick Response Code:



In 1967, Dr. Charles D. Kelman revolutionized cataract surgeries with the introduction of the phacoemulsification technique, which is now considered the safest and the most preferred technique in cataract surgery to deliver high volume, quality, and affordable medical care.<sup>[1,2]</sup> Phacoemulsification surgery is carried out with patients lying flat on their back and facing the operating microscope in a supine position. This position is considered ideal for both patients and the operating surgeon. However, some patients with cataracts cannot be positioned to face the overhead microscope during the surgery due to their medical conditions, such as patients with spine deformity, kyphosis, scoliosis, orthopnea, Meniere's disease, and CNS abnormality. Some studies have reported cases in which cataract surgery has been done on the patient sitting in a nearly upright position,<sup>[3-8]</sup> face-to-face positioned cataract surgery,<sup>[5,9,10]</sup> and surgical technique done under slit-lamp biomicroscope with the patient sitting in an upright position.<sup>[11]</sup> Others have also reported cases being performed with the surgeon standing while operating on the patient<sup>[12-14]</sup> [Table 1]. Here we describe a frugal innovative surgical technique called phacosit, a procedure of performing phacoemulsification with intraocular lens (IOL) implantation in a sitting position. We describe the phacosit technique in a wheelchair-bound patient because of her inability to lie down flat in a supine position on the operating table as well as major difficulty to transfer the patient to and fro from the wheelchair.

IOL and Refractive Services, Aravind Eye Hospital, Udumalpet, Tamil Nadu, <sup>1</sup>Aravind Eye Hospital, Coimbatore, Tamil Nadu, India

**Correspondence to:** Dr. Prithvi Chandrakanth, Chandradevi, Opp. Super Petrol Pump, Kannur Road, W. Naddakkavu, Kozhikode, Kerala - 673 011, India. E-mail: dr.prithvi.chandrakanth@gmail.com

Received: 13-Oct-2021

Revision: 09-Nov-2021

Accepted: 13-Dec-2021

Published: 22-Mar-2022

## Innovation

### Case report

An 80-year-old female presented to our hospital with defective vision in both eyes (BE) for 1 year. The patient was wheelchair-bound and gave a history of poor mobility due to stroke and hemiplegia [Fig. 1a and b]. She was a known case of type II diabetes mellitus (DM), hypertension, and coronary artery disease (CAD) on treatment. She gave a history of a minor spine deformity due to which her back hunched forward. Her visual acuity (V/A) was light perception (LP) due to the presence of a mature cataract in BE. Ultrasound B-scan in BE revealed a flat retina. She had difficulty getting in or out of the wheelchair unaided and gave a history of sleeping in a sideway position (lateral recumbent position) due to the inability to lie down flat on her back. Attempts made to transfer her to the reclining position were unsuccessful as it was uncomfortable and exhausting for the patient. She was denied cataract surgery due to her medical condition in other hospitals by the surgeon and anesthetists. Her grade of physical status according to the American Society of Anesthesiologists grading system was IV. After a tedious discussion about the forthcoming risks and complications, a decision to attempt the cataract surgery with the patient seated on the wheelchair in an upright position facing the surgeon "face to face" was made under anesthetic stand by [Table 2].

This is an open access journal, and articles are distributed under the terms of the Creative Commons Attribution-NonCommercial-ShareAlike 4.0 License, which allows others to remix, tweak, and build upon the work non-commercially, as long as appropriate credit is given and the new creations are licensed under the identical terms.

**For reprints contact:** WKHLRPMedknow\_reprints@wolterskluwer.com

**Cite this article as:** Brayan J, Chandrakanth P, Narendran S, Narendran K, Narendran V. PHACOSIT: A sitting phacoemulsification technique for patients unable to lie down flat during cataract surgery. Indian J Ophthalmol 2022;70:1396-401.

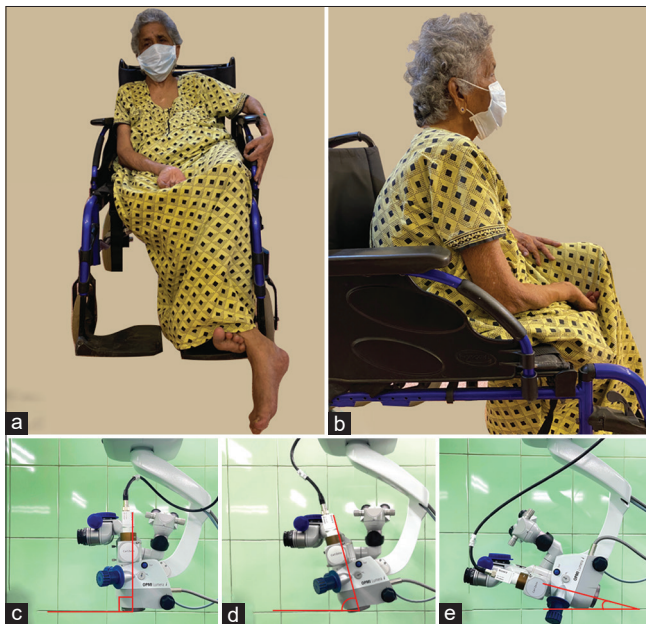
**Table 1: Details of previous techniques**

Author	No of eyes/Patients	Technique
Muraine et al. <sup>[11]</sup>	4 eyes/2 patients	Phacoemulsification by slit lamp in the upright position.
Sohail et al. <sup>[6]</sup>	240 eyes/179 patients	Phacoemulsification by the face-to-face method with the patient sitting semi-upright/upright with neck extended and surgeon in sitting or standing position. Adjustable patient chair, surgeon chair, and microscope were used
Lee et al. <sup>[7]</sup>	32 eyes	Phacoemulsification on a standard reclining operating chair and operating microscope/
Ang et al. <sup>[5]</sup>	2 patients	Phacoemulsification on a semi-recumbent position in a standard reclining cataract surgical chair

**Table 2: Details of the patient who benefited from phacosit**

Female, 80 years  
 Systemic condition: diabetes mellitus, hypertension, coronary artery disease, stroke, hemiplegia

Parameters	Right Eye (OD)	Left Eye (OS)
Pre-op Best Corrected Visual Acuity	LP +	LP +
Pre-op Intraocular Pressure (mm Hg)	12	14
Cataract Diagnosis	Mature Cataract	Mature Cataract
Anesthesia	Subtenon Anesthesia	Subtenon Anesthesia
Axial Length (mm)	21.73	21.80
Intraocular Power (D)	22.00	22.00
Post-op Best Corrected Visual Acuity – 30 days	6/6p	6/6p
Post-Op Best-Corrected Visual Acuity – 60 days	6/6	6/6
Post-Op Best-Corrected Visual Acuity – 90 days	6/6	6/6
Post-op Intraocular Pressure	14	14
Surgery Time (min)	13	10
Phaco CDE	40.02	14.35



**Figure 1:** (a) An 80-year-old wheelchair-bound female patient with a history of right-sided hemiplegia. (b) Lateral view of the patient showing the forward hunch of the back. (c) Reference image of an operating microscope in the vertical axis (90° to the horizontal axis). (d) Operating microscope angulated at 75° to the horizontal axis during routine phacoemulsification surgery (e) Operating microscope angulated at 75° to the vertical axis for the phacosit technique

**Prerequisite**

This technique involved the use of a wheelchair which was made immobile with the help of wheel stoppers. Vitals such as blood pressure, pulse, and SpO<sub>2</sub> were recorded. The cuff of the electronic sphygmomanometer was tied to one arm, and a pulse oximeter was connected to the finger of the other arm to monitor the intra-operative vitals of the patient.

**Microscope adjustment**

A Zeiss OPMI VISU 210 S88 operating microscope was used for this surgery which had the provision to adjust the microscope at various angles. In this case, we adjusted the operating microscope at an angle of approximately 70°–80° from the vertical plane. This angulation enabled the microscope to face the patient’s axis of the eye correctly [Fig. 1c–e].

**Positioning of the patient**

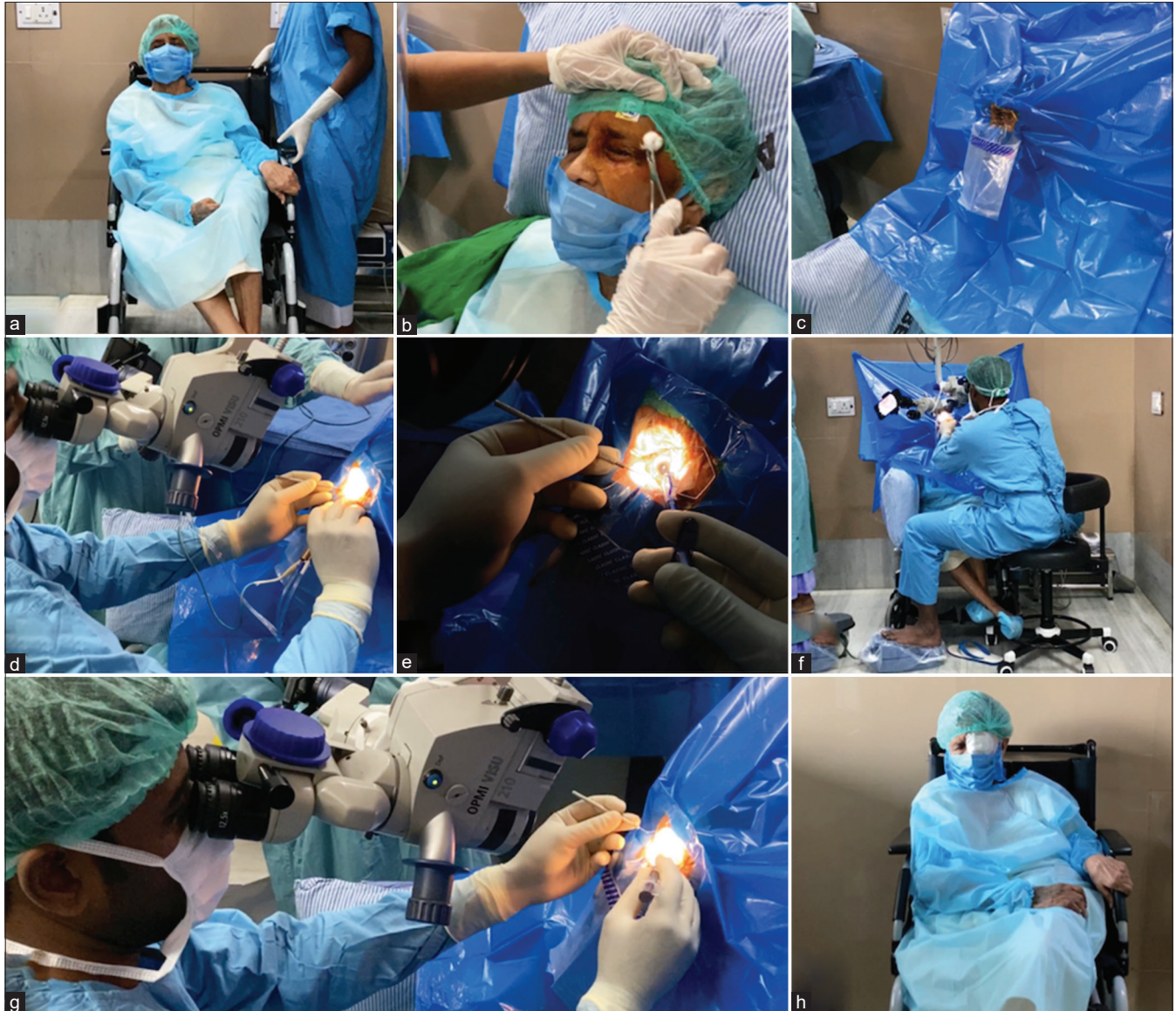
A sterile plastic surgical drape was stuck on one part of the operation theater wall to maintain asepsis. The patient was seated on a wheelchair chair placed against the surgically draped wall. Pillows were placed to rest her arms and head comfortably on the chair. Vitals were recorded at regular intervals [Table 3, Fig. 2a].

**Surgeon**

The surgeon sat on a height-adjustable chair facing the patient’s face and adjusted the chair height according to the patient’s position. The surgeon performed the surgery with outstretched arms.

**Table 3: Systemic analysis of the patient benefited by phacosit**

Parameters	Right Eye Surgery			Left Eye Surgery		
	Pre-Operative	Intra-Operative	Post-Operative	Pre-Operative	Intra-Operative	Post-Operative
Blood Pressure (mm Hg)	140/70	160/70	160/90	170/80	150/70	160/80
Pulse (bpm)	80	80	86	84	87	86
SPO <sub>2</sub> (%)	98	97	98	98	97	99

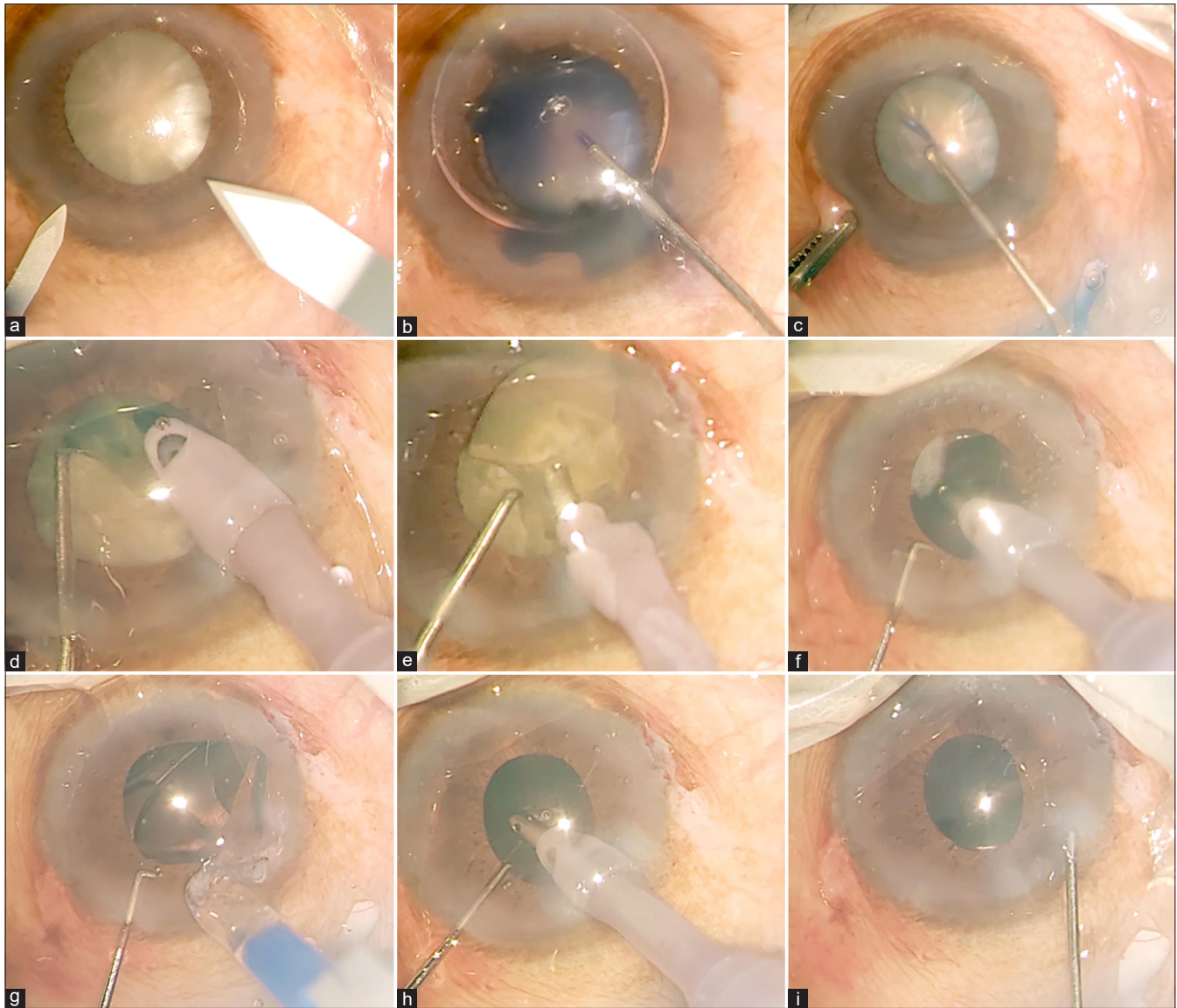


**Figure 2:** (a) Patient sitting on the wheelchair against the operating theater wall. (b) Prepping of the left eye using betadine solution. (c) Drapping of the left eye with inferiorly placed fluid collection bag. (d-g) Phacoemulsification with intraocular lens implantation via inferior approach with face-to-face sitting position of the surgeon and patient. (h) Patient in the post-operative ward

### Surgery

Alcon INFINITI™ System (phacoemulsification machine) was used in this technique. No new changes were made in the setting or the bottle height of the machine from the routine phacoemulsification technique. The surgery was performed in the left eye (LE) under the sub-tenons anesthesia. Her LE was instilled with 5% povidone-iodine drops, and the lids

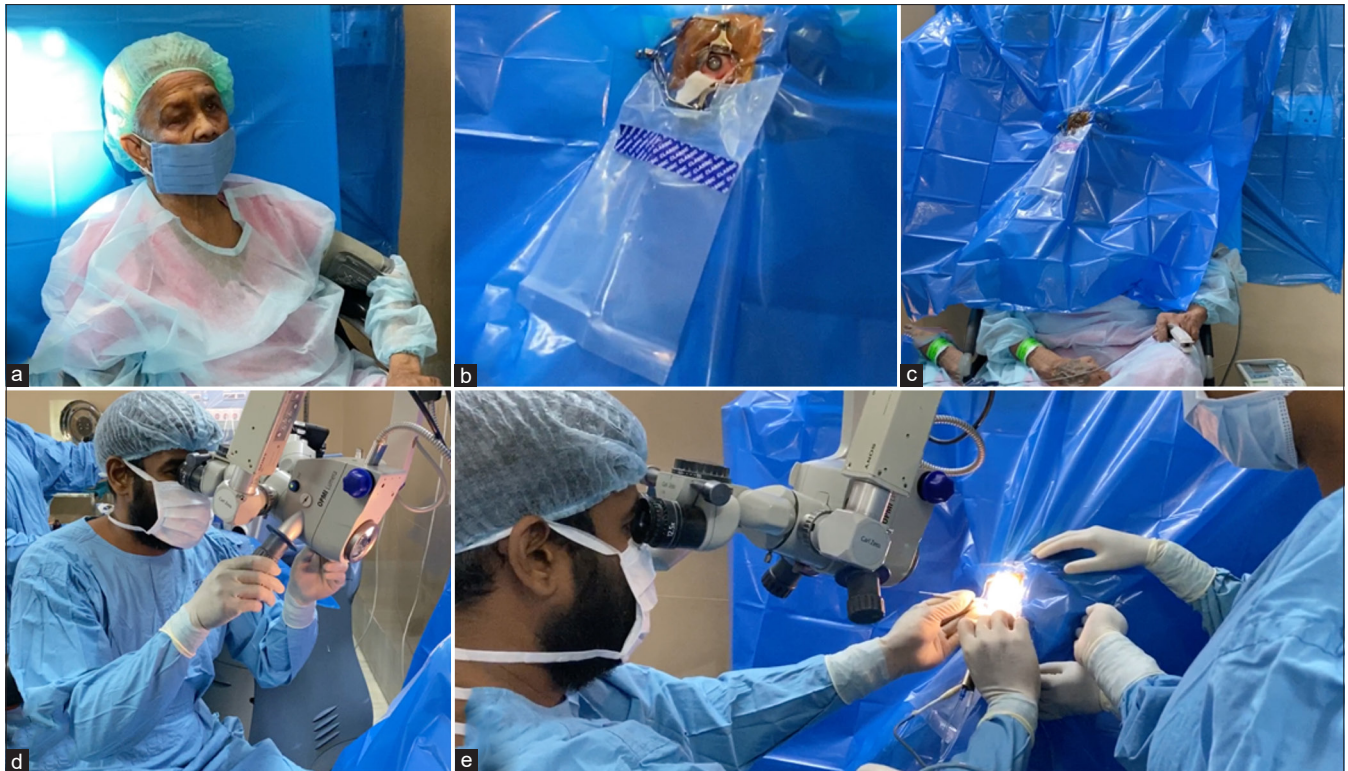
were prepped with 10% povidone-iodine solution [Fig. 2b]. A sterile plastic surgical drape was used to cover the other eye, face, and trunk of the patient by sticking the upper outer ends to the surgically draped wall. A universal wire speculum was placed on the left eye to keep it open throughout the surgery. The fluid collecting bag was stuck on the draped sheet inferiorly [Fig. 2c]. The surgeon sat on the



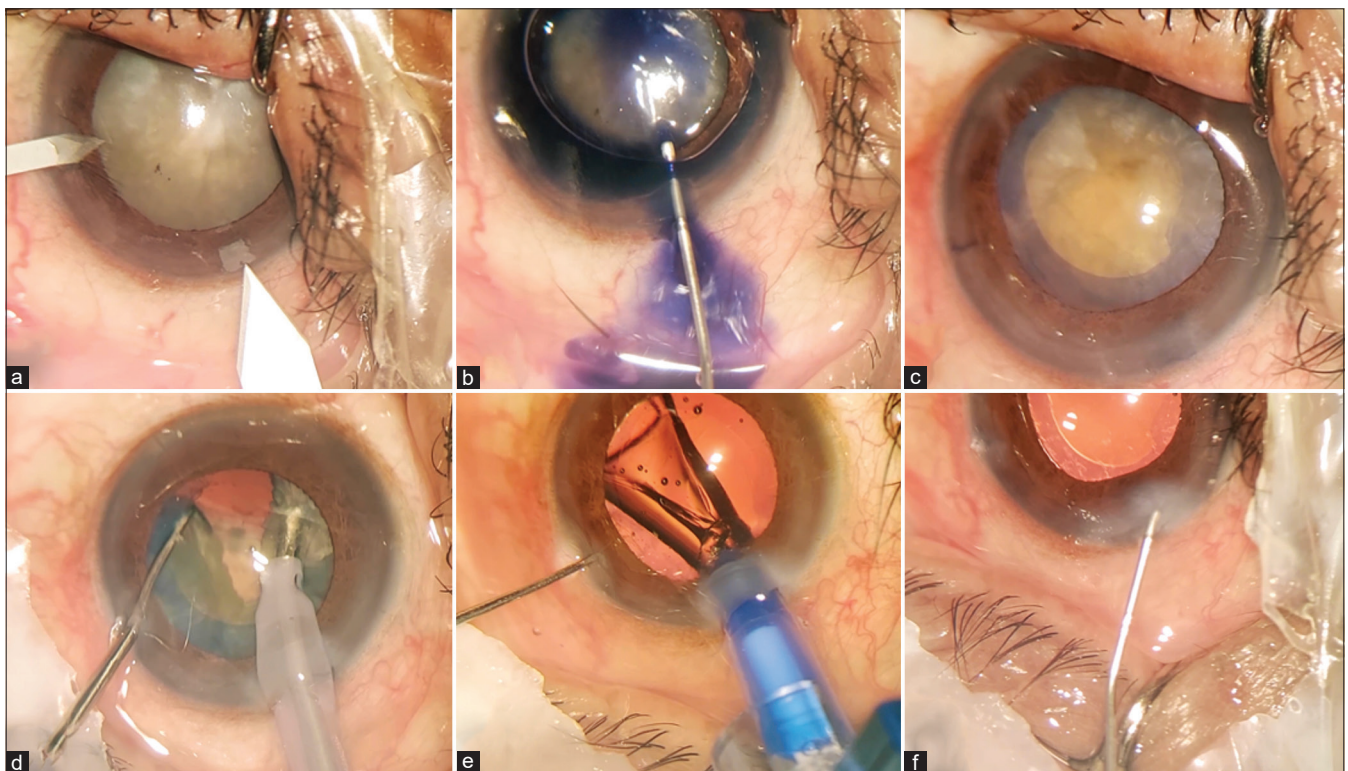
**Figure 3:** (a) An inferior self-sealing 2.8-mm clear corneal incision was made infero-temporally at 4 o'clock and a 1-mm-sized side port was made at the 7-o'clock position. (b) Staining of the anterior capsule with trypan blue. (c) Capsulorhexis being performed using a cystitome needle using high-molecular-weight ophthalmic viscosurgical devices. (OVD) (d and e) Routine phacoemulsification technique by using the direct chop technique using a 2-mm vertical chopper. (f) Cortex wash was performed using a coaxial irrigation aspiration probe. (g) Foldable IOL implantation. (h) Anterior chamber wash. (i) Stromal hydration to form the anterior chamber

height-adjusted chair facing the patient's face in an upright erect position. The surgery was performed with the surgeon's outstretched arms [Fig. 2d-g]. An inferior approach was performed for this surgery. An inferior self-sealing 2.8-mm clear corneal incision was made infero-temporally (4 o'clock). A 1-mm-sized side port was made at the 7-o'clock position [Fig. 3a]. The anterior capsule was stained with trypan blue dye [Fig. 3b]. Capsulorhexis was performed using a cystitome needle using high-molecular-weight ophthalmic viscosurgical devices (OVD) [Fig. 3c]. Multiple bouts of hydro dissection were given followed by nucleus rotation. Routine phacoemulsification technique by using the direct chop technique was done using a 2-mm vertical chopper [Fig. 3d and e]. Cortex wash was performed using a coaxial irrigation aspiration probe [Fig. 3f]. After injecting

OVD, a single foldable IOL was placed in the bag [Fig. 3g]. Anterior chamber was formed, intracameral moxifloxacin was injected, and the incision site was hydrated [Fig. 3h, i]. No sutures were placed. The left eye was patched, and the patient was shifted to the post-operative ward [Fig. 2h]. The post-operative vitals were assessed and recorded. Both the patient and the surgeon were comfortable throughout the surgery. Surgery and recovery were uneventful. One month later, the fellow eye (right eye) having a mature cataract was taken up for surgery by using the same arrangements and technique [Figs. 4 and 5]. We used a self-retaining Barraquer eye speculum for the right eye. The patient was happy and satisfied with the visual outcome, with an uncorrected distance visual acuity of 6/9p in both eyes, which improved to 6/6 with correction at 90 days.



**Figure 4:** (a) Patient with RE subtenon anesthesia sitting on the wheelchair against the wall. (b and c) Prepping and draping of the RE. (d) Operating microscope angulated at 75° to the vertical axis for the phacosit technique. (e) Phacoemulsification being done in the sitting position



**Figure 5:** (a) Clear corneal incision. (b) Trypan blue injection to the anterior chamber. (c) Complete capsulorhexis. (d) Phacoemulsification by using the direct chop technique with the help of a 2-mm vertical chopper. (e) Foldable IOL implantation. (f) Stromal hydration to form the anterior chamber

## Discussion

Phacoemulsification is routinely performed with the patient lying supine on the surgical table with his or her head flat and facing the overhead microscope to optimize the red reflex and surgical view for the operating surgeon. This routine position can be a challenge in medical conditions such as kyphosis, scoliosis, orthopnea, Meniere's disease, and CNS abnormality.<sup>[3-8]</sup> Some cardiovascular and respiratory conditions make the patients breathless when they lie down, whereas patients with some other neurological and spinal problems are also equally uncomfortable. In some extreme cases, the patient has a high risk of death if made to lie flat for any length of time. Usually, these patients have poor functioning of the heart, lungs, or muscles, making them unsuitable or at high risk for general anesthesia. The patient's quality of life is compromised due to the worsening cataract and poor visual acuity if the surgery is deferred because of the above reasons.<sup>[8,9]</sup>

The only reasonable solution to conduct surgery on a patient who cannot lie down flat on the operating table is to position them face to face in a sitting position. This technique allows cataract surgery to be done in patients who might otherwise be considered unfit for surgery because of their inability to lie in a supine position. We coined the term for this technique as phacosit.

Our patient with BE mature cataract was denied cataract surgery by various ophthalmologists due to her medical condition, which compromised her quality of life. Phacosit was the only reasonable option for surgery because of the high risks associated with general anesthesia.

This technique modifies the standard operating equipment that is readily available in the ophthalmic operation theater. No additional instruments and attachments are required for this technique. This technique should be attempted only by experienced cataract surgeons as it is done at an unfamiliar angle with outstretched arms. It is preferable for the surgeon to sit at the same side of the operating eye. It is important to ensure both surgeon and patient are comfortable before starting the surgery. The inferior approach method of phacoemulsification is unconventional with no previous study reports regarding the technique and its complications. The patient was explained about the guarded visual prognosis and a high risk of posterior capsular rupture or dropped nucleus fragments. The positioning of the RE phacosit technique cataract surgery was slightly more time-consuming and challenging for the surgeon when compared to the LE. Any potential surgical complication risk should be weighed against the disadvantages of general anesthesia usage. The patient was happy and satisfied with the good post-operative VA after 1 years of blindness, which outweighed the risks taken by the surgeon.

There is no previous study in the literature that has reported a technique with the patient seated completely upright in a chair and facing the operating microscope during cataract surgery.

## Conclusion

Phacosit is an innovative and valuable technique of performing phacoemulsification with IOL implantation in a sitting position for patients who are unable to lie flat on their back. In some patients with respiratory, cardiac, and spine problems, face-to-face surgery in a sitting position is the only viable option

who would otherwise be obliged to remain visually impaired in the rest of their lives.

## Acknowledgment

Dr. Hirika Gosalia, DNB, Aravind Eye Hospital, Coimbatore.

Mrs. Gurudevi, Mrs. Satya, Mrs. Subhulakshmi, Miss Nagajothi, Miss Chitra, Nursing staff, Aravind Eye Hospital, Udumalpet.

## Declaration of patient consent

The authors certify that they have obtained all appropriate patient consent forms. In the form the patient(s) has/have given his/her/their consent for his/her/their images and other clinical information to be reported in the journal. The patients understand that their names and initials will not be published and due efforts will be made to conceal their identity, but anonymity cannot be guaranteed.

## Financial support and sponsorship

Nil.

## Conflicts of interest

There are no conflicts of interest.

## References

1. Kelman CD. Phaco-emulsification and aspiration: A new technique of cataract removal: A preliminary report. *Am J Ophthalmol* 1967;64:23-35.
2. Honavar SG. "Indovation" in ophthalmology – The potential power of frugal innovations. *Indian J Ophthalmol* 2019;67:447-8.
3. Rogers GM, Goins KM. Cataract surgery in the patient that cannot lie flat. *Curr Opin Ophthalmol* 2010;21:71-4.
4. Pajaujis M, Injarie A, Eke T. Extreme face-to-face positioning for cataract surgery with patient seated upright in motorized wheelchair. *J Cataract Refract Surg* 2013;39:804-5.
5. Ang GS, Ong JM, Eke T. Face-to-face seated positioning for phacoemulsification in patients unable to lie flat for cataract surgery. *Am J Ophthalmol* 2006;141:1151-2.
6. Sohail T, Pajaujis M, Crawford SE, Chan JW, Eke T. Face-to-face upright seated positioning for cataract surgery in patients unable to lie flat: Case series of 240 consecutive phacoemulsifications. *J Cataract Refract Surg* 2018;44:1116-22.
7. Lee RMH, Jehle T, Eke T. Face-to-face upright seated positioning for cataract surgery in patients who cannot lie flat. *J Cataract Refract Surg* 2011;37:805-9.
8. Fine IH, Hoffman RS, Binstock S. Phacoemulsification performed in a modified waiting room chair. *J Cataract Refract Surg* 1996;22:1408-10.
9. Eke T. Side-saddle cataract surgery for patients unable to lie flat: Learning from the past [letter]. *Eye (Lond)* 2008;22:860; reply by J Nair, T Rimmer, 860.
10. Nair J, Rimmer T. Side saddle cataract surgery flat: Learning from the past [letter]. *Eye* 2007;21:1122-3.
11. Muraine M, Boutillier G, Toubeau D, Gueudry J. Face-to-face phacoemulsification using a slitlamp in patients who are unable to lie flat. *J Cataract Refract Surg* 2019;45:1535-8.
12. Hunter LH. Standing while performing phacoemulsification (letter). *J Cataract Refract Surg* 1995;21:111.
13. Liu C. Phacoemulsification in a patient with torticollis (letter). *J Cataract Refract Surg* 1995;21:364.
14. Pandey SK, Sharma V. Phacoemulsification in Postural Disorders [Internet]. *CRSToday*. 2021. Available from: <https://crstoday.com/articles/2016-apr/phacoemulsification-in-postural-disorders/>. [Last accessed on 2021 Nov 25].