

# Septal myectomy complicated by an embolic stroke in a patient with hypertrophic cardiomyopathy: a case report

Muhammad Umer Butt<sup>1</sup>, Anas Alameh <sup>2</sup>, Hanad Bashir <sup>2\*</sup>, and Ahmad Jabri <sup>1</sup>

<sup>1</sup>Heart and Vascular Institute, Case Western Reserve University, 2500 MetroHealth Drive A107 Cleveland, Ohio 44109, USA; and <sup>2</sup>Department of Internal Medicine, Cleveland Clinic Akron General, 1 Akron General Ave. Akron, Ohio 44307, USA

Received 8 February 2021; first decision 10 March 2021; accepted 27 August 2021; online publish-ahead-of-print 23 September 2021

## Background

Hypertrophic cardiomyopathy is estimated to affect 1 out of every 500 adults in the USA. One of its main complications is left ventricular outflow obstruction, which may require surgical septal myectomy in severe cases. We report a rare complication of postoperative septal akinesis leading to thrombus formation presenting as an acute ischaemic stroke.

## Case summary

A 48-year-old woman presented with acute stroke 2 years after surgical septal myectomy for hypertrophic obstructive cardiomyopathy. Diagnostic workup identified an intraventricular thrombus arising in the left ventricular outflow tract (LVOT). After comprehensive evaluation, it was determined that the thrombus development was a complication of the prior septal myectomy causing focal septal akinesis. Treatment with anticoagulation resulted in improvement of neurological symptoms and resolution of the intraventricular thrombus.

## Discussion

This case illustrates the rarity and unusual presentation of an intracardiac thrombus that arises from septal myectomy site. A thrombus arising in the LVOT, which is characterized by high gradient laminar flow, is highly unusual. This suggests microscopic and macroscopic alteration in the ventricular septal wall structure, as evident by the septal wall akinesis seen on echocardiography. Recognition of this complication is critical to the selection of appropriate anticoagulation as secondary stroke prevention in these patients.

## Keywords

Hypertrophic cardiomyopathy • Embolic stroke • Intraventricular thrombus • Anticoagulation • Case report

## Learning points

- To recognize the risk of intraventricular thrombus formation associated with surgical septal myectomy, resulting in acute stroke.
- To understand the pathophysiology of thrombus formation associated with post-surgical septal akinesis, and its implication on starting anticoagulation.

## Introduction

Hypertrophic cardiomyopathy is the most common inherited cardiac disease, affecting more than 1 in 500 adults in the USA. It is characterized by a load-independent increase in left ventricular wall thickness with a non-dilated left ventricle.<sup>1</sup> This can lead to obstruction of the blood flowing through the left ventricular outflow tract (LVOT). Clinical manifestations of hypertrophic cardiomyopathy are heterogeneous and may range from asymptomatic ventricular hypertrophy

\* Corresponding author. Tel: 3302125591, Email: [bashirh2@ccf.org](mailto:bashirh2@ccf.org)

Handling Editor: Belinda Gray

Peer-reviewers: Giacomo Tini Melato and Tina Khan

Compliance Editor: Stefan Simovic

Supplementary Material Editor: Vishal Shahil Mehta

© The Author(s) 2021. Published by Oxford University Press on behalf of the European Society of Cardiology.

This is an Open Access article distributed under the terms of the Creative Commons Attribution-NonCommercial License (<https://creativecommons.org/licenses/by-nc/4.0/>), which permits non-commercial re-use, distribution, and reproduction in any medium, provided the original work is properly cited. For commercial re-use, please contact [journals.permissions@oup.com](mailto:journals.permissions@oup.com)

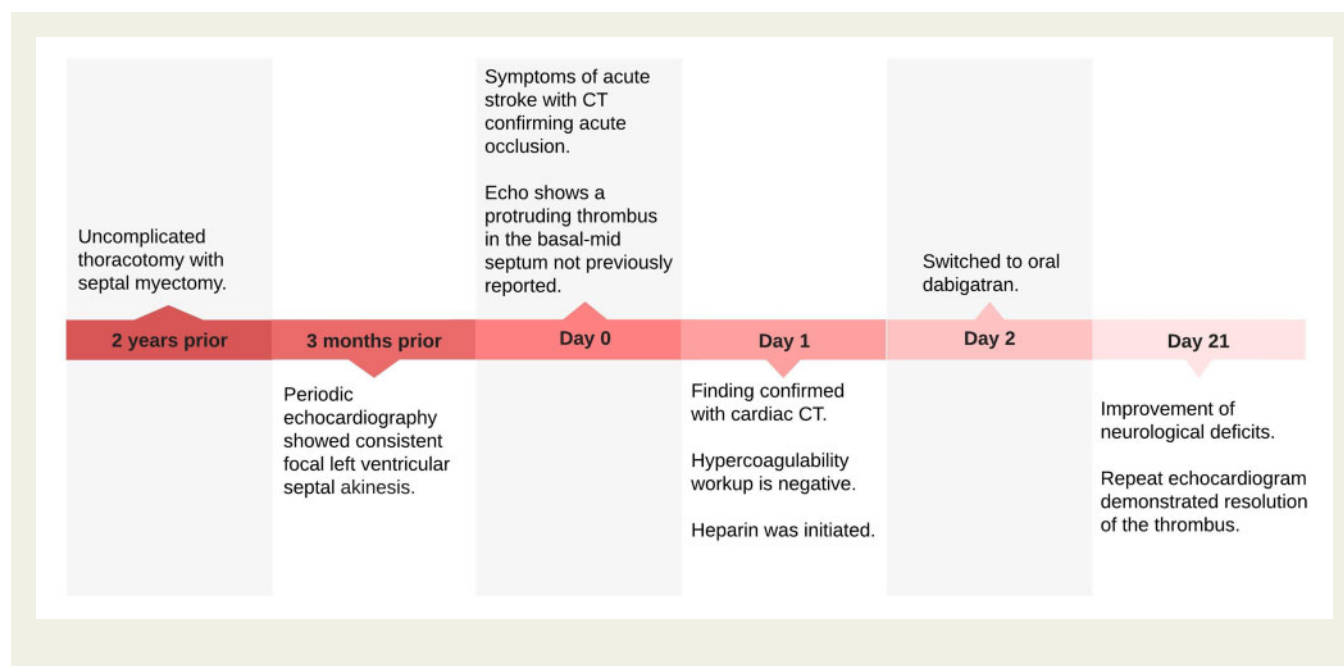
to severe symptoms related to LVOT obstruction or even sudden cardiac death.<sup>2</sup>

Medical management with beta blockers or calcium channel blockers is the mainstay therapy for symptom relief.<sup>3</sup> Surgical septal myectomy, however, is considered the gold standard therapy in cases refractory to medical therapy. Multiple studies have shown septal myectomy to be highly effective with low complication rates.<sup>4</sup> The main complications reported in the literature include conduction abnormalities, aortic regurgitation, and ventricular septal defects.<sup>5</sup> This case report presents the development of a thromboembolic event related to septal myectomy leading to an acute stroke, a complication that has seldom been reported in the literature.

The patient had stable vital signs. National Institutes of Health Stroke Scale (NIHSS) was 8, and her exam revealed expressive aphasia with flaccid right upper and lower extremities. Lab work were within normal limits. The rest of her physical exam was unremarkable. Electrocardiogram did not show any acute ischaemic changes, bundle branch blocks, or dysrhythmias. Computed tomography (CT) and CT angiography of the head and neck revealed an acute occlusion of the left sylvian branch of the middle cerebral artery, with an acute infarction of the left insula and the left frontal corona radiata.

She was not a candidate for thrombolytic therapy and was subsequently started on dual-antiplatelet therapy with aspirin 81 mg daily and clopidogrel 75 mg daily. She was admitted to the neurological in-

## Timeline



## Case presentation

A 48-year-old African American female with a past medical history of hypertrophic obstructive cardiomyopathy (HOCM), obesity, hypertension, hyperlipidaemia, and diabetes mellitus. She underwent uncomplicated thoracotomy with septal myectomy 2 years prior to this presentation, in which 11.0 g of excised myocardium was removed leading to a significant improvement in her LVOT obstruction with no residual valvular dysfunction. The postoperative course was uneventful. She presented with acute stroke and her symptoms included slurred speech, right facial droop sparing the forehead, and right-sided hemiparesis/hemianaesthesia. Previously, the patient had stable follow-up with postoperative echocardiograms showing a normal left ventricular ejection fraction of 70%, with a regional wall motion abnormality characterized by akinesia of the basal anteroseptal, mid anteroseptal, basal and mid inferior wall, and basal and mid inferior septum. The last echocardiogram was performed 3 months prior to this presentation.

tensive care unit for further workup. Echocardiogram demonstrated an ejection fraction of 55% with a focally abnormal left ventricular function and akinesia of the basal, mid anterior, and inferior septum consistent with her prior echocardiograms. However, there was a protruding density not previously reported in the basal-mid interventricular septum, measuring 2.2 × 1.4 cm (Figure 1). It had multiple associated sessile, mobile projections with poor perfusion pattern on definity contrast enhanced imaging, visualized at the site of the remote myomectomy (Figure 2). Cardiac magnetic resonance imaging was attempted to further characterize the lesion; however, it was unsuccessful due to the patient body habitus. Electrocardiogram-gated contrast cardiac CT was then performed and revealed an ovoid hypodensity arising from the septal wall of the left ventricle, with no contrast enhancement and low Hounsfield units (Figure 3). Given the septal akinesia, coronary angiography was performed to rule out ischaemia and showed normal coronary arteries with no evidence of obstruction.

Based on the lesion's atypical location in the LVOT, its origin at the former myectomy site, and poor perfusion on definity contrast study, the final diagnosis was acute cardioembolic stroke secondary to a left ventricular thrombus. Notably, the patient had no previous history of thromboembolic events and work-up for a possible underlying hypercoagulopathy state was negative. It was therefore deemed appropriate to commence anticoagulation with heparin and there was subsequently no evidence of bleeding. She was successfully transitioned to oral dabigatran 150 mg twice a day and discharged in a stable condition. Her neurologic deficits improved and echocardiography 3 weeks later demonstrated resolution of the thrombus (Figure 4).

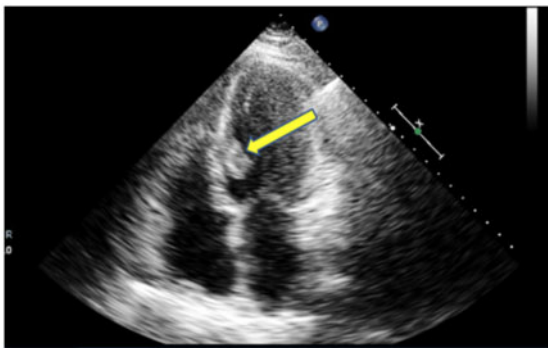
## Discussion

This case illustrates a rare presentation of an intracardiac thrombus arising from septal myectomy site. Known predisposing factors for new-onset ventricular thrombus are acute myocardial infarction,

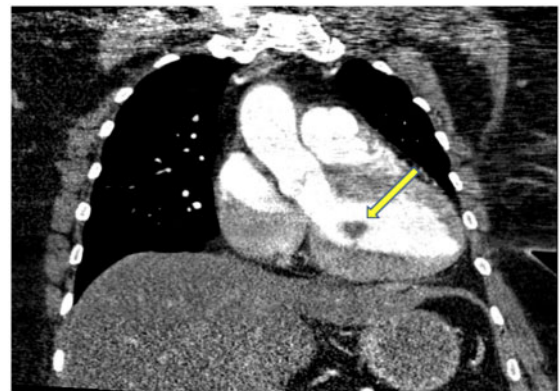
dilated cardiomyopathy, and severely low ejection fraction heart failure.<sup>6,7</sup> The common underlying mechanism is flow stasis that results from wall motion abnormalities and changes in the anatomical ventricular wall structure.

In this patient's case, chronic ventricular septal wall akinesis was documented on serial echocardiograms, resulting in a focal left ventricular systolic dysfunction most notable at the middle-anterior and inferior parts of the septum. This is believed to be the main predisposing factor for the thrombus formation. Ventricular septal wall akinesis has been reported in literature as one of the adverse sequelae of septal myectomy, commonly along the apical end of the left ventricular wall.<sup>8</sup> This subsequently produces a similar effect of blood stasis that is observed with severely low ejection fractions or extensive myocardial infarctions.

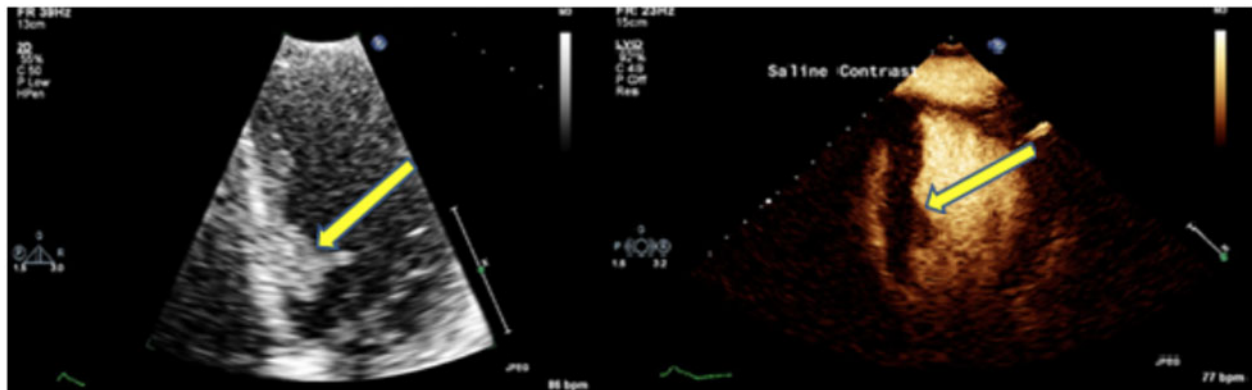
The location of this patient's intraventricular thrombus, however, at the mid-basal ventricular septum with upward projection to the LVOT is unusual. The natural anatomy of the LVOT provides a high-



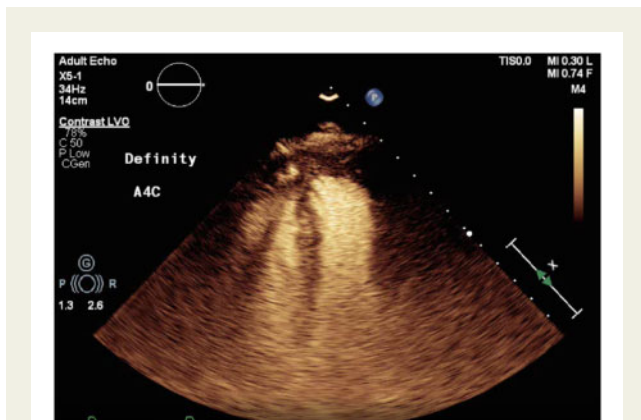
**Figure 1** Transthoracic echocardiogram: a protruding density in the basal-mid interventricular septum can be seen, measuring  $2.2 \times 1.4$  cm at the site of the remote myectomy.



**Figure 3** Electrocardiogram-gated contrast cardiac computed tomography: ovoid hypodensity arising from the septal wall of the left ventricle can be seen, with no contrast enhancement.



**Figure 2** Contrast enhanced echocardiogram: multiple sessile projections can be seen outlining the borders of the protruding density, with poor perfusion pattern.



**Figure 4** Contrast enhanced echocardiogram: 3-week follow-up reveals resolution of the thrombus.

gradient, laminar blood flow, which has protective effect against thrombus formation. A thrombus arising from the septal wall with protrusion into this directional flow is rare and scarcely reported in literature. This suggests microscopic and macroscopic alteration in the ventricular septal wall structure, as evident by the aforementioned wall akinesis. More importantly, the lesion's location at the LVOT implies a possible turbulent flow with underlying hypercoagulable state contributing to the rapid thrombus formation. The patient's hypercoagulability workup was nonetheless negative.

Recognition of this complication is critical for initiation of appropriate anticoagulation for secondary stroke prevention. The choice of anticoagulation in our patient is attributed to the intracardiac thrombus being the primary aetiology of her ischaemic stroke. Despite having a moderate risk of post-ischaemic haemorrhagic transformation, the benefit of anticoagulation was deemed to outweigh the risks in light of severe neurological debility. A direct oral anticoagulant (DOAC) was chosen due to the increasing data demonstrating a comparable benefit between warfarin and DOAC.<sup>9,10</sup> Dabigatran was started due to the availability of its reversal agent should there be a need to reverse its effect in the setting of haemorrhagic transformation.

## Conclusion

This case illustrates the rarity and unusual presentation of an intracardiac thrombus that arises from septal myectomy site. Traditionally, predisposing factors for left ventricular thrombus are acute myocardial infarction, dilated cardiomyopathy, and heart failure in the setting of flow stasis and wall motion abnormality. Our patient has chronic ventricular septal wall akinesis from prior myomectomy; however, the lesion's location at high-gradient and turbulent LVOT evident by echocardiography is unexpected and has been scarcely documented in literature. Recognition of this complication is critical to the selection of appropriate anticoagulation as secondary stroke prevention in these patients.

## Lead author biography



Mohammed Umer Butt is current fellow at Case Western Reserve University MetroHealth. Completed his medical training at King Edward Medical University and Internal Medicine Residency at SUNY Buffalo Affiliated Hospitals.

## Supplementary material

[Supplementary material](#) is available at *European Heart Journal - Case Reports* online.

**Slide sets:** A fully edited slide set detailing this case and suitable for local presentation is available online as [Supplementary data](#).

**Consent:** The authors confirm that written consent for submission and publication of this case report including images and associated text has been obtained from the patient in line with COPE guidance.

**Conflict of interest:** None declared.

**Funding:** None declared.

## Acknowledgements

This case has not presented previously, and we have no contributions to declare.

All authors contributed equally to this work.

## References

1. Maron BJ. Hypertrophic cardiomyopathy: a systematic review. *JAMA* 2002;**287**: 1308–1320.
2. Maron MS, Olivetto I, Betocchi S, Casey SA, Lesser JR, Losi MA et al. Effect of left ventricular outflow tract obstruction on clinical outcome in hypertrophic cardiomyopathy. *N Engl J Med* 2003;**348**:295–303.
3. Harris C, Croce B, Munkholm-Larsen S. Hypertrophic obstructive cardiomyopathy. *Ann Cardiothorac Surg* 2017;**6**:429–429.
4. Ommen SR, Maron BJ, Olivetto I, Maron MS, Cecchi F, Betocchi S et al. Long-term effects of surgical septal myectomy on survival in patients with obstructive hypertrophic cardiomyopathy. *J Am Coll Cardiol* 2005;**46**: 470–476.
5. Gersh BJ, Maron BJ, Bonow RO, Dearani JA, Fifer MA, Link MS et al. 2011 ACCF/AHA guideline for the diagnosis and treatment of hypertrophic cardiomyopathy: A report of the American College of Cardiology Foundation/American Heart Association Task Force on Practice Guidelines. Developed in Collaboration with the American Association for Thoracic Surgery, American Society of Echocardiography, American Society of Nuclear Cardiology, Heart Failure Society of America, Heart Rhythm Society, Society for Cardiovascular Angiography and Interventions, and Society of Thoracic Surgeons. *J Am Coll Cardiol* 2011;**58**:e212–60.
6. Palka I, Nessler J, Nessler B, Piwowarska W, Tracz W, Undas A et al. Altered fibrin clot properties in patients with chronic heart failure and sinus rhythm: a novel prothrombotic mechanism. *Heart* 2010;**96**:1114–1118.

- 
7. Bobbert P, Weikert U, Schmidt-Lucke C, Skurk C, Meyer A, Steffens D et al. Platelet activation and thrombus formation relates to the presence of myocardial inflammation in patients with cardiomyopathy. *J Cardiol* 2014;**63**:379–384.
  8. Kotkar KD, Said SM, Dearani JA, Schaff HV. Hypertrophic obstructive cardiomyopathy: the Mayo Clinic experience. *Ann Cardiothorac Surg* 2017;**6**: 329–336.
  9. Kaja M, Shokr M, Ramappa P. Use of direct oral anticoagulants in the treatment of left ventricular thrombus: systematic review of current literature. *Am J Ther* 2019;**7**:1.
  10. Fleddermann AM, Hayes CH, Magalski A, Main ML. Efficacy of direct acting oral anticoagulants in treatment of left ventricular thrombus. *Am J Cardiol* 2019;**124**: 367–372.