

Fibro-osseous pseudotumor of the digit

Mohammad Javdan, Mohammad Ali Tahririan

Department of Orthopedics, Medical University of Isfahan, Kashani Hospital, Iran

Abstract

Fibro-osseous pseudotumor of the digit is an unusual ossifying soft tissue lesion, which is usually an ill-defined soft tissue mass in radiography, with focal calcification, especially in the proximal phalanx. It predominantly affects young adults and, unlike myositis ossificans, is more common in women. The current case is a 30-year-old man who presented with pain and swelling on the dorsum of middle phalanx of the left index finger without history of trauma. Diagnosis of this lesion requires a high index of suspicion and should be differentiated from myositis ossificans, turret exostosis, and extra-skeletal osteosarcoma, which are discussed. This lesion is considered benign and has an excellent prognosis following complete removal and local recurrence is unusual. No cases of malignant change are on record.

Key Words: Digit, fibro-osseous pseudotumor, heterotopic ossification, soft tissue lesion

Address for correspondence:

Assistant professor Mohammad Ali Tahririan, Department of Orthopedics, Isfahan Medical University, Kashani Hospital, Iran. E-mail: tahririan@med.mui.ac.ir

Received: 25.12.2011, Accepted: 26.12.2011

INTRODUCTION

Fibro-osseous pseudotumor of the digit is an uncommon subcutaneous mass that usually occurs in young women, and it appears with pain and swelling of a finger. This mass should be differentiated from myositis ossificans, Turret exostosis, and extraskelatal osteosarcoma.

CASE REPORT

A 30-year-old male patient presented to our clinic with a history of tender swelling on the dorsum of middle phalanx of left index finger. The patient noted the mass since 12 months, which gradually became larger.

The mass was 13 mm in diameter [Figure 1], with mild tenderness and firm in palpation, slightly mobile and, without marked movement on interphalangeal motion, and no obvious adhesion to adjacent skin. The sensation of the finger was normal. Flexor and extensor tendons were intact; however, finger motion was slightly limited.

There was no history of major trauma, sharp injury, infection, or constitutional symptoms such as malaise, fever, or weight loss. Laboratory tests (CBC diff, ESR, CRP, Ca, P, Alk-P) were within normal limit. Tests for tuberculosis, brucella and syphilis were negative. Chest roentgenogram was normal.

Other imaging investigations included simple x-ray and CT-scan of the index finger. Conventional posteroanterior and lateral radiography revealed a paraosteal sclerotic lesion just abutting middle phalanx with bone density similar to adjacent bone and slight periosteal reaction [Figure 2], and further evaluation with CT-scan noted that the lesion has a patchy irregular border without cortical destruction or saucerization and there is no typical zonal pattern in the lesion [Figure 3].

Access this article online	
Quick Response Code:	Website: www.advbiores.net
	DOI: 10.4103/2277-9175.98565

Copyright: © 2012 Javdan. This is an open-access article distributed under the terms of the Creative Commons Attribution License, which permits unrestricted use, distribution, and reproduction in any medium, provided the original author and source are credited.

How to cite this article: Javdan M, Tahririan MA. Fibro-osseous pseudotumor of the digit. Adv Biomed Res 2012;1:31.

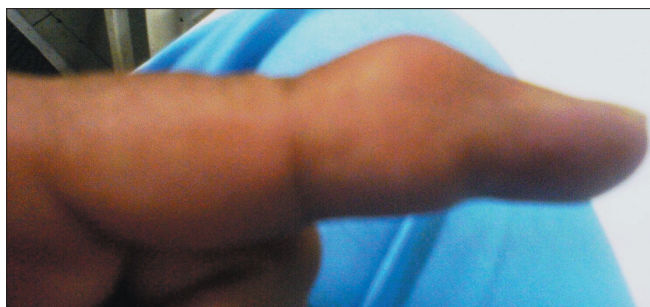

Figure 1: Fusiform mass in dorsal aspect of the index finger

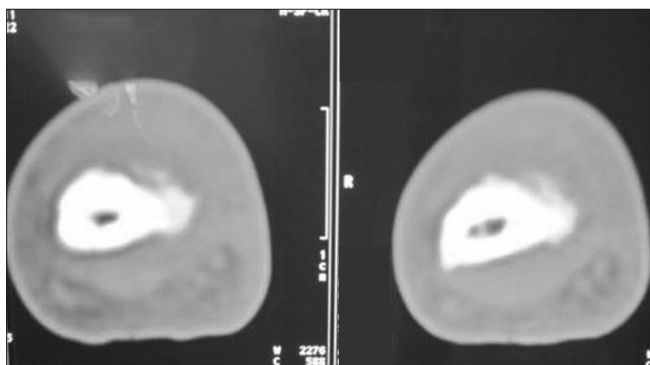


Figure 3: Soft tissue osseous lesion without of the middle phalanx cortical destruction

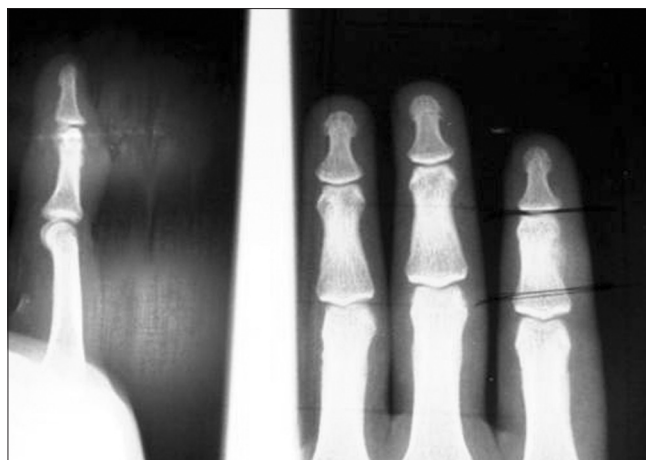

Figure 2: Paraosteal sclerotic lesion

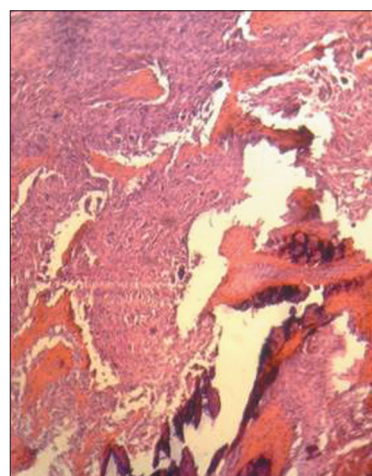


Figure 4: Histopathologic examination revealed proliferation of fibroblasts, dposit of osteoid, osteoblasts, and giant cells

An excisional biopsy with dorsolateral incision was performed. The lesion was 1 × 1 × 1.5 cm in size, white-grayish in color, with hard consistency, and no adhesion to adjacent tendons or soft tissues. Histopathologic examination revealed proliferation of fibroblasts that are loosely arranged, a prominent myxoid matrix, and deposits of osteoid rimmed by uniform osteoblasts. Multinucleated giant cells were also existed [Figure 4].

DISCUSSION

Fibro-osseous pseudo-tumor of the digit (FPOD), a heterotopic ossification that is closely related to myositis ossificans, occurs in the subcutaneous tissue of digit. It is an unusual case that has been described under various names, including pseudo-malignant osseous tumor of the soft tissues,^[1] florid reactive periostitis of the tubular bones of hands and feet,^[2] and parosteal fasciitis.^[3]

Clinically, this lesion affects young adults, mainly women, and presents as a painful, localized, fusiform, and often erythematous swelling in the soft tissues of the fingers, especially the region of the proximal phalange, and less commonly, the toes.^[4-6] Although history of trauma is not necessary, in the series by Dupree and Enzinger,^[4] a history of trauma was provided only nine of their 21 patients. Similarly,

Spjut and Dorfman,^[2] reported a history of trauma for five of 12 patients.

Roentgenographic examinations reveal relatively considerable soft tissue swelling along with focal calcification that lacks the typical zoning pattern of myositis ossificans.^[4,7,8] There may be thickening of adjacent periosteum, and rare cases erode adjacent bone.^[4,9]

In earlier reports in 1976 Edward *et al.*^[3] recommended wide block excision or ray amputation for such lesions, but according to recent reports after complete excision of the lesion, prognosis is excellent and there is no tendency toward local recurrence. Moreover, there is no evidence of malignant transformation.^[1,4,5,6]

The major differential diagnoses are myositis ossificans, Turret exostosis, and extraskeletal osteosarcoma.

FPOD has histologic and clinical features in common with myositis ossificans. This has led many to consider the two to be synonymous. Myositis ossificans most frequently occurs in young male athletes, although a specific history of trauma is absent in up to 40% of cases.^[10] An elevated ESR and Alk-P can be an accompanying finding, but neither are specific for this entity.^[10,11] Myositis ossificans can sometimes resemble juxtacortical or surface osteosarcomas, particularly if a radiolucent cleft is not clearly present between the lesion and the adjacent cortex.^[12]

In confusing cases, CT nicely delineates the zonal pattern that is classically seen in myositis ossificans. Clinically, and often on MR imaging, osteosarcoma cannot be excluded. The presence of peripheral density at radiography or CT, the presence of an enhancing rim on contrast-enhanced MR imaging, and the demonstration of a radiolucent cleft between the lesion and the neighboring bone are helpful features in differentiating myositis ossificans from osteosarcoma.

Although presentation of extraskelatal osteosarcoma is usually that of enlarging soft tissue mass, it typically occurs in older patients, is slightly more common in male than in female patients and rarely involves the digits, and is characterized by more pleomorphic hypochromatic cells, varying amounts of neoplastic osteoid and bone and atypical mitotic figures.^[4]

Turret exostosis presents as a well-delineated mass attached to the bone surface and histologically there is central located new bone surrounded by a peripheral cap of cartilage.

Therefore, diagnosis of the lesion requires a high index of suspicion and correlation of physical examination and radiographic findings with histologic findings

usually is necessary for definite diagnosis.

ACKNOWLEDGEMENT

The authors thank Reza Tahririan MD, senior resident, department of pathology for reviewing the histopathological specimen and providing a photograph of it.

REFERENCES

1. Patel MR, Desai SS. Pseudomalignant osseous tumor of soft tissue: A case report and review of the literature. *J Hand Surg Am* 1986;11:66-70.
2. Spjut HJ, Dorfman HD. Florid reactive periostitis of the tubular bones of the hands and feet, A benign lesion which may simulate osteosarcoma. *Am J Surg Pathol* 1981;5:423-33.
3. Mc Carthy EF, Ireland DC, Sprague BL, Bonfiglio M. Parosteal (nodular) fasciitis of the hand: A case report. *J Bone Joint Surg Am* 1976;58:714-6.
4. Dupree WB, Enzinger FM. Fibro-osseous pseudotumor of the digits. *Cancer* 1986;58:2103-9.
5. Moosavi CA, Al-Nahar LA, Murphey MD, Fanburg-Smith JC. Fibroosseous pseudotumor of the digit: A clinicopathologic study of 43 new cases. *Ann Diag Pathol* 2008;12:21-8.
6. Tan KB, Tan SH, Aw DC, Lee YS. Fibro-osseous pseudotumor of the digit: Presentation as an enlarging erythematous cutaneous nodule. *Dermatol Online J* 2010;16:7.
7. Saundaram M, Wang L, Rotman M, Howard R, Saboeiro AP. Florid reactive periostitis and bizarre parosteal osteochondromatous proliferation: Pre-biopsy imaging evolution, treatment and outcome. *Skeletal Radiol* 2001;30:192-8.
8. Kransdorf MJ, Meis JM. From the archives of the AFIP. Extraskelatal osseous and cartilaginous tumors of the extremities. *Radiographics* 1993;13:853-84.
9. Howard RF, Slawski DP, Gilula LA. Florid reactive periostitis of the digit with cortical erosion: A case report and review of the literature. *J Hand Surg Am* 1996;21:501-5.
10. Wang SY, Lomasney LM, Demos TC, Hopkinson WJ. Radiologic case study. Traumatic myositis ossificans. *Orthopedics* 1999;22:1000, 991-5.
11. Parikh J, Hyare H, Saifuddin A. The imaging features of post-traumatic myositis ossificans, with emphasis on MRI. *Clin Radiol* 2002;57:1058-66.
12. Amendola MA, Glazer GM, Agha FP, Francis IR, Weatherbee L, Martel W. Myositis ossificans circumscripta: Computed tomographic diagnosis. *Radiology* 1983;149:775-9.

Source of Support: Nil, Conflict of Interest: None declared.