

Repeated Diffuse Alveolar Hemorrhage in a Patient with Hemophilia B

Hajime Kasai¹, Jiro Terada¹, Hiromasa Hoshi², Takashi Urushibara¹, Fumiaki Kato¹,
Rintaro Nishimura¹ and Koichiro Tatsumi¹

Abstract

Diffuse alveolar hemorrhage (DAH) is a life-threatening complication that occurs in association with various diseases including coagulation disorders. In rare cases, it is caused by hemophilia. A 48-year-old man was admitted to our hospital for a third time due to DAH. Although the cause of DAH could not be identified by bronchoscopy or laboratory tests, a good response to corticosteroids suggested idiopathic DAH with pulmonary capillaritis. The patient was diagnosed with hemophilia B based on the results of a detailed inquiry, a mildly prolonged activated partial thromboplastin time, and low factor IX activity. Hemophilia may be an underlying factor that exacerbates the bleeding of patients with DAH, even when they show a good response to corticosteroids.

Key words: diffuse alveolar hemorrhage, hemophilia, corticosteroid

(Intern Med 56: 425-428, 2017)

(DOI: 10.2169/internalmedicine.56.7614)

Introduction

Diffuse alveolar hemorrhage (DAH) is a rare but life-threatening complication of various clinical entities such as connective tissue disease and a small vessel vasculitis (pulmonary capillaritis); it may also be caused by coagulation disorders (1). Hemophilia, which is a recessive, X-linked congenital bleeding disorder, has rarely been reported in association with DAH. Bleeding in patients with hemophilia mostly occurs internally into the joints or muscles (2). Refractory bleeding after invasive procedures or trauma is a major reason to suspect hemophilia. Although hemophilia is usually diagnosed in adolescence, mild or moderate hemophilia may sometimes escape detection until adulthood (3, 4). We herein present the case of a patient with recurrent DAH who was diagnosed with hemophilia B in adulthood.

Case Report

The patient was a 48-year-old man who had previously

been hospitalized due to hemoptysis at 42 years of age. At that time, a chest radiograph and chest computed tomography (CT) revealed diffuse ground-glass opacity (GGO) in the bilateral lung fields (Fig. 1, 2), and a bronchoscopic examination revealed the accumulation of large amounts of blood in the trachea and bronchi (Fig. 3). The patient's bronchoalveolar lavage fluid (BALF) was bloody and contained numerous hemosiderin-laden macrophages. A culture test of the BALF revealed no findings. An electrocardiogram and transthoracic echocardiogram revealed no abnormalities. A questionnaire that was completed at that time did not reveal the patient's hemorrhagic episode or a family history of bleeding disease, with the exception of his younger brother who had been diagnosed with hepatitis C. Furthermore, he had not received any drugs that had the potential to cause DAH. Following the above-mentioned examinations, DAH due to some sort of vasculitis was suspected. Thus, treatment with high-dose intravenous methylprednisolone (1,000 mg daily) for 3 days followed by prednisolone (25 mg daily) was initiated. This relieved his symptoms. Chest CT showed the resolution of the GGO. The patient's prednisolone dose was tapered and eventually discontinued at two-

¹Department of Respiriology, Graduate School of Medicine, Chiba University, Japan and ²Department of Medicine, School of Medicine, Chiba University, Japan

Received for publication April 21, 2016; Accepted for publication June 14, 2016

Correspondence to Dr. Hajime Kasai, daikasai6075@yahoo.co.jp

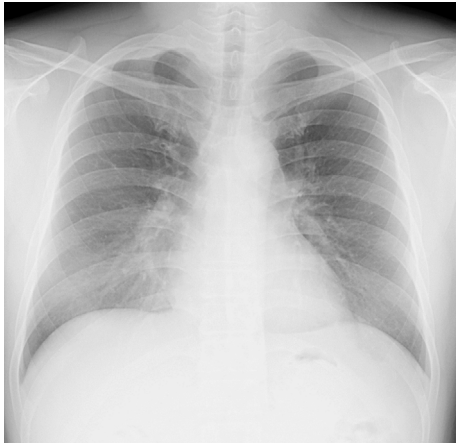


Figure 1. A chest radiograph at the time of the first admission showed the presence of diffuse ground-glass opacity in the bilateral lung fields.

and-a-half years after his discharge from our hospital.

The patient was readmitted to our hospital with a recurrence of hemoptysis at 46 years of age. The above-described therapy was initiated and led to the improvement of his condition. The prednisolone dose was tapered from 60 mg daily to a maintenance dose of 5 mg daily.

At 48 years of age, he was readmitted to our hospital with a further recurrence of hemoptysis. At this point, he had steroid-induced diabetes mellitus, which was treated with glimepiride (3 mg daily). At admission, his weight was 75 kg and height 167 cm; his vital signs were as follows: blood pressure, 178/102 mmHg; pulse rate, 109 beats/min, pulse oximetry, 97% in room air; and body temperature, 36.8°C. Chest auscultation revealed fine crackles in the right lung field. No skin rash, subcutaneous bleeding or joint swelling were present. A chest radiograph and CT showed the presence of diffuse GGO in the bilateral lung fields. Mild anemia was observed (hemoglobin, 11.3 g/dL), although hemoglobin levels had been 14.6 g/dL prior to the hemoptysis episode. The activated partial thromboplastin time (APTT) was prolonged to 53.5 seconds (normal range, 25.1-40.7 seconds). Laboratory tests showed that the patient's blood glucose and hemoglobin A1c levels were 299 mg/dL and 8.2%, respectively, due to the steroid-induced diabetes mellitus. Autoantibodies for various collagen diseases were negative (Table). We diagnosed the condition as a recurrence of DAH and again administered high-dose intravenous methylprednisolone for 3 days, followed by prednisolone (60 mg daily). His condition improved, as had been observed during the previous episodes. A further detailed inquiry regarding the patient's medical history revealed that, as an elementary school student, he had been hospitalized and had received blood transfusions twice following abnormally heavy bleeding after tooth extraction; however, a specific congenital bleeding disorder had not been diagnosed at that time. It was also revealed that his younger brother had been diagnosed with hemophilia B during adolescence. Considering the possibility of hemophilia, his blood coagulation

factors were examined, revealing that his factor IX activity was 3%. The patient was subsequently diagnosed with moderate hemophilia B. By the time of this diagnosis, the patient's DAH had already resolved with the corticosteroid therapy. We decided to continue treating the patient using prednisolone alone, without coagulation factor IX replacement therapy. No recurrence of DAH or hemorrhagic symptoms have been observed during 3 years since the tapering and discontinuation of prednisolone.

Discussion

The present case raises two clinical issues. First, hemophilia can be associated with repeated DAH and may act as an exacerbating factor. Second, in cases with serious bleeding events, such as DAH in the present case, hemophilia may be overlooked in adolescent patients.

Congenital coagulation disorders, including hemophilia, are known to be the rare causes of DAH (1). In general clinical settings, DAH is mainly caused by pulmonary capillaritis in association with systemic autoimmune diseases, pulmonary renal syndromes, and drugs (5, 6). In such cases, treatment with corticosteroids and immunosuppressive agents is often effective. In the present case, the patient's DAH was likely associated with pulmonary capillaritis as it resolved quickly after the initiation of corticosteroid therapy. However, different subtypes of DAH, such as coagulation disorder, mitral stenosis, and acute respiratory distress syndrome, are known to be refractory to corticosteroids and/or immunosuppressive agents. Thus, a careful evaluation is needed in selecting an appropriate treatment for patients with DAH.

Spontaneous hemoptysis as a rare manifestation of DAH in patients with a congenital coagulation disorder. There have only been nine reported cases of hemoptysis occurring with hemophilia; in six of these cases the patients had a concurrent infection (3, 7-12). There have been no reports about the frequency of DAH in patients with hemophilia. Although the exact frequency is not known, it is expected to be extremely low. These results suggest that coagulation defects generally play a secondary role in pulmonary hemorrhage and are not a primary cause (8). The occurrence of hemoptysis in patients with hemophilia and other bleeding disorders may therefore indicate the existence of an associated underlying disease (8).

In the present case, the underlying disease was considered to be some sort of pulmonary capillaritis, with hemophilia B being conducive to bleeding. Corticosteroids are not effective when DAH is caused by hemophilia alone. Hemophilia treatment (other than corticosteroids) was considered for the patient in the present case. Generally, such treatments are determined by the severity of hemophilia, which is classified according to coagulation factor levels as severe (<1%), moderate (1-5%), or mild (5-40%) (13). In cases of moderate hemophilia B, factor IX products are generally replaced at the time that the symptoms appear. In the present case, we

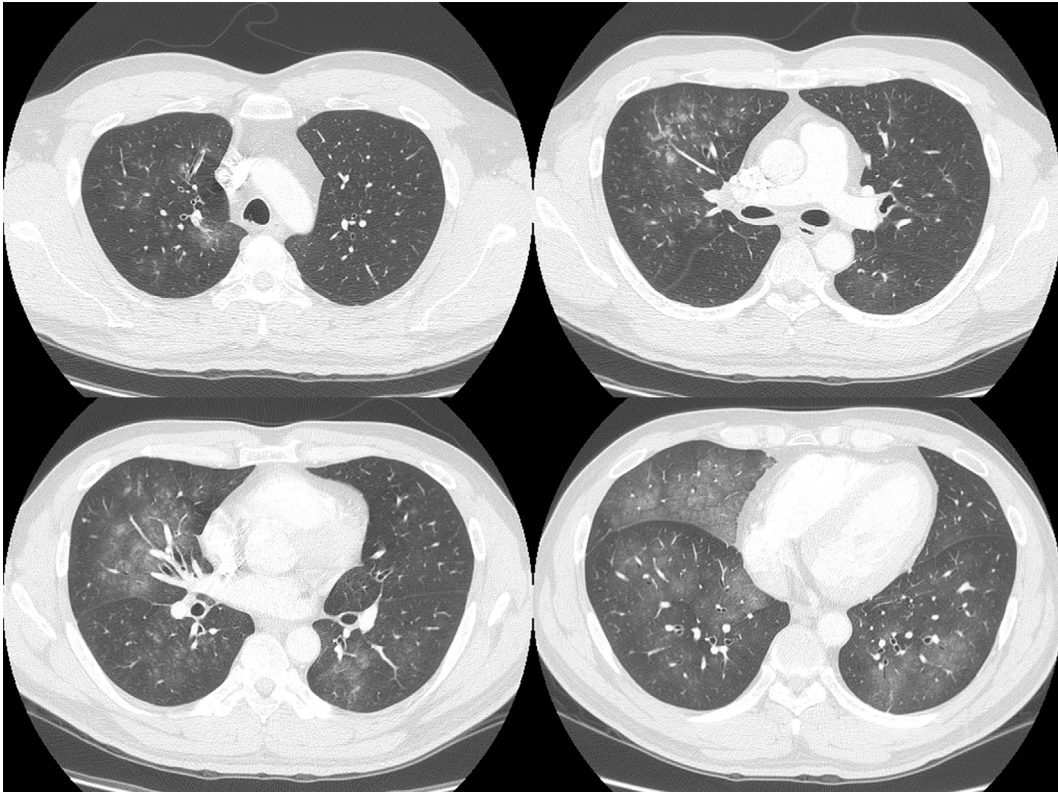


Figure 2. Chest computed tomography at the time of the first admission showed diffuse ground-glass opacity in the bilateral lung fields.

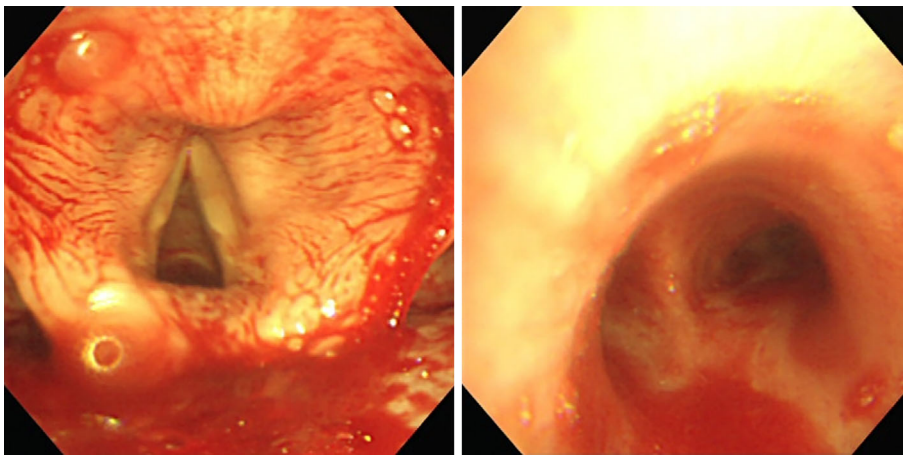


Figure 3. A bronchoscopic examination at the time of the first admission showed the accumulation of a large amount of blood in the trachea and bronchi.

continued to treat the patient with prednisolone alone after the second recurrence of DAH, because his hemoptysis had already disappeared in response to corticosteroid therapy at the time of the diagnosis of hemophilia and because the patient's diabetes mellitus and hypertension were controllable with the adjustment of oral hypoglycemic and antihypertensive medications. However, the patient's DAH recurred despite the provision of corticosteroid therapy, this treatment alone may not have been sufficient to achieve the long-term control of DAH. Thus, if it is not possible to control DAH or if other complications such as diabetes mellitus arise due to the corticosteroid therapy, as occurred in the present case,

coagulation factor IX replacement therapy is required.

In the present case, at the time of the first admission, the patient did not recognize that his bleeding episodes were hemorrhagic, and our questioning at the time did not reveal the blood transfusion episodes during his childhood or his brother's medical history. The presence of a mild extended APTT also left us unaware that the patient's condition was complicated with hemophilia. Furthermore, because he showed quite a good response to corticosteroids, we considered pulmonary capillaritis to have been the cause of DAH. Because further inquiries were not, even at the time of first recurrence of DAH, the diagnosis of hemophilia B was de-

Table. Laboratory Data on Admission.

Complete blood count			Blood chemistry			Immunology		
WBC	11,400	/μL	AST	30	U/L	CRP	1.3	mg/dL
Neutrophil	72.3	%	ALT	61	U/L	Rheumatoid factor	<5	units
Eosinophil	10.7	%	LDH	318	U/L	Anti-RNA antibody	negative	
Monocyte	5.2	%	ALP	196	U/L	Anti-SS-A/Ro antibody	negative	
Lymphocyte	11.6	%	γ-GTP	113	U/L	Anti-SS-B/Ro antibody	negative	
RBC	411×10 ⁴	/μL	TP	7	g/dL	Anti-centromere antibody	negative	
HGB	11.3	g/dL	ALB	4.3	g/dL	Anti-Jo1 antibody	negative	
HCT	34.5	%	UA	3.9	mg/dL	Anti-smith antibody	negative	
PLT	26.3×10 ⁴	/μL	UN	13	mg/dL	Anti-topoisomerase I antibody	negative	
Coagulation system			CRE	0.73	mg/dL	PR3-ANCA	<10	EU
			T-BIL	1.1	mg/dL	MPO-ANCA	<10	EU
APTT	53.5	sec	ID-BIL	0.1	mg/dL	Anti-GBM antibody	<10	EU
PT	11.4	sec	Na	139	mmol/L	Double standard DNA antibody	<10	IU/mL
PT activity	87	%	K	3.7	mmol/L	Cardiolipin antibody	< 8	U/mL
PT-INR	1.03		Cl	104	mmol/L	Urine test		
			Glucose	299	mg/dL	White blood cell count	<1	HPF
			HbA1c	8.2	%	Red blood cell count	<1	HPF
						Urinary sugar	4+(1,000)	

APTT: activated partial thromboplastin, PT: prothrombin time, PT-INR: PT international normalized ratio, PR3-ANCA: proteinase 3 antineutrophil cytoplasmic antibody, MPO-ANCA: myeloperoxidase-antineutrophil cytoplasmic antibody, GBM: glomerular basement membrane, HPF: high power field

laid. Matsumoto et al. reported the case of an 18-year-old patient with hemophilia B who had tuberculosis with non-cavitary lung disease. He had not been diagnosed in adolescence and presented with recurring hemoptysis (3). They further reported that hemophilia A often escapes detection, even in patients with factor VIII levels as high as 25%, until a heavy bleeding episode after major trauma or surgery (3). These results underscore the importance of performing a repeated, detailed inquiry regarding congenital bleeding diseases, even if DAH shows good response to corticosteroids.

We herein presented a case in which a patient was diagnosed with hemophilia B after repeated recurrences of DAH. There may be other cases of hemophilia that remain undiagnosed until adulthood. Attention should be paid to the possibility of hemophilia, even in adult patients with an unexplained recurrence of DAH.

Author's disclosure of potential Conflicts of Interest (COI).

Koichiro Tatsumi: Honoraria, GlaxoSmithKline and Pfizer.
Koichiro Tatsumi Research funding, The Respiratory Failure Research Group from the Ministry of Health, Labour and Welfare, Japan.

References

- Lara AR, Schwarz MI. Diffuse alveolar hemorrhage. *Chest* **137**: 1164-1171, 2010.
- Srivastava A, Brewer AK, Mauser-Bunschoten EP, et al. Guidelines for the management of hemophilia. *Haemophilia* **19**: e1-e47, 2013.
- Matsumoto H, Suzuki K, Watanabe I, et al. Recurrent hemoptysis in tuberculosis with non-cavitary lung disease as a symptom of mild hemophilia A in a young adult. *Intern Med* **39**: 63-65, 2000.
- Peyvandi F, Garagiola I, Young G. The past and future of haemophilia: diagnosis, treatments, and its complications. *Lancet* **388**: 187-197, 2016.
- Newsome BR, Morales JE. Diffuse alveolar hemorrhage. *South Med J* **104**: 269-274, 2011.
- Specks U. Diffuse alveolar hemorrhage syndromes. *Curr Opin Rheumatol* **13**: 12-17, 2001.
- Suzuki T, Yamamoto Y, Otaki M, et al. Acute alveolar haemorrhage in a patient with haemophilia B. *Haemophilia* **18**: e29-e31, 2012.
- Girolami A, Vettore S, Scandellari R, Allemand E, Girolami B. About the rarity of haemoptysis in congenital bleeding disorders. A report of five cases. *Haemophilia* **15**: 825-827, 2009.
- Connolly JP. Hemoptysis as a presentation of mild hemophilia A in an adult. *Chest* **103**: 1281-1282, 1993.
- Takeda R, Mabuchi H. A massive pulmonary hemorrhage resulting in cavitation occurring in a case of hemophilia A associated with diabetes mellitus. *South Med J* **67**: 869-873, 1974.
- O'Dwyer ME, DeLoughery TG. Pulmonary hemorrhage in a hemophiliac simulating a lung neoplasm. *Am J Hematol* **64**: 299-302, 2000.
- Chandrakala S, Jijina F, Ghosh K. Diffuse alveolar haemorrhage with severe haemophilia. *Haemophilia* **16**: 962-964, 2010.
- White GC 2nd, Rosendaal F, Aledort LM, et al. Definitions in hemophilia. Recommendation of the scientific subcommittee on factor VIII and factor IX of the scientific and standardization committee of the International Society on Thrombosis and Haemostasis. *Thromb Haemost* **85**: 560, 2001.

The Internal Medicine is an Open Access article distributed under the Creative Commons Attribution-NonCommercial-NoDerivatives 4.0 International License. To view the details of this license, please visit (<https://creativecommons.org/licenses/by-nc-nd/4.0/>).