

A case of deep vein thrombosis associated with methicillin sensitive *Staphylococcus aureus* genu septic arthritis

Lyndia Effendy, Metta Octora,
Deby Kusumaningrum

Department of Clinical Microbiology,
Faculty of Medicine Universitas
Airlangga, Dr. Soetomo Hospital
Surabaya, Indonesia

Abstract

Septic arthritis caused by bacteria Gram positive *Staphylococcus aureus* (*S. aureus*) infection has been widely reported from Europe and the United States. This case presentation reported the first *Staphylococcal* septic arthritis, preceded by systemic erythroderma skin lesions from aregional hospital in Surabaya, Indonesia. Radiology imaging was used for confirming the defect. Joint fluid aspirate from the affected knee joint lesion was sent for joint fluid analysis and microbiology culture. The analysis showed infiltration of neutrophil inflammatory cells. *S. aureus* was isolated on culture and demonstrated catalase positive and coagulase positive reactions. Antimicrobial susceptibility testing was performed to determine the appropriate selection of antibiotics. Clindamycin was used for treatment and the complicated occurrence of deep vein thrombosis was treated with anticoagulant. Awareness of this disease and its progression to its complication deep vein thrombosis is required to understand the burden of this disease.

Introduction

Staphylococcus aureus (*S. aureus*) infection is one of the cause of an acute and destructive septic arthritis in adults. The frequency of septic arthritis is four to ten cases per 100,000 patients years. Our case reported a 50 years old man with deep vein thrombosis of left femoral vein who presented initially with *Staphylococcal* septic arthritis of left knee and erythroderma. He underwent prolonged hospital admission and was managed with synovial fluid aspiration, antibiotics and anticoagulant. This report aims to describe increased risk of deep vein thrombosis in Methicillin Sensitive *Staphylococcal* genu septic arthritis

Case Report

A 50-year-old man with hypertension was referred to the emergency department of Dr. Soetomo hospital with four days history of fluctuating fever and severe progressive pain in the left knee that had begun after three years of recurring history of desquamated itchy redness of the entire body skin. He had been consuming herbal medication for this disease and he recently underwent 12 days hospitalization in other nearby regional hospital, where he received ceftriaxone injection, but no improvement was seen.

The patient was not able to stand up at that moment of admission. BMI was 23kg/m², blood pressure 170/100mmHg, pulse 105 beats per minute and body temperature 37,5°C. The day before it was 38,2°C. The left knee showed signs inflammation and desquamation. There was no history of trauma, no allergy, no diabetes, no elevated in uric acid level, no high cholesterol levels. Blood examination showed hemoglobin 8.3g/dL, leucocytes of 8680/μL and platelet 610000/μL, albumin 2.7mg/dL, LED 50 mm, CRP 8.7mg/dL, uric acid 2.5mg/dL. X-ray studies of the left knee revealed osteoarthritis with narrowing of femuropatellar left knee joint with osteophytes in posterior margin.

Joint fluid obtained during arthroscopy on the day of admission showed a yellowish and clear aspirate, no crystal were visible, WBC 6167/μL, neutrophil 81.3%. The aspirate was also sent to the microbiology laboratory for direct Gram staining and culture. It showed Gram positive cocci, catalase positive, coagulase positive. The culture from Phoenix was identified as *S. aureus* with antimicrobial susceptibility test still susceptible to oxacillin, cefoxitin, amoxiclav, ciprofloxacin, clindamycin, gentamicin, mupirocine high level, quinupristin-dalfopristin, teicoplanin, cotrimoxazole, and fosfomycin. Based form this AST then treatment with clindamycin was started. However, because of inadequate response, further investigation of the arthritis knee were performed and found partial thrombus of vena saphena magna femoralis to distal sinistra. After the patient received anticoagulant agent and a good clinical outcome was obtained.

Discussion

Septic arthritis is a severe type of arthritis that occurs when bacteria, viruses, fungi or protozoa invade joints resulting in severe inflammation and joint damage.^{1,2} Septic

Correspondence: Lyndia Effendy, Department of Clinical Microbiology, Faculty of Medicine University of Airlangga, Dr. Soetomo Hospital Surabaya, Indonesia, Mayjen; Prof.Dr. Moestopo 6-8, Surabaya, East Java, Indonesia,
Tel.: 08123019152
E-mail: lyndiaeffendy@gmail.com

Key words: methicillin sensitive *Staphylococcus aureus*, genu septic arthritis, deep vein thrombosis.

Contributions: All the authors contributed equally.

Conflict of interest: The authors declare no potential conflict of interest.

Funding: None.

Acknowledgements: The authors would like to thank various people for their contribution to this report, all technicians in microbiology laboratory in Dr Soetomo's hospital, for their valuable technical support on this project. Special thanks should be given to Prof. Dr. dr. Eddy Bagus Wasito, MS, SpMK (K), my research project supervisor for their professional guidance and valuable support and to dr Lindawati Alimsardjono, MKes, SpMK (K) for her useful and constructive recommendations on this project.

Conference presentation: Poster Presentation on the International conference INSBIO MM 27-28 August, 2019.

Received for publication: 17 February 2020.
Accepted for publication: 1 July 2020.

This work is licensed under a Creative Commons Attribution-NonCommercial 4.0 International License (CC BY-NC 4.0).

©Copyright: the Author(s), 2020

Licensee PAGEPress, Italy
Infectious Disease Reports 2020; 12(s1):8725
doi:10.4081/idr.2020.8725

arthritis is estimated to be 4 to 10 cases per 100,000 people in industrialized countries, and can affect people at any age,³⁻⁶ even though males are slightly more susceptible than females.^{2,3} Persisting joint damage occurs in more than 30% of the patients^{3,4}. A study for incidence and prevalence of septic arthritis in Indonesia has not yet been recorded. From the previous studies, the presence of skin fragility, prior arthritis, diabetes, and poor immune function may increase the risk of septic arthritis occurrence.⁵⁻⁷

The clinical manifestation of our patient was four days history of fluctuating fever

and severe progressive pain of the left knee that had begun after three years recurring history of desquamated itchy redness of the entire body skin. The three years clinical history of erythroderma, presented a non intact skin, as a site of entry for skin normal flora into the underlying soft tissue. The invasion of microorganism, including normal flora such as *S. aureus* into the synovial space, may occur either through hematogenous spread (most common) or by direct invasion. The synovium is extremely vascularized and contains no limiting basement membrane, facilitating the access to the synovial space. Thus, bacteria may spread directly from a local skin and soft tissue infection and could reach the joint through non intact skin.

However, there was a delay in diagnosing and treatment of septic arthritis in this patient because at first he had been self medicating by consuming herbal medication for three years. When the skin condition got worse and the patient had difficulties in standing on his leg, he was admitted to one of the regional hospital and then received ceftriaxone injection with 12 days hospitalization, but no improvement was seen.

This report showed a case of unresolved arthritis, thus referred to Dr Soetomo hospital for further investigation. From the microbiology examination, the causative agent responsible for this was Gram positive, coagulase positive *S. aureus*. This causative agent is well known as the most prevalent microorganisms causing septic arthritis.^{1,4} *S. aureus* is a stable colonizers of the nares and the skin of the human population.⁸ *S. aureus* is also an invasive pathogen and frequent cause of skin and soft tissue as well as bloodstream infections.⁸ Once these microorganisms have gained entry into the joint, the low fluid conditions in the joint space allow adherence and infection.⁹ The attachment of *S. aureus* to the joint extracellular matrix is mediated by microbial surface component recognizing adhesive matrix molecules (MSCRAMMs). After colonizing the joint, the bacteria can rapidly proliferate and trigger an acute inflammatory response. The synovium responds with a proliferating lining-cell hyperplasia and there is an influx of inflammatory cells.⁹ Phagocytes, including neutrophils and macrophages, chemotactically migrate to the infected joint, directed by gradients of bacterial products displaying chemotactic activity and mediators of the immune response.¹⁰ Neutrophils play a major role in the first-line defense against invading pathogens, including bacteria, and these leucocytes are the first to migrate to the site of infection. Activated macrophages are

recruited to the joint slightly later and they are followed by T lymphocytes.⁸⁻¹⁰

The infectious capacity of *S. aureus* in different tissues is provided by the presence of several virulence factors.⁸⁻¹⁰ *S. aureus* produces staphyloxanthin, a membrane-bound carotenoid, which is responsible for the yellow pigmentation of colonies. This pigment scavenges reactive oxygen species and protects *S. aureus* from phagocytic killing. A hallmark of *S. aureus* is mediated by two secreted products, coagulase (Coa) and von Willebrand factor-binding protein (vWbp), which contribute to the ability to clot human blood or plasma.⁹⁻¹⁰ *S. aureus* has a capsule composed of polysaccharides, which acts as a physical barrier that protects the bacteria from phagocytosis by immune cells that infiltrate into the synovial fluid during the inflammation phase. Peptidoglycan (PGN) is the major component of the cell wall of Gram positive bacteria.¹¹ *S. aureus* is a bone pathogen because it possesses several cell-surface adhesion molecules that facilitate its binding to the bone matrix.¹²⁻¹⁴ Binding involves a family of adhesins that interact with extracellular matrix components and these adhesins have been termed MSCRAMMs.^{14,15} Specific

MSCRAMMs are needed for the colonization of specific tissues. Particular MSCRAMMs include fibronectin-binding proteins, fibrinogen-binding proteins, elastin-binding and collagen-binding adhesion molecules. Once the bacteria adhere to and colonize bone matrix, they elaborate several virulence factors such as proteases,




Figure 3. No growth in Mac Conkey agar plate.

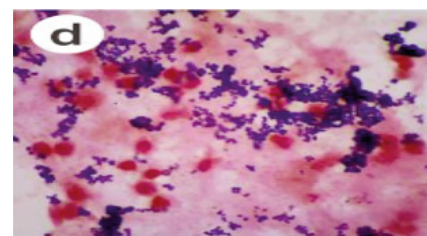


Figure 4. Gram stain showed Gram positive coccus.

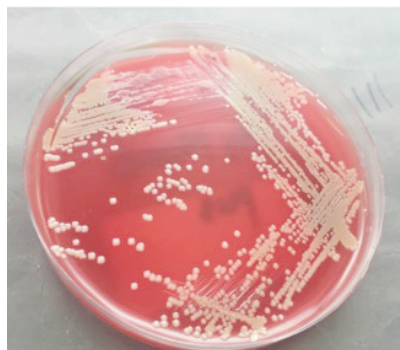


Figure 1. Golden Yellow colonies of *Staphylococcus aureus* in blood agar plate.

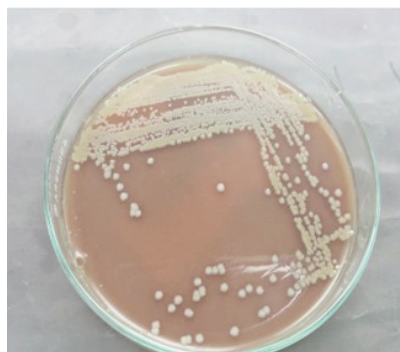

Figure 2. Golden yellow colonies of *Staphylococcus aureus* in chocolate agar plate.



Figure 5. Catalase positive.



Figure 6. Coagulase positive.

which can break down matrix components.^{14,15} Further experimental studies demonstrated that collagen adhesion is an important virulence determinant in *S. aureus*-induced arthritis.¹⁵

S. aureus secretes a large number of enzymes and toxins, many of which have been implicated as potential virulence factors. Alpha and gamma toxins are lytic to red blood cells and various leukocytes, but not to neutrophils.¹⁶ The combination of these two toxins has been experimentally demonstrated to be important for the development of septic arthritis.¹⁶ Another toxin is Pantone-Valentine leucocidin (PVL, consisting of the LukS and LukF proteins) that can lyse leukocytes, especially human neutrophils, and is related to fulminant cases of septic arthritis.¹⁶ Enterotoxins, such as the superantigen toxic shock syndrome toxin-1 (TSST-1) can cause shock by stimulating the release of interleukin IL-1, IL-2, TNF and other cytokines.¹⁶ Experimentally, the presence of TSST-1 favors the development of septic arthritis.¹⁶ Another important virulence factor is bacterial deoxyribonucleic acid (DNA) with non-methylated CpG motifs, which is considerably less frequent in vertebrate DNA.¹⁷ The CpG DNA can bind to Toll-like receptor 9 (TLR9) in immune cells, leading to the production of cytokines such as IL-1 β , TNF, IL-6 and IL-12.¹⁷ Those various factors may predispose to the development of Deep Vein Thrombosis (DVT) caused by *S. aureus*-induced septic arthritis.

Usually in the management of joint infections, an initial short course of intravenous treatment is given to reduce the bacterial burden and thereby minimize the risk of emergence of resistance to oral agents. Intravenous therapy is administered for the first 2-4 weeks, followed by long term oral therapy to complete the treatment.¹⁸ The appropriate choice of antibiotic for treatment of septic arthritis is based on the likelihood of the organism involved, modified by the result of Gram staining and microbiology culture. Suggested empirical antibiotic treatment of septic arthritis with no risk factors for atypical organism is second or third generation cephalosporin (if the patient presents penicillin allergy), or clindamycin oral or flucloxacillin intravena or gentamicin intravena.¹⁹ When selecting oral antibiotics to treat septic arthritis must consider several factors such as the type and causative agent of infection, the extent of debridement when applicable, the antibiotic susceptibility of the pathogen, antibiotic penetration into the bone and joint tissue, oral bioavailability and cost. The drug selected must have activity against the isolated organism and have a low risk for the

development of adverse reactions and drug-drug interactions. Clindamycin is a lincosamide antibiotic, a synthetic compound of natural occurring lincomycin. Like cloxacillin and the cephalosporin, clindamycin possesses activity against *Staphylococcus aureus* infection of bone and soft tissue. Clindamycin acts by inhibiting bacterial protein synthesis at the level of the 50s ribosome. It may decrease toxin production and increase microbial opsonization and phagocytosis even at subinhibitory concentrations. Clindamycin is well absorbed (90%) from the gastrointestinal tract, and high concentrations are achieved in most tissues including neutrophils, bone (60%) and joints (85%) but not in the central nervous system. The drug is metabolized and excreted by the liver, and dose modifications are recommended for hepatic failure or concomitant renal and hepatic dysfunction.¹⁹

Similar studies showed that DVT occurred after *S. aureus* septic arthritis. DVT was usually diagnosed after 4 to 6 days after diagnosis of septic arthritis and subsequent immobilization.^{2,20}

Anticoagulant therapy remains a major factor of initial treatment for DVT because the bacteria can hide inside the thrombus and lead to a persistent inflammatory response, thus requiring a more prolonged course of antibiotic therapy with its various side effects.²⁰ Presence of DVT in *Staphylococcus aureus* septic arthritis patient is associated with higher rate of disseminated infection which may occur in up to one third of patients and associated with high mortality rate.²⁰

Conclusions

This case report showed a patient with *Staphylococcal genu* septic arthritis had a severe complication of Deep Vein Thrombosis. This is due to *Staphylococcal* inflammation and their intensification of a hypercoagulability state, progressive joint tissue damage and persistent edema, along with immobilization, known as Virchow's triad. A moderately elevated C reactive protein and several other inflammatory markers are indicating this ongoing process. Microbiology culture and sensitivity, obtained from the synovial fluid aspirate, is important in confirming the causative agent for this case of septic arthritis. Clinicians should also be aware of the elevated risk of DVT in patient with *Staphylococcal genu* septic arthritis. Hence, initiating appropriate investigation and timely management can be conducted to reduce morbidity in this case.

References

1. Boff,D, Crijns, H, Teixeira,MM. etal. Neutrophils: Beneficial and Harmful Cells in Septic Arthritis. Int J Mol Sci 2018; 19:468.
2. Gupta MN, Sturrock,RD, Field,M. A Prospective 2 year study of 75 patients with adult onset septic arthritis. Rheumatology. 2001; 40:24-30.
3. Geirsson AK, Statkevicius S, Vikingson A. Septic Arthritis in Iceland 1990-2002: Increasing incidence due to iatrogenic infections. Ann Rheum Dis 2007;67:638-43.
4. Kennedy N, Chambers ST, Nolan I, et al. Native joint septic arthritis: Epidemiology, clinical features and microbiological causes in a New Zealand population. J Rheumatol 2015;42:2392-7.
5. Khan FY, Abu-Khattab M, Baagar K, et al. Characteristics of patients with definite septic arthritis at Hamad General Hospital Qatar: A hospital-based study from 2006 to 2011. Clin Rheumatol 2013; 32:969-73.
6. Okubo Y, Nochioka K, Marcia T Nationwide survey of pediatric septic arthritis in the United states. J Orthop 2017;14:342-6.
7. Lieber SB, Fowler ML, Zhu C, et al. Clinical characteristics and outcomes in polyarticular septic arthritis. Joint Bone Spine 2018;85:469-73.
8. Thomer L, Schneewind O, Missiakas D. Pathogenesis of *Staphylococcus aureus* Bloodstream Infections. Ann Rev Pathol: 2017.
9. Tarkowski A, Bokarewa M, Collins LV, et al. Current status of pathogenetic mechanisms in staphylococcal arthritis FEMS Microbiol Lett 2002;217:125-32.
10. Verdrengh,M, Tarkowski,A. Role of neutrophils in experimental septicemia and septic arthritis induced by *Staphylococcus aureus*. Infect Immun 1997;65:2517-21.
11. O'Riordan K, Lee,JC. *Staphylococcus aureus* Capsular Polysaccharides. Clin Microbiol Rev 2004;17:218-34.
12. Hudson MC, Ramp WK, Frankenburg KP. *Staphylococcus aureus* adhesions to bone matrix and bone-associated biomaterials. FEMS Microbiol Lett 1999;173:279-84.
13. Wright JA., Nair SP. Interaction of staphylococci with bone. Int J Med Microbiol 2010;300:193-204.
14. Foster TJ, Hook M. Surface protein adhesins of *Staphylococcus aureus*. Trends Microbiol 1998;6:484-488.
15. Patti JM, Bremell T, Krajewska-

- Pietrasik D, et al. The Staphylococcus aureus collagen adhesion is a virulence determinant in experimental septic arthritis. *Infect Immun* 1994;62:152-61.
16. Loffler B, Hussain M, Grundmeier M, et al. Staphylococcus aureus panton-valentine leucocidin is a very potent cytotoxic factor for human neutrophils. *PLoS Pathog* 2010;6:e1000715
 17. Singer M, De Waaij DJ, Morre SA, Ouburg S. CpG DNA analysis of bacterial STDs. *BMC Infect.Dis.*2015; 15,273.
 18. Matthews CJ, Kingsley G, Coakley G, et al. Management of septic arthritis: a systematic review. *Ann Rheum Dis* 2007; 66: 440-445.
 19. Kim BN, Kim ES, Oh MD. Oral antibiotic treatment of staphylococcal bone and joint infections in adults. *J Antimicrob Chemother* 2014; 69:309-22.
 20. Shrestha D, Limbu H, Thapa NB, Dhakal AK. Deep vein thrombosis in a child with osteoarticular infection: A case report. *JCMS-Nepal*: 2013; 9:52-5.