



# Concealed index for concealed penis in prepubertal children

Kobiljon Ergashev<sup>1</sup> , Jae Min Chung<sup>1,2,3</sup> , Sang Don Lee<sup>1,2,3</sup>

<sup>1</sup>Department of Urology, Pusan National University Yangsan Hospital, Yangsan, <sup>2</sup>Department of Urology, Pusan National University School of Medicine, Yangsan, <sup>3</sup>Research Institute for Convergence of Biomedical Science and Technology, Pusan National University Yangsan Hospital, Yangsan, Korea

**Purpose:** The concealed penis (CP) is a congenital or acquired genital anomaly that requires surgical correction. To construct an objective CP severity index, we compared the penile parameters of a CP with a normal penis (NP) and postoperative outcomes of CP patients.

**Materials and Methods:** In this retrospective study, 391 boys under 14 years who visited our hospital between September 2017 and February 2020 were included. Among these boys, 105 patients had a CP and 286 boys had a NP without CP. The stretched penile length (SPL), penile circumference (PC), and penile length above baseline skin level (BPL) were measured using a ruler (cm), and the testicular volume was measured using an orchidometer (mL). We defined the concealed index according to SPL (CIs) as BPL/SPL and the concealed index according to circumference (CIC) as BPL/PC. A repair of the CP was performed in the CP patients. All parameters were measured before surgery and after three months.

**Results:** The CP had significantly shorter SPL and BPL, and smaller CIs and CIC than the NP. The cutoff values for the CIs and CIC were 0.68 and 0.58, respectively (sensitivity 86.7% and 86.7%; specificity 65.0% and 88.5%, respectively). After repair of the CP, all penile parameters were significantly improved.

**Conclusions:** The CIs and CIC are useful and objective parameters for checking the severity of CP, and evaluating the postoperative outcome of CP repair. We newly introduced cutoff values for the CIs (0.68) and CIC (0.58) for diagnosing and evaluating CP repair.

**Keywords:** Child; Penile diseases; Penis; Reconstructive surgical procedures; Severity of illness index

This is an Open Access article distributed under the terms of the Creative Commons Attribution Non-Commercial License (<http://creativecommons.org/licenses/by-nc/4.0>) which permits unrestricted non-commercial use, distribution, and reproduction in any medium, provided the original work is properly cited.

## INTRODUCTION

The concealed penis (CP) has a broad definition. Considerable research has been conducted on this topic regarding its classification, treatment options, and especially, surgical techniques [1-3]. The CP is one that appears to be small but has a normal stretched penile length (SPL) when measured from the pubic symphysis to the tip of the glans and a nor-

mal diameter of the penile shaft [4]. In this regard, this entity must be distinguished from a micropenis, in which the penile length is shorter than the normal length.

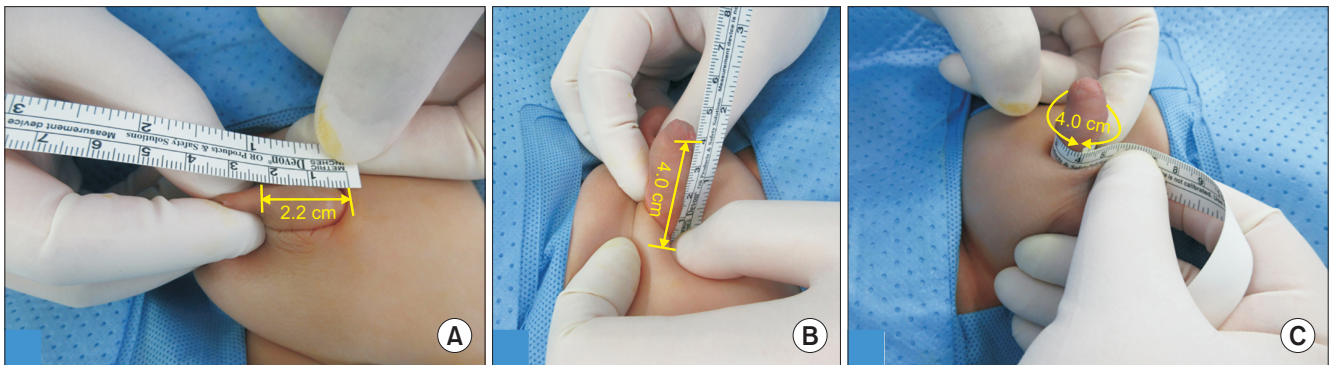
Presently, many confusing terms regarding the concealment condition of the penis, such as buried, trapped, webbed, hidden, inconspicuous, and concealed, are used. A buried penis occurs when the fundiform ligament of the penis saddles abnormally on the dorsal shaft. This anomaly is frequently

**Received:** 7 September, 2020 • **Revised:** 13 October, 2020 • **Accepted:** 8 November, 2020 • **Published online:** 25 February, 2021

**Corresponding Author:** Jae Min Chung <https://orcid.org/0000-0002-7467-5954>

Department of Urology, Pusan National University Yangsan Hospital, Pusan National University School of Medicine, 20 Geumo-ro, Mulgeum-eup, Yangsan 50612, Korea

TEL: +82-55-360-2678, FAX: +82-55-360-2164, E-mail: busanuro@hanmail.net



**Fig. 1.** Measuring techniques of the penile parameters. (A) Penile length above baseline skin level (BPL)=2.2 cm. (B) Stretched penile length (SPL)=4.0 cm. (C) Penile circumference (PC)=4.0 cm. Concealed index according to SPL (CIs)=concealed index according to circumference (Cic)=0.55.

associated with insufficient penile skin, inadequate subcutaneous attachment to Buck's fascia, and usually, a narrow opening of the prepuce [2]. Another form, the trapped penis, is related to cicatrix formation after circumcision. Last, in a webbed penis, the CP has scrotal skin continuing up to the penile ventral shaft. Obesity or excessive suprapubic fat tissue may influence the appearance of a hidden penis. In this paper, we describe CP terminology to prevent any further confusion. The concealment condition of the penis is represented by "CP", instead of buried, hidden, or inconspicuous penis.

The severity of a CP varies widely. However, there are no objective methods to accurately determine the severity of the CP. Moreover, there is also no precise, objective way to distinguish the CP from the normal penis (NP). The traditional method of diagnosing a CP is by physical examination (visual inspection), which is very subjective. The diagnosis can vary from center to center and among physicians. Therefore, it would be useful to have an objective tool to distinguish a CP from a micropenis, the severity of the CP, and evaluate outcomes after surgery. This retrospective study aimed to introduce a new diagnostic tool that is useful for differentiating the severity of a CP and the condition of the penis.

## MATERIALS AND METHODS

This study was approved by the Institutional Review Board of the Pusan National University Yangsan Hospital (approval number: 05-2020-156). The clinical information of the patients was collected by reviewing the medical records retrospectively.

### 1. Data collection

Data were collected from patients under 14 years old

between September 2017 and February 2020 who visited our clinic for pediatric urological and genital problems such as CP, retractile testis, hydrocele, enuresis, and overactive bladder. We excluded patients with a micropenis, trapped penis, webbed penis, and bilateral undescended testes from this study.

### 2. Measurement of penile and testicular parameters

The SPL, penile circumference (PC), and penile length above the baseline skin level (BPL) were measured using a ruler (cm) (Fig. 1). The SPL was the stretched distance from the base of the penis under the pubic symphysis to the tip of the glans. The BPL was the distance from the baseline penile skin level to the tip of the glans. Care must be taken not to include the prepuce length in the SPL and BPL measurements. The PC was identified as the length of the penile base girth. The concealed index was calculated using the BPL and the SPL or the BPL and the PC. The concealed index according to the SPL (CIs) was calculated by the BPL/SPL ratio. The concealed index according to circumference (Cic) was calculated by the BPL/PC ratio. The testicular volumes were measured on each side with a Prader orchidometer.

### 3. Analysis groups

Patients with normal penile parameters were classified into the NP group. Patients with a CP were classified into the CP group. To properly compare the two groups, the patient numbers in each group were enrolled in an age-matched manner (NP:CP=2:1). Finally, we enrolled 105 children with a CP and 286 children with a NP. Repair of the CP was performed in the CP group by a single pediatric urologist between September 2017 and February 2020.

**4. Operation method**

The operation started with the patient in the supine position on the table and under general anesthesia. A median longitudinal incision was made on the ventral penile skin from the phimotic ring to the penoscrotal junction. A stay suture was put on the glans for traction with Prolene 5.0 (Ethicon, Somerville, NJ, USA) and remained until the end of the operation. A circumferential incision was made according to the initial preputial opening.

Degloving was performed with dissecting all Dartos fascia of the penis and fibrous tissues from Buck’s fascia. The subcutaneous tissue of the penoscrotal junction was dissected ventrally at the 6 o’clock position. This simplified the penopubic area fat tissue dissection dorsally until the pubic ligaments were reached at 12 o’clock. Two-point fixation sutures at the dorsal and ventral base of the penis were made with Prolene 4.0 (Ethicon).

Skin coverage was conducted with an approximation of the dissected Dartos fascia to Buck’s fascia. Byar’s flap embraced the ventral surface of the penis and the shaft skin was recreated by transposing the skin medially into the midline.

All the remaining penile skin was designed for approximation with Monocryl 6.0 (Ethicon) and the remnant skin was removed. The operation was finished by inserting a Foley catheter and applying an appropriate compression dressing. The patient was usually discharged the day after surgery.

**5. Improvement evaluation**

Improvement was calculated as the ratio of the differ-

ence between the postoperative and preoperative concealed indexes to the postoperative concealed index and expressed as a percentage. Based on these findings, the patients were divided into two groups: patients whose concealed index improved by more than 25% (group A) and those with less than 25% improvement (group B).

**6. Statistical analysis**

SPSS for Windows 26.0 software (IBM Corp., Armonk, NY, USA) was employed for all statistical analyses. We compared the two groups by the Mann–Whitney test. A p-value of <0.05 was considered statistically significant.

**Results**

The average age of the patients was 70.96±49.25 months. The average SPL, PC, and BPL were 4.40±1.39 cm, 4.51±1.09 cm, and 3.01±1.44 cm, respectively. The SPL/PC ratio was 0.98±0.17, which was very close to 1, indicating that the SPL was similar to the PC. The CIs (BPL/SPL) and C<sub>ic</sub> (BPL/PC) ratios were 0.67±0.14 and 0.66±0.20, respectively. The average volume of the right testis was 3.07±3.01 mL and the left was 3.00±2.57 mL.

**1. Normal penis vs. concealed penis**

The age, height, weight, PC, and volume of the testis in the patients in the NP group and those in the CP group were not statistically different. The BMI, SPL, SPL/PC, BPL, CIs, and C<sub>ic</sub> showed statistical differences between the two groups (Table 1).

An receiver operating characteristic (ROC) analysis was

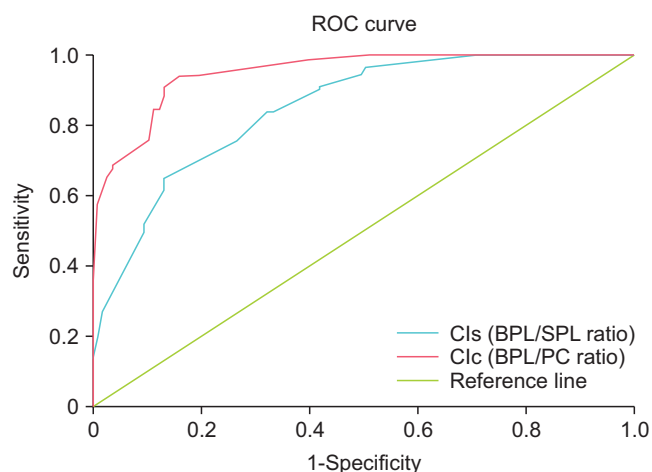
**Table 1.** Characteristics of the patients with NP, CP, and total patients

Parameter	NP group (n=286)	CP group (n=105)	Total patients (n=391)	p-value <sup>a</sup>
Age (mo)	71.09±46.33	70.63±56.69	70.96±49.25	0.412
Height (cm)	113.22±27.59	113.19±32.35	113.21±29.02	0.76
Weight (kg)	24.97±15.61	30.14±21.75	26.41±17.66	0.751
BMI (kg/m <sup>2</sup> )	18.17±4.07	20.02±4.15	18.71±4.18	<0.001
SPL (cm)	4.67±1.39	3.67±1.09	4.40±1.39	<0.001
PC (cm)	4.51±1.17	4.51±0.85	4.51±1.09	0.062
SPL/PC	1.04±0.12	0.82±0.18	0.98±0.17	<0.001
BPL (cm)	3.40±1.43	1.94±0.79	3.01±1.44	<0.001
CIs (BPL/SPL ratio)	0.72±0.10	0.53±0.16	0.67±0.14	<0.001
C <sub>ic</sub> (BPL/PC ratio)	0.74±0.14	0.43±0.14	0.66±0.20	<0.001
Right testis volume (mL)	3.14±3.32	2.89±2.05	3.07±3.01	0.554
Left testis volume (mL)	3.03±2.72	2.91±2.11	3.00±2.57	0.568

Values are presented as mean±standard deviation.

NP, normal penis; CP, concealed penis; BMI, body mass index; SPL, stretched penile length; PC, penile circumference; BPL, baseline penile length; CIs, concealed index according to SPL; C<sub>ic</sub>, concealed index according to circumference.

<sup>a</sup>:Mann–Whitney test.



**Fig. 2.** Receiver operating characteristic (ROC) curve for the concealed index values to discriminate normal penis from concealed penis patients. Cls, concealed index according to SPL; BPL, baseline penile length; SPL, stretched penile length; Clc, concealed index according to circumference; PC, penile circumference.

**Table 2.** Comparison of the preoperative and postoperative penile parameters of the patients with concealed penis

Parameter	Preoperative	Postoperative	p-value <sup>a</sup>
SPL (cm)	3.67±1.09	4.36±1.32	<0.001
PC (cm)	4.51±0.85	5.07±1.45	<0.001
SPL/PC	0.82±0.18	0.87±0.13	0.01
BPL (cm)	1.94±0.79	3.30±1.08	<0.001
Cl <sub>s</sub> (BPL/SPL ratio)	0.53±0.16	0.75±0.08	<0.001
Cl <sub>c</sub> (BPL/PC ratio)	0.43±0.14	0.65±0.13	<0.001

Values are presented as mean±standard deviation.

SPL, stretched penile length; PC, penile circumference; BPL, baseline penile length; Cl<sub>s</sub>, concealed index according to SPL; Cl<sub>c</sub>, concealed index according to circumference.

<sup>a</sup>:Mann-Whitney test.

conducted to find the cutoff value of the concealed index to distinguish an NP from a CP. The Cl<sub>s</sub> cutoff value was 0.68, with a sensitivity of 86.7% and a specificity of 65.0%. The Cl<sub>c</sub> cutoff value was 0.58, with a sensitivity of 86.7% and a specificity of 88.5% (Fig. 2).

## 2. Postoperative outcomes

All penile parameters showed significant improvement postoperatively excepted SPL/PC ( $p<0.005$ ; Table 2). Moreover, all postoperative penile parameters were significantly different between the NP and CP patients except the BPL (3.40±1.43 cm and 3.30±1.08 cm,  $p=0.813$ ; Table 3, Fig. 3A).

## 3. Improvement evaluation

The patients in group A were older than those in group B (87.96±56.22 months and 50.04±50.48 months, respectively).

**Table 3.** Comparison of the penile parameters of the patients with NP and postoperative concealed penis at 3 months

Parameter	NP group (n=286)	Postoperative at 3 months (n=105)	p-value <sup>a</sup>
SPL (cm)	4.67±1.39	4.36±1.32	0.001
PC (cm)	4.51±1.17	5.07±1.45	<0.001
SPL/PC	1.04±0.12	0.87±0.13	<0.001
BPL (cm)	3.40±1.43	3.30±1.08	0.813
Cl <sub>s</sub> (BPL/SPL ratio)	0.72±0.10	0.75±0.08	0.001
Cl <sub>c</sub> (BPL/PC ratio)	0.74±0.14	0.65±0.13	<0.001

Values are presented as mean±standard deviation.

NP, normal penis; SPL, stretched penile length; PC, penile circumference; BPL, baseline penile length; Cl<sub>s</sub>, concealed index according to SPL; Cl<sub>c</sub>, concealed index according to circumference.

<sup>a</sup>:Mann-Whitney test.

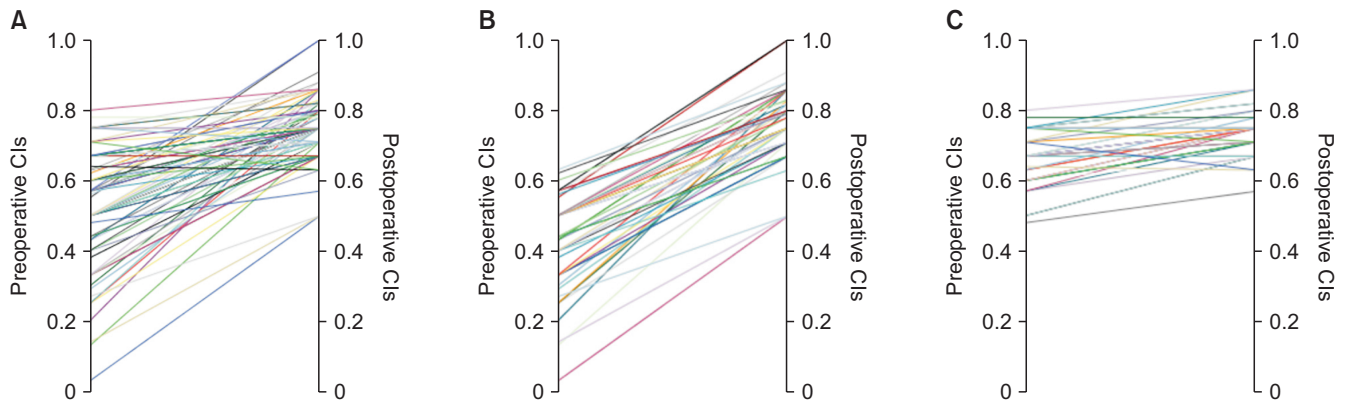
The preoperative SPL/PC ratio was higher in group A than in group B. Preoperatively, the Cl<sub>s</sub> and Cl<sub>c</sub> in group A (0.43±0.13 and 0.36±0.13, respectively) were lower than in group B (0.65±0.08 and 0.50±0.12, respectively). The PC and the Cl<sub>s</sub> were significantly different postoperatively between the two groups ( $p=0.026$  and  $p=0.016$ , respectively; Table 4, Fig. 3B, C).

## DISCUSSION

There conducted many articles that described CP definition, its classification, and surgical treatment [5-7]. Recently, there was a research about penile index in CP [8]. However, their research includes only CP patients. Our study is the first article that reports the comparison between the CP and the NP. Moreover, a concealed index can serve as a useful tool to differentiate a CP from a NP, to obtain the severity of the CP, and to assess the postoperative improvement.

Many different classifications for penile concealment have been developed [9-12]. Crawford [10] reported that a CP was a relatively common condition in infancy, where the penis is concealed behind a protuberant fold of suprapubic fat. A micropenis is described as an endocrine-related disorder and an organ that is smaller than normal for the size and age of the individual. A buried penis is defined as a condition in which the penile shaft is partially or completely buried in subcutaneous fat. A webbed penis is a relatively common abnormal skin covering in which there is a partial or complete penoscrotal web.

Hinman [11] suggested distinguishing two types of micropallus, the anomalous and the endocrine types. The former type is a disorder that arises from antenatal factors occurring during the first trimester of pregnancy. The endocrine type is a micropallus that arises from defects in endocrine



**Fig. 3.** Comparison of preoperative vs. postoperative concealed index according to SPL (CIs). (A) Total patients. (B) Group A: more than 25% improvement. (C) Group B: less than 25% improvement.

**Table 4.** Comparative data of the improvement in the postoperative concealed penis patients

Parameter	Group A	Group B	p-value <sup>a</sup>
Age (mo)	87.96±56.22	50.04±50.48	0.002
Height (cm)	123.54±32.53	100.89±27.76	0.001
Weight (kg)	37.69±22.70	21.17±16.78	<0.001
BMI (kg/m <sup>2</sup> )	21.56±4.23	18.18±3.24	<0.001
Preoperative			
SPL (cm)	3.86±1.16	3.45±0.95	0.058
PC (cm)	4.51±0.86	4.52±0.84	0.987
SPL/PC	0.85±0.16	0.77±0.18	0.028
BPL (cm)	1.68±0.82	2.24±0.63	<0.001
CIs (BPL/SPL ratio)	0.43±0.13	0.65±0.08	<0.001
Cic (BPL/PC ratio)	0.36±0.13	0.50±0.12	<0.001
Postoperative			
SPL (cm)	4.48±1.38	4.22±1.24	0.345
PC (cm)	5.29±1.47	4.81±1.39	0.026
SPL/PC	0.85±0.13	0.88±0.12	0.277
BPL (cm)	3.45±1.16	3.11±0.95	0.125
CIs (BPL/SPL ratio)	0.77±0.10	0.74±0.06	0.016
Cic (BPL/PC ratio)	0.66±0.14	0.65±0.12	0.676

Values are presented as mean±standard deviation. BMI, body mass index; SPL, stretched penile length; PC, penile circumference; BPL, baseline penile length; CIs, concealed index according to SPL; Cic, concealed index according to circumference. <sup>a</sup>:Mann–Whitney test.

factors during the second and third trimesters of pregnancy.

Maizels et al. [9] provided classification and definitions of each entity of penile concealment. According to their work, the phallus may be hidden from view as a buried, webbed, trapped, micro or diminutive penis. A buried penis is where the penile shaft is buried below the surface of prepubic skin. A webbed penis is a condition where the scrotal skin webs the penoscrotal angle to obscure the penis. In a trapped penis, the shaft of the penis is entrapped in scarred, prepubic skin following trauma (overzealous circumcision). A micro-

penis is a normally formed penis with a stretched length that is less than 2 standard deviations below the mean and usually is thought to be the consequence of an underlying endocrinopathy. A diminutive penis is a penis that is small and/or malformed as a consequence of epispadias/exstrophy, severe forms of hypospadias, chromosomal abnormalities, or an intersex condition.

Methods to diagnose a CP have been described in various ways by different researchers. Bergeson et al. [13] defined an inconspicuous penis as a group of conditions in which the penis appears small but the shaft can be normal or abnormal size. Cimador et al. [14] used the term “inconspicuous penis” to refer to a group of anatomical abnormalities in which the penis appears small for the age of the patient. Yang et al. [15] described the appearance of a CP on physical examination. They suggested that all patients had the initial appearance of a short penis with minimal penile shaft skin and the normal penile shaft could be palpated and visualized while applying pressure on both sides of the shaft base. All patients enrolled in their study had phimosis and those with obesity/previous penile surgery were excluded. In our study, 69.5% of the patients in the CP group had type I (severe) phimosis. Xu et al. [16] characterized a CP as one that is diagnosed as a flat or beak-shaped penis, with a shorter penile length appearance than that of their peers. However, compression at the pubic skin of the penile root could reveal a normal penile length. Ge et al. [17] reported that all parameters of the CP were measured during the preoperative physical examination and all patients had a flat or beak-shaped penis with minimal penile shaft skin, and the normal penile shaft could be palpated while applying pressure on the opposite side of the shaft base.

The visual inspection of the external genitalia, especially the penis, during the physical examination is not enough to characterize the penile condition in detail [18,19]. Moreover,

it is difficult to analyze a patient's improvement objectively after surgical correction. The published papers on this topic so far have lacked objective tools that could present the diagnosis and severity of the condition. In the current study, we introduced a new objective tool, the concealed index, which can be used for distinguishing a NP from a CP. The concealed index was a reliable tool in diagnosing as well as in prognosing the condition.

An ROC analysis was conducted to find the concealed index cutoff value to distinguish a NP from a CP in this study. For that, the CIs (BPL/SPL ratio) of the NP and the CP patients were compared and the cutoff value was found to be 0.68, with a sensitivity and specificity of 86.7% and 65%, respectively. The CIc (BPL/PC ratio) of the NP and the CP patients were compared and the cutoff value was found to be 0.58, with a sensitivity and specificity of 86.7% and 88.5%, respectively. Therefore, we can use the obtained cutoff values as an objective tool in the diagnosis of a CP if the CIs is less than 0.68 or the CIc is less than 0.58. Among the two indexes, we prefer the CIc, because the CIs uses the SPL. In pediatric patients, it is not easy and physically difficult to measure the penile length with stretching, especially if the patient is uncooperative. In this study, we found that the PC was similar to the SPL in prepubertal children. Moreover, the CIc had a higher specificity than the CIs. Therefore, we recommend using the CIc instead of the CIs.

In several studies, the impact of the BMI on the penis concealment was studied among the physical parameters. Obesity has been considered the acquired cause of CP, especially redundant fat tissue in the suprapubic area [4]. When we analyzed the difference according to age, height, weight, or BMI, there were differences in all penile and testicular parameters except the concealed index (Supplementary Table 1). Correspondingly, our research result also confirmed that the concealed index was not affected by the physical parameters of the patient. Hence, we concluded that the concealed index is a powerful objective tool in usage.

To demonstrate an improvement in the penile condition after surgical correction for the CP, the preoperative and postoperative penile parameters (BPL, PC, SPL, CIs, and CIc) of the CP patients were compared. All of the parameters showed statistically significant improvement. The aforementioned penile parameters served as useful objective parameters to evaluate postoperative outcomes. The larger postoperative PC was the result of the development of postoperative penile edema, which is a common condition after repair. This has also been reported frequently in previously published studies [5-7,15].

To identify whether the postoperative penile parameters

reached the normal penile parameters after surgical correction, we compared the 3-month postoperative penile parameters with normal parameters. Only the postoperative BPL was similar to that in the NP group. All the other penile parameters were significantly different from those of the NP group. Even though the repair of CP was performed successfully, concealed penile parameters did not reach the normal values according to the CIs and the CIc.

The preoperative CIs improved after surgical correction in both group A and group B patients with remarkable improvement in the former. The comparison of the differences between the preoperative and postoperative concealed indexes of the two groups revealed that patients with severe concealment (lower CIs) of the penis at baseline showed better improvement after CP repair. Accordingly, based on the degree of improvement, the patients were divided into the more improved and the less improved groups.

There were several limitations to our study. First, this study was performed as a retrospective review of the medical record. We collected all data during physical examinations in routine clinical practice with the purpose of checking the developmental genital state of all patients at the first visit. Therefore, little bias was used to obtain the data.

Second, the patient numbers were unequally distributed among the age groups (more patients were younger than 2 years old) because CP is diagnosed more often at younger ages. Therefore, we used a normal patient group with each age-matched control that included an equal proportion of patients in each group.

Third, the patients in the NP group were not all healthy controls. Patients without penile problems, but with other problems such as hydrocele, lower urinary tract dysfunction, urinary tract infection, and inguinal hernia were included in the NP group. As these conditions are not the normal, but do not affect the penile parameters, and we believe they can be used as a normal control group.

## CONCLUSIONS

The concealed index is a useful tool for diagnosing and determining the severity of CP and evaluating the postoperative outcomes of CP repair. We newly introduced cutoff values for the CIs (0.68) and CIc (0.58) for diagnosing and evaluating CP repair. Further prospective multicentric studies with a larger sample size are needed to better identify the reliability and applicability of the concealed index.

## CONFLICTS OF INTEREST

The authors have nothing to disclose.

## ACKNOWLEDGMENTS

This study was supported by a 2020 research grant from Pusan National University Yangsan Hospital.

## AUTHORS' CONTRIBUTIONS

Research conception and design: Jae Min Chung. Data acquisition: Jae Min Chung. Statistical analysis: Kobiljon Ergashev and Jae Min Chung. Data analysis and interpretation: Kobiljon Ergashev and Jae Min Chung. Drafting of the manuscript: Kobiljon Ergashev and Jae Min Chung. Critical revision of the manuscript: Kobiljon Ergashev and Jae Min Chung. Obtaining funding: Jae Min Chung. Administrative, technical, or material support: Kobiljon Ergashev and Jae Min Chung. Supervision: Jae Min Chung and Sang Don Lee. Approval of the final manuscript: Jae Min Chung and Sang Don Lee.

## SUPPLEMENTARY MATERIAL

Supplementary material can be found via <https://doi.org/10.4111/icu.20200401>.

## REFERENCES

- Hadidi AT. Buried penis: classification surgical approach. *J Pediatr Surg* 2014;49:374-9.
- Chin TW, Tsai HL, Liu CS. Modified prepuce unfurling for buried penis: a report of 12 years of experience. *Asian J Surg* 2015;38:74-8.
- El-Koutby M, Mohamed Amin el G. Webbed penis: a new classification. *J Indian Assoc Pediatr Surg* 2010;15:50-2.
- Palmer LS, Palmer JS. Management of abnormalities of the external genitalia in boys. In: Wein AJ, Kavoussi LR, Partin AW, Peters CA. *Campbell-Walsh urology*. 11th ed. Philadelphia: Elsevier; 2016.
- Lee T, Suh HJ, Han JU. Correcting congenital concealed penis: new pediatric surgical technique. *Urology* 2005;65:789-92.
- Frenkl TL, Agarwal S, Caldamone AA. Results of a simplified technique for buried penis repair. *J Urol* 2004;171(2 Pt 1):826-8.
- Borsellino A, Spagnoli A, Vallasciani S, Martini L, Ferro F. Surgical approach to concealed penis: technical refinements and outcome. *Urology* 2007;69:1195-8.
- Sun J, Zhao HT, Zhong L, Zou XY. [Application of penile index in the diagnosis and therapeutic evaluation of concealed penis in children]. *Zhonghua Yi Xue Za Zhi* 2020;100:1708-10. Chinese.
- Maizels M, Zaontz M, Donovan J, Bushnick PN, Firlit CF. Surgical correction of the buried penis: description of a classification system and a technique to correct the disorder. *J Urol* 1986;136(1 Pt 2):268-71.
- Crawford BS. Buried penis. *Br J Plast Surg* 1977;30:96-9.
- Hinman F Jr. Microphallus: distinction between anomalous and endocrine types. *J Urol* 1980;123:412-5.
- Bloom DA. Virga obscura. *Dialogues Pediatr Urol* 1993;16:8.
- Bergeson PS, Hopkin RJ, Bailey RB Jr, McGill LC, Piatt JP. The inconspicuous penis. *Pediatrics* 1993;92:794-9.
- Cimador M, Catalano P, Ortolano R, Giuffrè M. The inconspicuous penis in children. *Nat Rev Urol* 2015;12:205-15.
- Yang T, Zhang L, Su C, Li Z, Wen Y. Modified penoplasty for concealed penis in children. *Urology* 2013;82:697-700.
- Xu JG, Lv C, Wang YC, Zhu J, Xue CY. Management of concealed penis with modified penoplasty. *Urology* 2015;85:698-702.
- Ge W, Zhu X, Xu Y, Chen Y, Wang J. Therapeutic effects of modified Devine surgery for concealed penis in children. *Asian J Surg* 2019;42:356-61.
- Ryu DS, Cho WY, Chung JM, Kang DI, Lee SD, Park S. Comparison of penile length at 6-24 months between children with unilateral cryptorchidism and a healthy normal cohort. *Investig Clin Urol* 2018;59:55-60.
- Ahn ST, Lee DH, Jeong HG, Kim JW, Moon DG. Scrotal septum detachment during penile plication to compensate for loss of penile length compared with conventional surgical technique. *Investig Clin Urol* 2020;61:224-30.