

Comparison of the clinical efficacy of percutaneous transforaminal endoscopic discectomy and traditional laminectomy in the treatment of recurrent lumbar disc herniation

Shifeng Jiang, MM^a, Qingning Li, MM^b, Hongzhi Wang, PhD^{a,*}

Abstract

A few years ago, percutaneous transforaminal endoscopic discectomy (PTED) began to prevail in clinical treatment of recurrent lumbar disc herniation (RLDH), whereas traditional laminectomy (TL) was treated earlier in RLDH than PTED. This study aimed to compare the clinical efficacy of PTED and TL in the treatment of RLDH.

Between November 2012 and October 2017, retrospective analysis of 48 patients with RLDH who were treated at the Cancer Hospital, Chinese Academy of Sciences, Hefei and Department of Orthopaedics, Second Affiliated Hospital of Anhui Medical University. Perioperative evaluation indicators included operation time, the intraoperative blood loss, length of incision and hospitalization time. Clinical outcomes were measured preoperatively, and at 1 days, 3 months, and 12 months postoperatively. The patients' lower limb pain was evaluated using Oswestry disability index (ODI) and visual analog scale (VAS) scores. The ODI is the most widely-used assessment method internationally for lumbar or leg pain at present. Every category comprises 6 options, with the highest score for each question being 5 points. Higher scores represent more serious dysfunction. The VAS is the most commonly-used quantitative method for assessing the degree of pain in clinical practice. The measurement method is to draw a 10 cm horizontal line on a piece of paper, 1 end of which is 0, indicating no pain, which the other end is 10, which means severe pain, and the middle part indicates different degree of pain.

Compared with the TL group, the operation time, postoperative bed-rest time, and hospitalization time of the PTED group were significantly shorter, and the intraoperative blood loss was also reduced. These differences were statistically significant ($P < .01$). There were no significant differences in VAS or ODI scores between the two groups before or after surgery ($P > .05$).

PTED and TL have similar clinical efficacy in the treatment of RLDH, but PTED can shorten the operation time, postoperative bed-rest time and hospitalization time, and reduce intraoperative blood loss, so the PTED is a safe and effective surgical method for the treatment of RLDH than TL, but more randomized controlled trials are still required to further verify these conclusions.

Abbreviations: ODI = Oswestry Disability Index, PTED = percutaneous transforaminal endoscopic discectomy, RLDH = recurrent lumbar disc herniation, TL = traditional laminectomy, VAS = visual analog scale.

Keywords: efficacy, percutaneous transforaminal endoscopic discectomy, recurrent lumbar disc herniation, traditional laminectomy

Editor: Somchai Amorniyotin.

SJ and QL contributed equally to this work.

The authors have no conflicts of interest to disclose.

The datasets generated during and/or analyzed during the current study are publicly available.

^a Department of Orthopaedics, Cancer Hospital, Chinese Academy of Sciences, Hefei, Shushan lake road No.350, shushan district, hefei city, Anhui Province, china, ^b Department of Orthopaedics, The Second Affiliated Hospital of Anhui Medical University, 678 Furong Road, Hefei, Anhui, China.

* Correspondence: Hongzhi Wang, Department of Orthopedics, The second affiliated Hospital of Anhui Medical University, Shushan lake road No.350, shushan district, hefei city, anhui province, china (e-mail: liqn1986@163.com).

Copyright © 2021 the Author(s). Published by Wolters Kluwer Health, Inc. This is an open access article distributed under the terms of the Creative Commons Attribution-Non Commercial License 4.0 (CCBY-NC), where it is permissible to download, share, remix, transform, and build up the work provided it is properly cited. The work cannot be used commercially without permission from the journal.

How to cite this article: Jiang S, Li Q, Wang H. Comparison of the clinical efficacy of percutaneous transforaminal endoscopic discectomy and traditional laminectomy in the treatment of recurrent lumbar disc herniation. *Medicine* 2021;100:30(e25806).

Received: 23 October 2019 / Received in final form: 2 April 2021 / Accepted: 15 April 2021

<http://dx.doi.org/10.1097/MD.00000000000025806>

1. Introduction

Recurrent lumbar disc herniation (RLDH) refers to patients with lumbar disc herniation who obtained relief for more than half a year after an initial operation, but after which the disc on the original surgical side protrudes again causing neurological symptoms.^[1] Patients with lumbar disc herniation usually first undergo conservative treatment. For patients for whom conservative treatment is ineffective, traditional laminectomy (TL) is often used in clinical practice, but this procedure is associated with a certain recurrence rate after operation.^[2] Patients with recurrence after surgery, if the spine is not clearly unstable, can be treated by surgical removal of the disc by the original approach, but there is scar tissue adhesion in the original operation area, and reoperation can lead to destruction of the posterior structure of the spine.^[3,4] In the past few decades, with the rapid development of endoscopic instruments and minimally-invasive techniques, Percutaneous transforaminal endoscopic discectomy (PTED) has achieved good results in the treatment of lumbar disc herniation compared with TL, with a reliable curative effect, small trauma, and good protection for muscle and other tissue structures. Therefore, the authors conjecture that PTED may also be an effective treatment for RLDH. Thus, in this study, the

author retrospectively analysed 48 patients with RLDH from November 2012 to October 2017, and explored the clinical application of PTED in RLDH. The clinical efficacy of the two surgical methods was compared and the advantages of PTED were explored.

2. Materials and methods

2.1. Patient population

From November 2012 to October 2017, 48 patients with RLDH, treated at the Department of Orthopaedics, the Cancer Hospital, Chinese Academy of Sciences, Hefei and Department of Orthopaedics, Second Affiliated Hospital of Anhui Medical University, were selected to participate in this study. Our study protocol was approved by the ethics committee of the Cancer Hospital, Chinese Academy of Sciences and the Second Affiliated Hospital of Anhui Medical University. They were divided into a PTED group and a TL group according to the different surgical methods employed. There were 24 patients in the PTED group, comprising 15 males and 9 females; their ages ranged from 26 to 77 years, with a mean of 44.9 ± 6.8 years; the course of disease was 3 to 78 months, with an average of 55.3 ± 5.8 months. The lesion segment was L4/5 in 15 cases, and L5/S1 in 9 cases. There were 24 patients in the TL group, comprising 14 males and 10 females; their ages ranged from 25 to 74 years, with a mean of 45.7 ± 7.4 years; the course of disease was 4 to 77 months, with an average of 56.8 ± 6.1 months. The lesion segment was L4/5 in 14 cases, and L5/S1 in 10 cases of. There were no significant differences in gender, age, course of disease, or lesion segment between the two groups ($P > .05$), as shown in Table 1.

2.2. Selection criteria

Inclusion criteria:

- (1) Patients with single-segment lumbar disc herniation, who had undergone traditional laminectomy;
- (2) Patients who experienced pain relief for more than 6 months after the first surgery;
- (3) Those who have underwent strict conservative treatment for more than 3 months, but with no obvious effect;
- (4) Those who experienced weakening muscle strength and a feeling of numbness in the innervation area caused by the last lumbar disc herniation; and
- (5) Those whereby CT, MRI and other imaging examinations showed that the RLDH was in the same segment.

Table 1
Comparison of general data of patients with postoperative recurrence of lumbar disc herniation.

Variables	PTED group (n=24)	TL group (n=24)	P value
Gender (Male/Female)	15/9	14/10	.753
Average age (m) (x±SD)	44.9±6.8	45.7±7.4	.742
Recurrent segment			
L4-5	15	14	.532
L5-S1	9	10	
Course of disease	55.3±5.8	56.8±6.1	.825
Number of patients	24	24	—

PTED = percutaneous transforaminal endoscopic discectomy, SD = standard deviation, TL = traditional laminectomy.

Exclusion criteria:

- (1) Patients with lumbar disc herniation at two or more segments;
- (2) Patients with spinal deformity, obvious lumbar instability, or lumbar spinal stenosis;
- (3) After the first operation, the patient's pain, numbness and other symptoms were not relieved;
- (4) Patients with bowel or urinary dysfunction caused by compression of the cauda equina;
- (5) Patients with spinal infections, tumours or tuberculosis, as well as coagulopathy, severe cardiopulmonary dysfunction and other diseases.

2.3. Surgical procedures

PTED group: The patient was placed in the prone position (Fig. 1). After the puncture path was determined by C-arm fluoroscopy (Fig. 3A), local anaesthesia was administered by inserting the needle into the corresponding intervertebral disc along the intervertebral foramen, and the patient was asked whether they felt pain. After confirming that the position of the puncture needle was good, observe the condition of the intervertebral disc protrusion was observed. The guide wire was then inserted, an incision of about 8 mm was created, and expanded step by step. Under C-arm fluoroscopy, the patient was treated by intervertebral foraminoplasty, paying attention to the patient's pain and avoiding nerve damage. After completion of the operation, the working channel and the endoscope were placed, and the fluoroscopy was again used to confirm the position of the working catheter in the intervertebral disc. The intervertebral foramen imaging system was connected and the nerve root and dural sac were decompressed using a nucleus pulposus clamp. The nucleus pulposus tissue was removed (Fig. 3B), the nerve root was decompressed, and the incision was sutured to complete the surgery.

TL group: Patients received epidural anaesthesia or general anaesthesia (Fig. 2). Before surgery, the C-arm machine was used to locate the lesion space. The previous surgical scar was marked, and a posterior median incision about 5 cm long was created, then tissues were separated layer by layer to reveal the articular processes and the lamina (Fig. 3C). The epidural scars were removed slowly to reveal the nerve roots and dural sac. If necessary, the bone window was expanded, the nerve root was separated and the intervertebral disc was exposed, then the nucleus pulposus of the intervertebral disc was removed. The lateral crypt was then enlarged, and adhesion and compression of the nerve root tissue were released, so that the left and right movement range was approximately 8 mm. The deep layer of the incision was continuously flushed with physiological saline, a negative pressure drainage tube was placed, A fixator with a fusion device was used to fix the operative segmental area (Fig. 3D), and the incision was sutured to complete the surgery.

2.4. Postoperative care

All patients were routinely given antibiotics to prevent infection 30 minutes before surgery and two days after surgery; Patients in the PTED group were immediately able to perform double lower limb elevation exercises in bed after the operation, able to walk with protection of the waistline, and able to exercise the back muscles one day after surgery. Patients in the TL group were able to perform double lower limb elevation exercises in bed one day

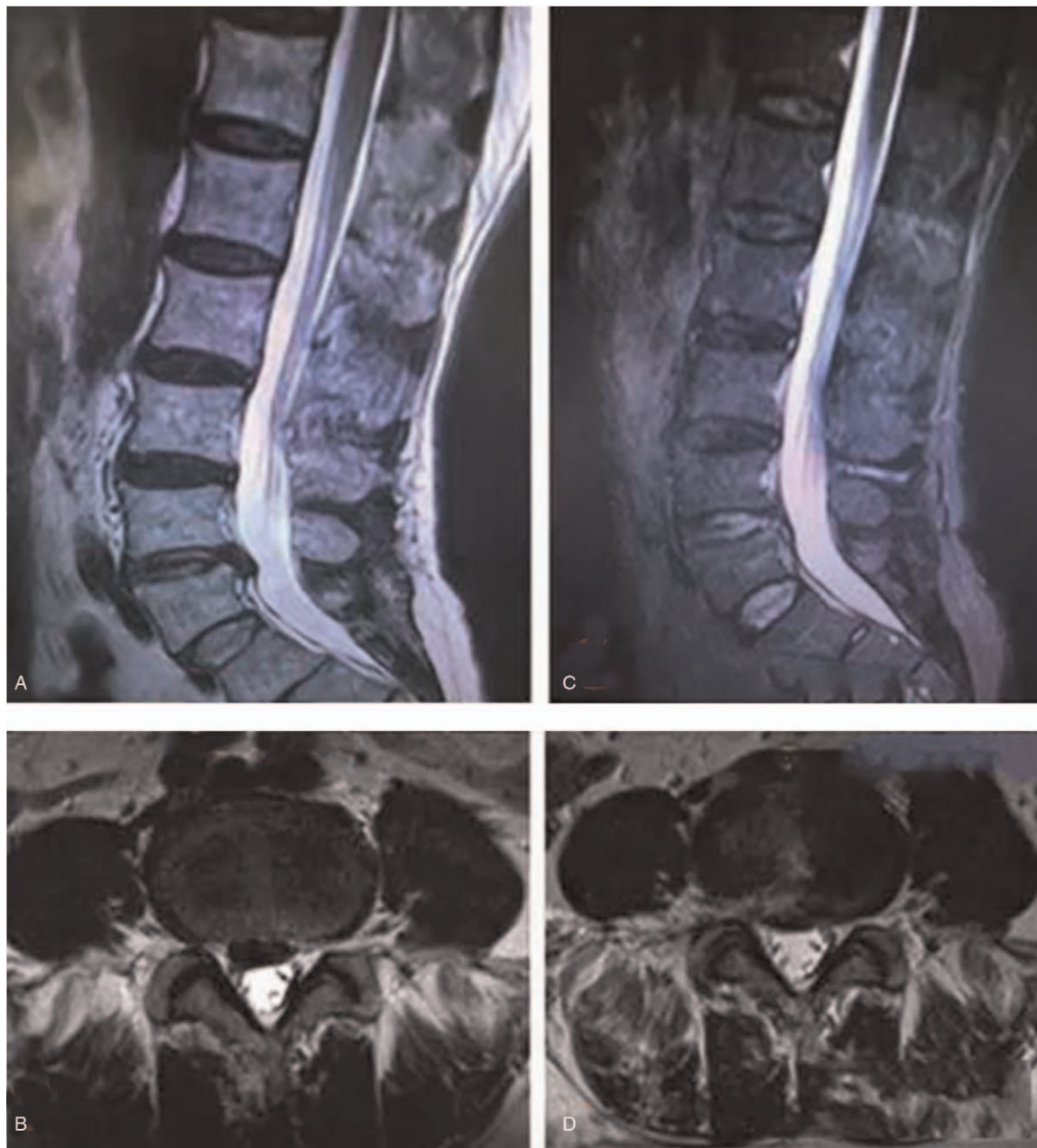


Figure 1. The patient had a protrusion in the right portion of the L4/L5 intervertebral disc. (A) In the sagittal section, MRI showed an L4/L5 intervertebral disc protrusion on the right. (B) In the cross section, a protrusion could be seen in the right portion of the L4/L5 intervertebral disc, and the nerve roots were compressed. (C) Six months after surgery, In the sagittal section, MRI showed no significant protrusion in the L4/L5 intervertebral disc. (D) Six months after surgery, cross-sections showed no significant protrusion in the L4/L5 intervertebral discs, and the nerve roots were not compressed. MRI = magnetic resonance imaging.

after surgery, and to walk with protection of the waistline seven days after surgery.

2.5. Observation indicators

The following indicators were evaluated in the two groups of patients and compared:

- (1) Perioperative indicators: including operation time, intraoperative blood loss, length of incision, length of hospital stay, etc.;
- (2) postoperative complications;

- (3) visual analog scale (VAS) scores and Oswestry Disability Index (ODI) scores of patients preoperatively and at 1 day, 3 months, and 1 year postoperatively.

2.6. Statistical analysis

Data were statistically analysed using the statistical software SPSS 24.0. Measurement data are expressed as mean \pm standard deviation (SD), Intra-group comparisons were performed using paired T-tests, comparison between groups using independent

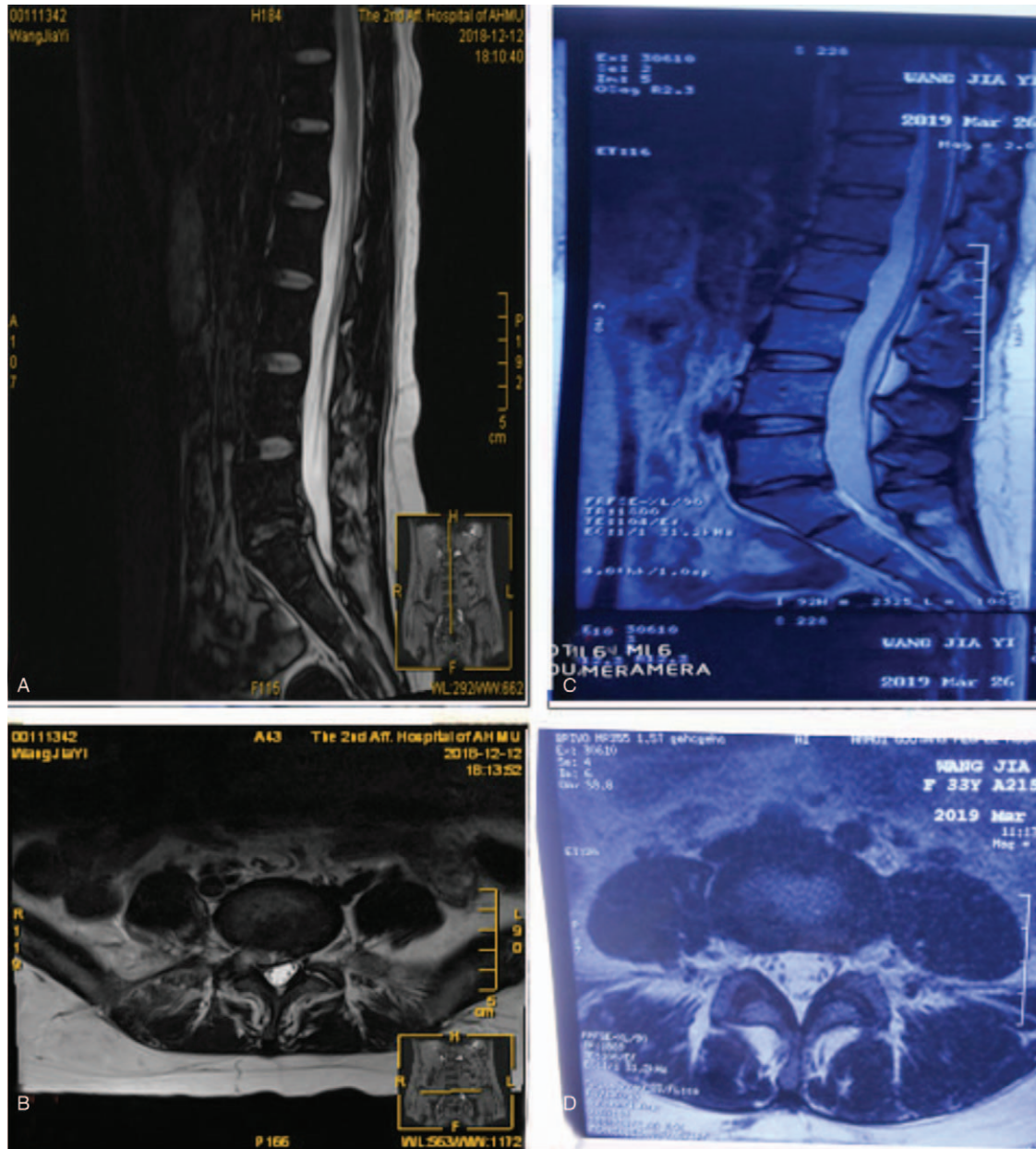


Figure 2. The patient had a protrusion in the right portion of the L5/S1 intervertebral disc. (A) In the sagittal section, MRI showed an L5/S1 intervertebral disc protrusion on the right. (B) In the cross section, a protrusion could be seen in the right portion of the L5/S1 intervertebral disc, and the nerve roots were compressed. (C) Three months after surgery, in the sagittal section, MRI showed no significant protrusion in the L5/S1 intervertebral disc. (D) Three months after surgery, cross-sections showed no significant protrusion in the L5/S1 intervertebral discs, and the nerve roots were not compressed. MRI = magnetic resonance imaging.

sample T-tests. The count data are expressed by the number of cases and percentage, and comparison between groups was performed by χ^2 test. $P < .05$ was considered statistically significant. $P < .01$ was considered obviously statistically significant.

3. Results

3.1. Postoperative complications

Both groups of patients successfully completed the surgery (Fig. 1, Fig. 2), with no serious complications such as damage to large blood vessels or nerves during operation. One patient in the

PTED group suffered intervertebral space infection but recovered after anti-inflammatory treatment. In the TL group, two patients developed aggravation of lower extremity neurological symptoms, which improved after treatment with nutritional nerves, hormones, and dehydration. The incidence of complications was 4.2% (1/24) in the PTED group and 8.3% (2/24) in the TL group, but the difference was not statistically significant ($\chi^2 = 1.867$; $P = .172$) (Table 2).

3.2. Perioperative indicators

Comparison of perioperative indicators between the two groups of patients, as shown in Table 3, revealed that the operation time,

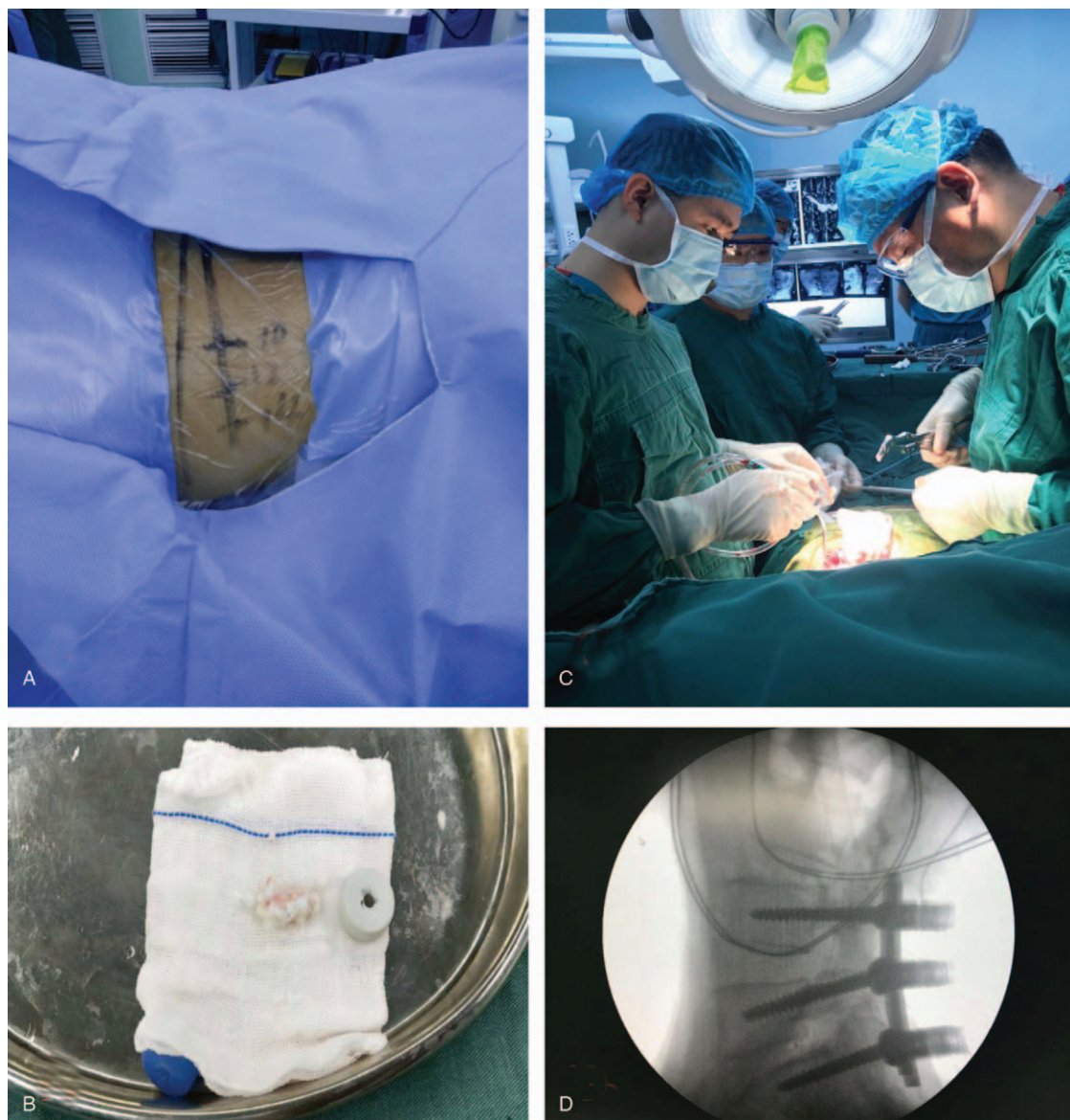

Figure 3. Intraoperative and postoperative pictures of the two groups of patients. (A) Localization during PTED surgery. (B) The nucleus pulposus from PTED surgery. (C) Hemostasis during TL surgery. (D) fixed after TL surgery. PTED = percutaneous transforaminal endoscopic discectomy, TL = traditional laminectomy.

hospitalization time, amount of bleeding and length of incision in the PTED group were significantly shorter than those in the TL group, and the differences were statistically significant ($P < .01$).

3.3. VAS and ODI score comparison

Both groups were followed up for 14 to 26 months, with a mean of 17.1 months. The VAS and ODI scores before and after surgery

Table 2
Comparison of the incidence of complications between the two groups (%).

Groups	The incidence of complications	χ^2 value	P value
PTED group	4.2% (1/24)	1.867	.172
TL group	8.3% (2/24)		

PTED = percutaneous transforaminal endoscopic discectomy, TL = traditional laminectomy.

are shown in Tables 4 and 5. Scores one day, three months and one year after operation in both groups were compared with scores before operation, and both indicators showed significant differences ($P < .05$); however, there was no significant difference between the two groups ($P > .05$).

4. Discussion

TL is a commonly used surgical method and can achieve excellent results. However some patients will still experience recurrent disc herniation after surgery, with a recurrence rate reported in the literature of about 5% to 18%.^[5-7] The reasons for recurrence are mainly related to the following aspects:

- (1) The nucleus pulposus of the intervertebral disc was not completely removed during the operation, and the residual nucleus pulposus tissue underwent accelerated degeneration and protruded again;

Table 3
Comparison of perioperative indicators between the two groups (x ± s).

Groups	Number	Operation time (min)	Amount of bleeding (ml)	Length of incision (cm)	Hospitalization time (d)
PTED group	24	65.3 ± 12.5	28.6 ± 4.7	0.92 ± 0.16	4.7 ± 1.2
TL group	24	78.6 ± 15.4	57.2 ± 8.3	4.41 ± 0.57	8.6 ± 1.3
t value	—	4.512	20.790	42.340	14.659
P value	—	<.01	<.01	<.01	<.01

PTED = percutaneous transforaminal endoscopic discectomy, TL = traditional laminectomy.

- (2) When the articular process joint removed during surgery exceeded 50%, postoperative small joint degeneration could occur as a result, leading to lumbar instability and recurrence of symptoms;
- (3) The patient did not undergo scientific rehabilitation exercise after surgery, or bent over too early, participated in high-intensity work related to lumbar motion for a long time, or had a history of lumbar trauma or fatigue^[8];
- (4) Postoperative scar tissue adhesion to the dura mater and nerve root, or scar tissue compressing the dura mater and nerve roots;
- (5) Lumbar disc herniation was combined with spinal canal, nerve root canal and lateral recess stenosis, but was not effectively treated during the first operation. Although there are many related reasons, the main reason for recurrence is still residual intervertebral disc nucleus pulposus tissue, which compresses nerve roots and causes neurological symptom recurrence.^[9]

The treatment principle of reoperation for RLDH is still based on nerve decompression. However, during the operation, the orthopaedic surgeon should pay attention to reducing the damage caused by reoperation. In the past, for those who had not been diagnosed with lumbar instability, most surgical methods used the original surgical approach. When the operation is performed via the original surgical approach, the muscle tissue needs to be re-incised, and the structure of the posterior lamina and the facet joint is further destroyed; at the same time, the probability of damage to the dorsal branch of the spinal nerve is increased.^[10,11] In addition, when the original surgical approach is used during reoperation, the scar tissue at the dura mater and the nerve root needs to be peeled off. If the operation is not performed properly, the dura mater may be torn (three cases in the TL group), or nerve root damage may be aggravated (two cases in the TL group).^[12] Moreover, the trauma of the second operation through the original approach will also increase the incidence of low back pain after surgery.^[13]

In contrast, PTED has the following advantages:

- (1) It uses the posterior lateral approach, thus avoiding the original surgical scar, therefore, when the surgical channel is

established, it is not affected by scars and adhesion tissues, and the related complications caused by peeling scar tissue are also reduced simultaneously.

- (2) Percutaneous transforaminal microsurgery in the process of decompression of the spinal canal only needs to remove part of the superior articular process, which will not lead to postoperative spinal instability, so there is no need for internal fixation and the patient can get out of bed early.^[14]
- (3) There is no need to pull the nerve root during operation. If there is nerve root compression on the ventral side compression, it is easier to handle, and the interference in the intraspinal canal is smaller, reducing the amount of bleeding in the intraspinal canal venous plexus.
- (4) For elderly patients with poor cardiopulmonary function, the lateral position can be selected for the percutaneous transforaminal approach, thereby reducing interference with the heart and lungs and ensuring the operation is carried out smoothly;
- (5) The surgical incision is small, only about 8 mm, and the operation can be performed under local anaesthesia, so that the patient stays awake during the operation, which is beneficial in allowing the orthopaedic surgeon and the patient to communicate at any time, reducing the probability of nerve damage, and also avoiding the risk of general anaesthesia or epidural anaesthesia.

In this study, the incidence of complications, and the postoperative VAS and ODI scores in the two groups were similar ($P > .05$), indicating that there was no significant difference in efficacy or safety between the two surgical methods. However, in the comparison of perioperative indices such as operation time, intraoperative blood loss, incision length, and hospitalization time, the PTED group showed significant advantages. Our findings confirmed that percutaneous transforaminal surgery has advantages including short operation time, small trauma and quick recovery after operation. At the same time, it should be noted that patients should be considered carefully for the following situations:^[1] The percutaneous transforaminal technique has a definite effect on ventral compression of nerve roots, but for those with neurological

Table 4
Comparison of ODI scores before and after surgery in the two groups (x ± s).

Groups	Number	Before surgery	1 d after surgery	3 mo after surgery	1 yr after surgery
PTED group	24	39.87 ± 7.65*	11.34 ± 1.89*	6.86 ± 2.13*	2.61 ± 1.55*
TL group	24	41.53 ± 6.98*	12.52 ± 1.95*	7.02 ± 2.24*	2.64 ± 1.62*
t value	—	1.049	0.632	0.343	0.089
P value	—	.297	.534	.732	.930

ODI = Oswestry Disability Index.

* indicates contrast with preoperative, $P < .05$.

Table 5**Changes in VAS scores before and after surgery in both groups (x±s).**

Groups	Number	Before surgery	1 d after surgery	3 mo after surgery	1 yr after surgery
PTED group	24	8.65±1.57	2.21±0.85*	0.95±0.32*	0.43±0.26*
TL group	24	8.57±1.62	2.17±0.64*	0.87±0.31*	0.47±0.30*
t value	—	0.235	0.242	1.182	0.674
P value	—	.815	.809	.240	.502

PTED = percutaneous transforaminal endoscopic discectomy, TL = traditional laminectomy, VAS = visual analog scale.

* indicates contrast with preoperative, $P < .05$.

symptoms caused by compression of the dorsal scar, it is difficult to separate, and the channel is narrow and the probability of nerve root damage is higher^[7]; (2) Patients with nerve root mutations have a higher probability of injury under the percutaneous transforaminal approach; therefore, orthopaedic surgeons should be more cautious when selecting patients as candidates for surgery, and not force the expansion of surgical indications.

The percutaneous transforaminal technique is more dependent on the perspective of the C-arm machine for puncture positioning in the process of placing the working channel. If the operator is not skilled, it often requires multiple punctures; and the perspective time is longer. In addition, the learning curve of this technology is steep, especially for patients with RLDH, thus the technical requirements of the surgeon are higher.

5. Conclusions

In conclusion, according to our results, the incidence of complications and the postoperative VAS and ODI scores in the two groups showed no significant difference, but in regard to operation time, intraoperative blood loss, incision length, and hospitalization time, the PTED group showed significant advantages. Further investigation with more patients is necessary.

Acknowledgments

The authors would like to thank all the participants in the studies.

Author contributions

Conceptualization: Qingning Li.

Data curation: Qingning Li, Hongzhi Wang.

Formal analysis: Qingning Li, Hongzhi Wang.

Methodology: Qingning Li, Hongzhi Wang.

Resources: Shifeng Jiang, Qingning Li.

Software: Shifeng Jiang, Qingning Li, Ziyu Li.

Supervision: Shifeng Jiang, Qingning Li.

Validation: Qingning Li.

Writing – original draft: Shifeng Jiang.

Writing – review & editing: Shifeng Jiang, Hongzhi Wang.

References

- [1] Suk KS, Lee HM, Moon SH, Kim NH. Recurrent lumbar disc herniation: results of operative management. *Spine (Phila Pa 1976)* 2001;26:672–6.
- [2] Ibrahim M, Arockiaraj J, Amritanand R, Venkatesh K, David KS. Recurrent lumbar disc herniation: results of revision surgery and assessment of factors that may affect the outcome. A non-concurrent prospective study. *Asian Spine J* 2015;9:728–36.
- [3] Dai LY, Zhou Q, Yao WF, Shen L. Recurrent lumbar disc herniation after discectomy: outcome of repeat discectomy. *Surg Neurol* 2005; 64:226–31.
- [4] Fu TS, Lai PL, Tsai TT, Niu CC, Chen LH, Chen WJ. Long-term results of disc excision for recurrent lumbar disc herniation with or without posterolateral fusion. *Spine (Phila Pa 1976)* 2005;30:2830–4.
- [5] Azimi P, Mohammadi HR, Benzel EC, Shahzadi S, Azhari S. Use of artificial neural networks to predict recurrent lumbar disk herniation. *J Spinal Disord Tech* 2015;28:E161–5.
- [6] Ghobadifar MA, Pourghardash F, Akbarzadeh A, Mosallanejad Z. Safety of epidural steroid injection methods in the management of recurrent lumbar disc herniation: few comments. *Asian Spine J* 2015; 9:311–2.
- [7] Mroz TE, Lubelski D, Williams SK, et al. Differences in the surgical treatment of recurrent lumbar disc herniation among spine surgeons in the United States. *Spine J* 2014;14:2334–43.
- [8] Kaloostian PE, Gokaslan ZL. Extent of lumbar discectomy in modern-day neurosurgery. *World Neurosurg* 2014;82:640–2.
- [9] Shin BJ. Risk factors for recurrent lumbar disc herniations. *Asian Spine J* 2014;8:211–5.
- [10] Neroni M, Gazzeri R, Conforti G, Visocchi M. State of art of recurrent lumbar disk herniation, interspinous and interlumbal fusions. *J Neurosurg Sci* 2014;58:45–8.
- [11] Nomura K, Yoshida M, Kawai M, Okada M, Nakao S. A novel microendoscopically assisted approach for the treatment of recurrent lumbar disc herniation: transosseous discectomy surgery. *J Neurol Surg A Cent Eur Neurosurg* 2014;75:183–8.
- [12] Tian R, Sun T, Shen X, Zhang X, Jia Y, Hu W. The significance of lumbar MRI in the diagnosis of recurrent lumbar disc herniation after surgery. *Zhonghua Wai Ke Za Zhi* 2014;52:258–62.
- [13] Park JS, Choi SE, Cho TK, et al. Recurrence rate after herniotomy only versus discectomy in lumbar disc herniation. *Korean J Spine* 2013;10: 227–31.
- [14] Sinkemani A, Hong X, Gao ZX, et al. Outcomes of microendoscopic discectomy and percutaneous transforaminal endoscopic discectomy for the treatment of lumbar disc herniation: a comparative retrospective study. *Asian Spine J* 2015;9:833–40.