

## Case Report

# Fluro-deoxygenase-positron emission tomography/ computed tomography in hard metal lung disease

*Kapil Iyer, Vinaya Karkhanis, Sandip Basu<sup>1</sup>, Jyotsna M Joshi*

*Department of Pulmonary Medicine, Topiwala National Medical College, BYL Nair Hospital, <sup>1</sup>Department of Nuclear Medicine, Radiation Medicine Centre, Bhabha Atomic Research Centre, Tata Memorial Hospital, Mumbai, Maharashtra, India*

## ABSTRACT

We report a case of a diamond polisher where FDG-PET/CT was helpful in identifying active inflammation in hard metal lung disease (HMLD) caused by cobalt exposure.

**KEY WORDS:** Cobalt, diamond polishing, High-resolution computed tomography

**Address for correspondence:** Dr. Jyotsna M Joshi, Department of Pulmonary Medicine, Topiwala National Medical College, BYL Nair Hospital, Mumbai - 400 008, Maharashtra, India. E-mail: drjoshijm@gmail.com

## INTRODUCTION

Hard metal is a synthetic compound that combines tungsten carbide with cobalt with proportion of cobalt varying between 5% and 25% by weight.<sup>[1]</sup> Cobalt metal particles, when inhaled in association with other agents such as metallic carbides or diamond dust may produce an interstitial lung disease (ILD) termed “Hard metal lung disease” (HMLD) usually of the giant cell variety.<sup>[2]</sup> Link between cobalt exposure and giant cell interstitial pneumonitis (GIP) was published by Abraham and Spragg.<sup>[3]</sup> With chronic exposure to this dust, there is an inflammatory process that evolves progressively. The role of fluro-deoxygenase-positron emission tomography (FDG-PET)/computed tomography (CT) in infection and inflammatory disorders is being explored as one of its promising areas of applications in recent times. We report a case where FDG-PET/CT was helpful in identifying active inflammation in HMLD caused by cobalt exposure in a diamond polisher.

## CASE REPORT

A 41-year-old man, worked as a diamond polisher for more than 15 years, presented to our department with a 3-year

history of dry cough and progressive breathlessness on exertion. Examination revealed grade 3 clubbing, exercise desaturation and bilateral bibasilar fine end inspiratory crackles. Routine hematological and biochemical values were normal including ACE level as 33U/l. An arterial blood gas analysis was normal but showed an increased alveolar-arterial gradient. Chest radiograph [Figure 1] showed bilateral reticulonodular opacities. Spirometry was suggestive of severe restrictive abnormality with forced vital capacity (FVC) of 1.38 liters (31%), forced expiratory volume in first second (FEV<sub>1</sub>) of 1.24 liters (35%), FEV<sub>1</sub>/FVC ratio of 89, and diffusion of lung for carbon monoxide (DLCO) of 10.08 ml/min/mmHg (35% predicted). High-resolution computed tomography (HRCT) of thorax revealed ill-defined patchy areas of confluent centrilobular nodules with a central and peripheral distribution pattern and fissural nodules with mildly enlarged mediastinal lymph nodes [Figure 2]. Whole body positron emission tomography – computed tomography (WB PET-CT) was done to see extent of underlying inflammation. It showed diffuse low-grade fluorodeoxy glucose (FDG) uptake in bilateral lungs with sparing of peripheral right middle lobe laterally, and low to moderate FDG uptake in right paratracheal, subcarinal, right tracheobronchial, bilateral hilar, bilateral inguinal lymph nodes and aortopulmonary window [Figure 3]. An analysis of the powder used for polishing diamonds at his workplace was performed. It revealed a high quantity of Cobalt -24.65 parts per million. The patient refused lung biopsy. However, in view of significant occupational exposure to cobalt, HRCT findings and normal ACE levels, diagnosis of hard metal disease due to cobalt exposure was made. He was advised to change his job. Steroids i.e., tablet prednisolone 40 mg was given as

### Access this article online

Quick Response Code:



Website:

[www.lungindia.com](http://www.lungindia.com)

DOI:

10.4103/0970-2113.164160

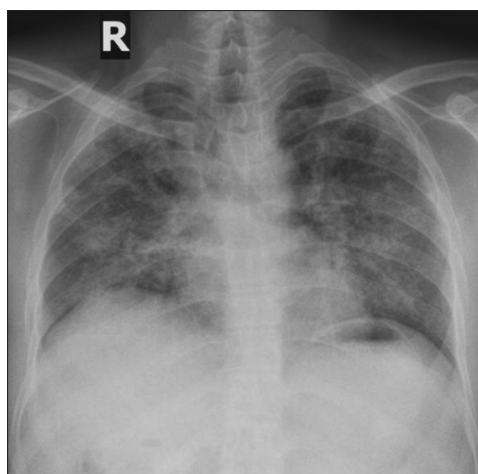
diagnosis could not be proven with biopsy and FDG-PET scan showed increased uptake suggesting underlying inflammation. One year later his lung functions were stable with FVC-1.38, FEV<sub>1</sub>-1.29 and FEV<sub>1</sub>/FVC ratio-93. Follow-up HRCT after 1 year showed similar findings as baseline.

## DISCUSSION

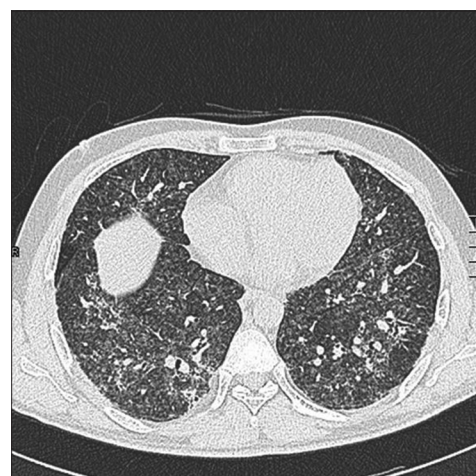
Hard metal is an alloy of tungsten carbide and a cobalt matrix to which smaller amounts of titanium, nickel, chromium, niobium, vanadium, tantalum, or molybdenum are added.<sup>[4]</sup> Its extreme toughness is conducive for its use in oil well drills, machine parts, armor plates, jet engine exhaust ports, aeronautical, automobile, electrical, oil and mining industries, diamond cutters and polishers.<sup>[5-7]</sup> Metallic dust particles less than 2  $\mu\text{m}$  are ideal for alveolar deposition and lead to respiratory manifestations. It has been found that cobalt is the offending compound for development of lung disease,<sup>[8]</sup> and the ionized form of cobalt reacts readily with proteins and hence acts as a hapten leading to respiratory affection. HMLD is an occupational interstitial lung disease occurring in those exposed to dust of hard metals and presents mainly with GIP.<sup>[2,9]</sup> Liebow first classified GIP as a form of idiopathic interstitial pneumonia (IIP). Studies suggested that most cases of GIP are caused by exposure to components of hard metals.<sup>[10-12]</sup>

Subsequently in 2000, GIP was excluded from the classification of IIP proposed by the American Thoracic Society and the European Respiratory Society (ATS/ERS) and term "hard metal lung disease" (HMLD) was preferred.<sup>[13]</sup> Features of GIP are bronchiolocentric fibrosing interstitial pneumonia with bronchiolar and peribronchiolar fibrosis and increased macrophages in the airspaces associated with multinucleated giant cells. Multinucleated giant cells do not resemble either Langerhans or foreign body type cells and have distinct morphology in HMLD. Three types of pulmonary reactions to cobalt exposure are asthmatic reactions, hypersensitivity lung disease, and interstitial pulmonary fibrosis with giant cell pneumonitis.<sup>[2,14]</sup> In addition to classical GIP, HMLD has a variety of pathological patterns, desquamative interstitial pneumonia (DIP), obliterative bronchiolitis (OB), and the usual interstitial pneumonia (UIP) pattern.<sup>[4]</sup> An observational study<sup>[15]</sup> on GIP and lung fibrosis in HMLD showed microscopic findings of lung specimens in UIP pattern included mild centrilobular inflammation and multinucleated giant cells which could never be seen in the classical UIP. Thus, HMLD shows inflammation usually of the giant cell variety.

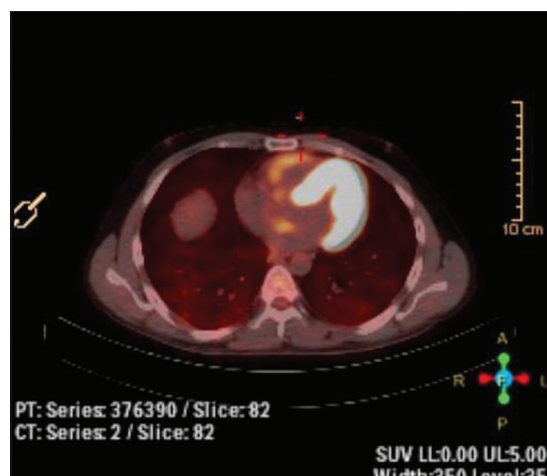An affected person has a strong occupational exposure and presents with a prolonged history of dry cough, progressive breathlessness on exertion, fatigue, weight loss. An HRCT usually shows areas of ground glass attenuation,



**Figure 1:** Digital chest radiograph (posterior anterior view) showing bilateral reticulonodular opacities



**Figure 2:** High resolution computed tomography showing ill-defined patchy areas of confluent centrilobular nodules with central and peripheral distribution pattern



**Figure 3:** PET/CT showing low-grade metabolically active lesions in bilateral lung parenchyma, and low to moderate uptake in right paratracheal, subcarinal, right tracheobronchial, bilateral hilar, bilateral inguinal lymph nodes and aortopulmonary window

centrilobular nodules, interspersed cysts with an upper lobe predilection, and occasionally may also present with honeycombing.<sup>[16,17]</sup> The histopathologic manifestations of HMLD range from bronchitis to subacute fibrosing alveolitis to interstitial fibrosis.<sup>[18]</sup> It is characterized by desquamation of epithelial cells and accumulation of macrophages and multinucleated giant cells in alveolar spaces, which develop within a few years of hard-metal exposure, whereas chronic diffuse mural fibrosis with honeycombing can occur either a few or many years after exposure. Spirometry show restrictive lung defect with reduced diffusing capacity. Diagnosis is on the basis of occupational history, HRCT findings and/or surgical biopsy.

Inflammatory pulmonary lesions may show increased uptake of FDG as it has been described in literature.<sup>[19]</sup> In ILD increased activity on PET may suggest active disease and decrease in uptake correlates with response to therapy.<sup>[20]</sup> Correlation with CT, FDG-PET scan may obviate the need for further evaluation or biopsy in more than one-third of scintigraphic equivocal lesions.<sup>[21]</sup> Increased uptake in inflammation may be explained by recruitment of activated white cells (granulocytes, lymphocytes and macrophages) which have enhanced levels of glucose transporters and increased affinity of FDG through various cytokines and growth factors. Our patient showed diffuse low grade FDG uptake in both lungs and low to moderate FDG uptake in right paratracheal, subcarinal, right tracheobronchial, bilateral hilar, bilateral inguinal lymph nodes and aortopulmonary window; correlating well with HRCT findings. Increased FDG uptake in our patient also is due to continuous inflammation evolving through the disease process progressively. Management includes cessation of exposure to the concerned occupational dust or powder, inhaled bronchodilators and inhaled corticosteroids for the airway component, and oral corticosteroids for alveolitis stage of interstitial involvement. However, once contracted, the prognosis of the disease is poor.<sup>[22]</sup> Our patient did not show improvement; however, lung function remained stable. Beneficial response to steroid therapy is mentioned in the literature. In a study by Bezerra *et al.*, treatment with immunosuppressant (azathioprine and pulses of cyclophosphamide) and prednisone showed good clinical improvement.<sup>[23]</sup>

Hard metal lung disease due to cobalt exposure pathologically shows high degree of inflammation usually of the giant cell variety. This is the basis of FDG uptake in patients exposed to cobalt dust. Occupational history plays vital role in diagnosing the condition.

## REFERENCES

- Linson D, Lauwerys R, Demedts M, Nemery B. Experimental research into the pathogenesis of cobalt/hard metal lung disease. *Eur Respir J* 1996;9:1024-8.
- Sundaram P, Agarwal K, Mandke JV, Joshi JM. Giant cell pneumonitis induced by cobalt. *Indian J Chest Dis Allied Sci* 2001;43:47-9.
- Abraham JL, Spragg RJ. Documentation of environmental exposure using open biopsy, transbronchial biopsy and bronchopulmonary lavage in giant cell interstitial pneumonia (GIP). *Am Rev Respir Dis* 1979;119:119.
- Moriyama H, Kobayashi M, Takada T, Shimizu T, Terada M, Narita J, et al. Two-dimensional analysis of elements and mononuclear cells in hard metal lung disease. *Am Respir Crit Care Med* 2007;176:70-7.
- Sprince NL, Oliver LC, Eisen EA, Greene RE, Chamberlin RI. Cobalt exposure and lung disease in tungsten carbide production. A cross-sectional study of current workers. *Am Rev Respir Dis* 1988;138:1220-6.
- Enriquez LS, Mohammed TL, Johnson GL, Lefor MJ, Beasley MB. Hard metal pneumoconiosis: A case of giant cell interstitial pneumonitis in a machinist. *Respir Care* 2007;52:196-9.
- Kelleher P, Pacheco K, Newman LS. Inorganic dust pneumonias: The metal-related parenchymal disorders. *Environ Health Perspect* 2000;108(Suppl 4):685-96.
- Coates EO Jr, Watson JH. Diffuse interstitial lung disease in tungsten carbide workers. *Ann Intern Med* 1971;75:709-16.
- Cugell DW. The hard metal diseases. *Clin Chest Med* 1992;13:269-79.
- Ohori NP, Sciurba FC, Owens GR, Hodgson MJ, Yousem SA. Giant-cell interstitial pneumonia and hard-metal pneumoconiosis. A clinicopathologic study of four cases and review of the literature. *Am J Surg Pathol* 1989;13:581-7.
- Migliori M, Mosconi G, Michetti G, Belotti L, D'Adda F, Leghissa P, et al. Hard metal disease: Eight workers with interstitial lung fibrosis due to cobalt exposure. *Sci Total Environ* 1994;150:187-96.
- Dai JH, Miao LY, Xiao YL, Meng FQ, Cai HR. Giant cell interstitial pneumonia associated with hard metals: A case report and review of the literature. *Zhonghua Jie He He Hu Xi Za Zhi* 2009;32:493-6.
- American Thoracic Society; European Respiratory Society. American Thoracic Society/European Respiratory Society International Multidisciplinary Consensus Classification of the Idiopathic Interstitial Pneumonias. This joint statement of the American Thoracic Society (ATS) and the European Respiratory Society (ERS) was adopted by the ATS board of directors, June 2001 and by the ERS Executive Committee, June 2001. *Am J Respir Crit Care Med* 2002;165:277-304.
- Cugell DW, Morgan WK, Perkins DG, Rubin A. The respiratory effects of cobalt. *Arch Intern Med* 1990;150:177-83.
- Tanaka J, Moriyama H, Terada M, Takada T, Suzuki E, Narita I, et al. An observational study of giant cell interstitial pneumonia and lung fibrosis in hard metal lung disease. *BMJ Open* 2014;4:e004407.
- Gotway MB, Golden JA, Warnock M, Koth LL, Webb R, Reddy GP, et al. Hard metal interstitial lung disease: High-resolution computed tomography appearance. *J Thorac Imaging* 2002;17:314-8.
- Dunlop P, Müller NL, Wilson J, Flint J, Chung A. Hard metal lung disease: High resolution CT and histologic correlation of the initial findings and demonstration of interval improvement. *J Thorac Imaging* 2005;20:301-4.
- Asad S, Aquino SL, Piyavisetpat N, Fischman AJ. False-positive FDG positron emission tomography uptake in nonmalignant chest abnormalities. *AJR Am J Roentgenol* 2004;182:983-9.
- Meissner HH, Soo Hoo GW, Khonsary SA, Mandelkern M, Brown CV, Santiago SM. Idiopathic pulmonary fibrosis: Evaluation with positron emission tomography. *Respiration* 2006;73:197-202.
- Basu S, Yadav M, Joshi J. Potential of 18F-FDG-PET and PET/CT in nonmalignant pulmonary disorders: Much more than currently perceived? Making the case from experience gained in the Indian scenario. *Nucl Med Commun* 2014;35:689-96.
- Metser U, Even-Sapir E. Increased (18) F-fluorodeoxyglucose uptake in benign, nonphysiologic lesions found on whole-body positron emission tomography/computed tomography (PET/CT): Accumulated data from four years of experience with PET/CT. *Semin Nucl Med* 2007;37:206-22.
- Ruediger HW. Hard metal particles and lung disease: Coincidence or causality? *Respiration* 2000;67:137-8.
- Bezerra PN, Vasconcelos AG, Cavalcante LL, Marques VB, Nogueira TN, Holanda MA. Hard metal lung disease in an oil industry worker. *J Bras Pneumol* 2009;35:1254-8.

**How to cite this article:** Iyer K, Karkhanis V, Basu S, Joshi JM. Fluoro-deoxyglucose-positron emission tomography/computed tomography in hard metal lung disease. *Lung India* 2015;32:480-2.

**Source of Support:** Nil, **Conflict of Interest:** None declared.