

Contents lists available at [ScienceDirect](https://www.sciencedirect.com)

## International Journal of Surgery Case Reports

journal homepage: [www.casereports.com](http://www.casereports.com)

# Simultaneous endovascular treatment of synchronous symptomatic acute type B aortic dissection and large infrarenal aortic aneurysm. Technical tips and case report

Ettore Dinoto<sup>a,\*</sup>, Felice Pecoraro<sup>a,b</sup>, Arduino Farina<sup>a</sup>, Alessia Viscardi<sup>c</sup>, Guido Bajardi<sup>a,b</sup>

<sup>a</sup> Vascular Surgery Unit, AOUP Policlinico 'P. Giaccone', Palermo, Italy

<sup>b</sup> Department of Surgical, Oncological and Oral Sciences, University of Palermo, Italy

<sup>c</sup> Department of Public Health, Vascular Surgery Unit, University Federico II of Naples, Naples, Italy

## ARTICLE INFO

### Article history:

Received 21 June 2020

Received in revised form 19 July 2020

Accepted 19 July 2020

Available online 11 August 2020

### Keywords:

Complicated aortic B dissection

PETICOAT

Case report

## ABSTRACT

**INTRODUCTION:** Data from the literature suggest that in patients with acute type B aortic dissection (ATBAD), associated with AAA, rupture risk is higher at the confluence tract than isolated lesions. Herein, we report a case of ATBAD and AAA managed with simultaneous intervention.

**CASE PRESENTATION:** We report a complicated case of a symptomatic patient presenting with a type B aortic dissection and false lumen extension into superior mesenteric artery (SMA) with an infrarenal abdominal aortic aneurysm (AAA). Severe back pain and hypertension were the patient's initial complaints. This patient underwent endovascular repair with a thoracic and infrarenal aortic endograft.

**DISCUSSION:** AAA rupture has been detected at admission in three-fourths of patients with ATBAD that extended to or involved a coexisting unoperated atherosclerotic aneurysms. Prompt surgical intervention is essential to deal with this dreadful aortic emergency.

**CONCLUSION:** In our experience a totally endovascular solution to treat a complicated ATBAD plus AAA was a rapid solution with low invasivity, no complication and complete healing of patients.

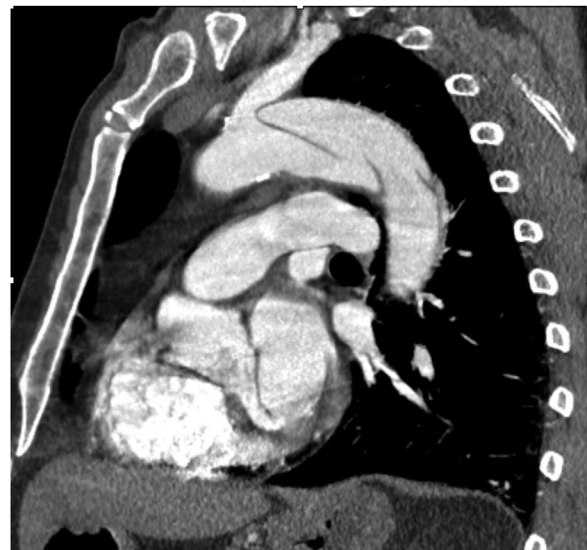© 2020 Published by Elsevier Ltd on behalf of IJS Publishing Group Ltd. This is an open access article under the CC BY-NC-ND license (<http://creativecommons.org/licenses/by-nc-nd/4.0/>).

## 1. Introduction

The association of acute type B aortic dissection (ATBAD) and abdominal aortic aneurysm (AAA) is infrequent with a reported incidence of 5.5–7% in large volume aortic centers [1]. An higher rupture risk is reported at the confluence between ATBAD and AAA lesions. When these lesions occur synchronously in different aortic segments the natural history appears to conform the expected course of each lesion considered individually [2]. In case of indication to treatment, there are no clear evidence regarding the timing of simultaneous or delayed intervention. Herein, we report a case of ATBAD and AAA managed with simultaneous intervention. This work has been written in accordance with the SCARE criteria [3].

## 2. Case presentation

A 65-year-old male with hypertension and diabetes mellitus complained of sudden thoraco-abdominal pain. At history he referred to be in treatment with antiplatelet and anti-hypertensive drugs. Patient denied any previous family history of similar pathology. CT-scan showed an ATBAD, from left subclavian artery (LSA) to



**Fig. 1.** Preoperative CT-angiography showing proximal dissection from left subclavian artery.

\* Corresponding author at: Vascular Surgery Unit, AOUP Policlinico 'P. Giaccone', Via Liborio Giuffrè, 5, Palermo, Italy.

E-mail address: [ettore.dinoto@policlinico.pa.it](mailto:ettore.dinoto@policlinico.pa.it) (E. Dinoto).

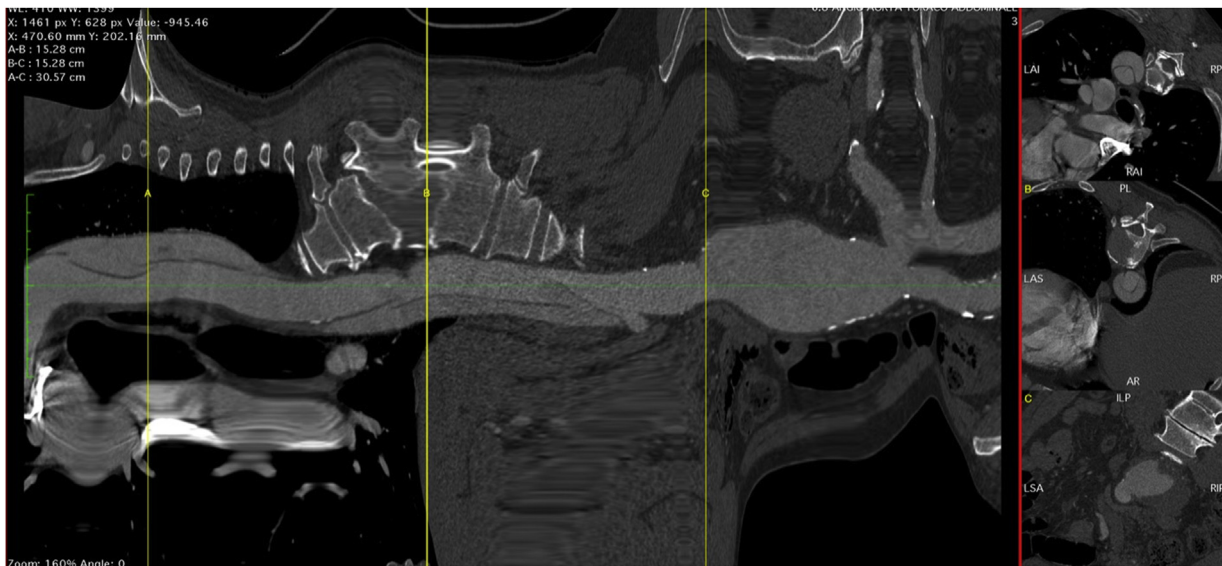


Fig. 2. Preoperative centerline showing dissection and abdominal aneurysm.

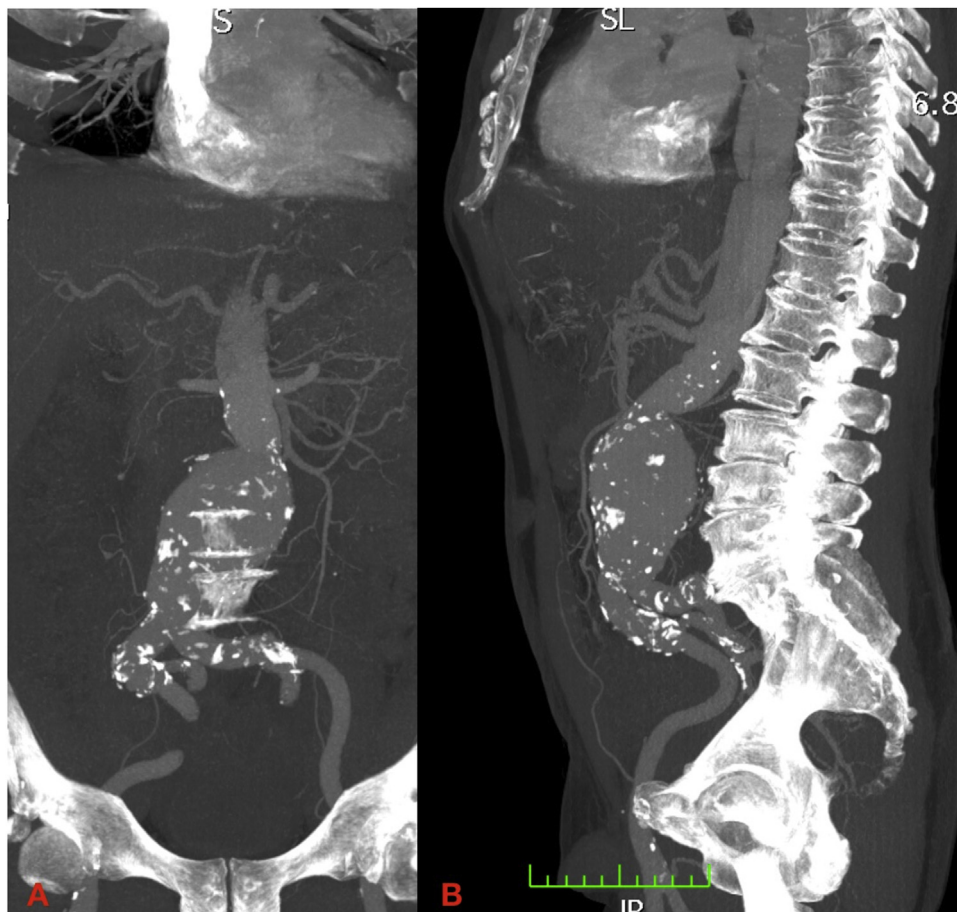


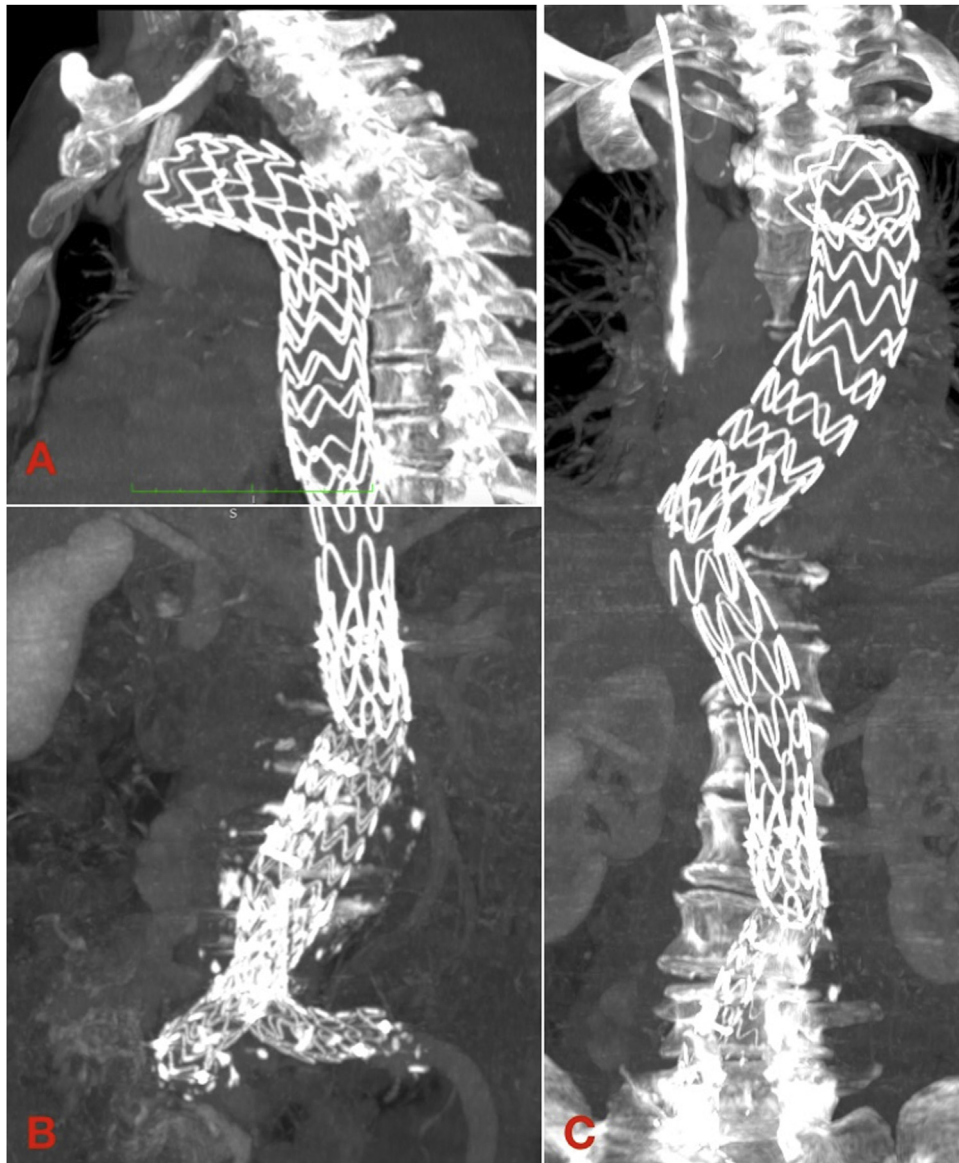
Fig. 3. Preoperative CT-angiography showing abdominal aneurysm in the coronal plane (A) and sagittal plane (B).

the superior mesenteric artery (SMA), and a 72 mm large infrarenal AAA. CT-angiography showed a significant true lumen compression from an expanding false lumen (Figs. 1–3). No malperfusions symptoms or signs were evident. Uncontrollable systemic hypertension and pain (thoracic and abdominal) were the indications to treatment. To reduce the invasiveness of the procedures and

address simultaneously both ATBAD and AAA a totally endovascular approach was chosen.

Intervention was conducted without placement of spinal drain.

In our vascular operating room, under general anesthesia and systemic heparinization (ACT > 250 s), a bilateral surgical common femoral artery (CFA) and a bilateral percutaneous brachial artery



**Fig. 4.** Postoperative CT MPR showing Thoracic graft (A), abdominal graft (B) and final structure of prosthetic implant (C).

(BA) accesses were gained. A through and through wire from the right CFA to the right BA (bodyfloss technique) [4] was constructed in consideration of the arch anatomy and to create a stable platform for the thoracic stent-graft advancement and deployment by applying adequate tension to the bodyfloss wire.

An adequate proximal landing zone was identified in zone 2 Hishimaru aortic arch. To maintain LSA perfusion a chimney was planned. From the left BA access a 10 × 31 mm Silene covered stent (InSitu Technologies Inc, St. Paul, MN, USA) was advanced and parked at the origin of the LSA so that half of the length was positioned inside the aortic arch and the remaining into the LSA. A 40 × 223 mm Valiant Navion (Medtronic, Inc., Minneapolis, MN, USA) was placed and deployed in zone 2 aortic arch through the bodyfloss wire. At this stage, the Silene covered stent (InSitu Technologies Inc) was deployed. A kissing ballooning of both the Valiant Navion (Medtronic, Inc.) thoracic stent-graft and the LSA chimney was performed. Sizing of the thoracic and LSA devices were performed according to the current understandings [4]. The control angiography confirmed the adequate proximal sealing, the absence of leakages and the maintained LAS patency.

The second step consisted of endovascular aneurysm repair (EVAR) carried with a 32 mm bifurcated ENDURANT II (Medtronic, Inc.) stent-graft from the infrarenal aorta to both common iliacs carried with the use of the speed cannulation gate technique [5]. The control angiography confirmed the adequate proximal and distal sealing, the absence of leakages and the maintained internal iliacs patency.

The third step was performed with the placement of a 36 × 180 mm Zenith endovascular dissection stent (Cook Medical, Bloomington, IN, USA) between the thoracic and the abdominal stent-graft. This bare metal stent is intended to supports the collapsed true lumen without covering the reno-visceral branches as reported in the PETTICOAT (provisional extension to induce complete attachment) technique (Fig. 4). The final angiographic control confirmed the above mentioned partial findings and the maintained patency of reno-visceral arteries and a reduced refueling of the false lumen.

After procedure the patient was transferred in the intensive care unit (ICU) for monitoring of vital functions where the extubation was carried after 12 h with no complications or signs of spinal cord ischemia (SCI). On the second postoperative day the

patient was transferred from ICU and discharged at home after seven days.

The one year CT angiography showed good placement of thoracic and abdominal graft with good remodeling of false lumen in absence of symptoms and complete exclusion of AAA.

### 3. Discussion

A simultaneous AAA in cases presenting ATBAD is reported in the Literature with a prevalence of 1–7% in patient treated for aortic disease [1]. In this circumstance, the AAA etiology is still a not fully understood: it can be associated to a pre-existing asymptomatic degenerative atherosclerotic lesion, or it can be the result of the rapid expansion determined by the dissecting flap [6,7]. This close correlation further is demonstrated [8], also by evidences in some cases of dissection in patient previously treated for AAA [9]. AAA rupture has been detected at admission in three-fourths of patients with ATBAD that extended to or involved a coexisting unoperated atherosclerotic aneurysms. This association, increasing the risk of thoracic or aortic rupture, indicate such combination of aortic lesions as “complicated” dissection [2]. Thus, a coexisting aortic lesions must be considered for treatment as quickly as possible. The reported simultaneous approach can be performed endovascularly also when supra-aortic branches are involved with the combination of proper devices [10]. Molinari et al. suggested an extensive endovascular treatment with TEVAR to close the primary entry tear and exclusion of all distal reentries by an abdominal bifurcated endograft to avoid the risk of rupture or collapse of true lumen in patient with dissection type B involving carrefour and iliac artery [11]. Patel et al. described a case of complex TBAD associated to a pressurized infrarenal AAA treated with a TEVAR and EVAR in a single stage [5]. Moreover EVAR has been associated to acceptable outcomes even when employed outside the instruction for use [12,13]. Despite a known increased risk after emergent AAA surgical repair [14] and the indication to full heparinization during TEVAR and chimneys [15], in a reported literature review simultaneous interventions with TEVAR showed also good outcomes [6].

### 4. Conclusions

In literature studies reporting simultaneous treatment of ATBAD and AAA are lacking. This experience using a totally endovascular solution to address both diseases even with the involvement of supra-aortic branches and the reno-visceral aortic segment was feasible. This solution represents a rapid and less invasive approach to address high complex disease and allowed fast discharge and limited ICU stay.

#### Declaration of Competing Interest

None.

#### Funding

None.

#### Ethical approval

None.

#### Consent

Written informed consent was obtained from the patient for publication of this case report and accompanying images. A copy

of the written consent is available for review by the Editor-in-Chief of this journal on request.

#### Author contribution

Ettore Dinoto: study concept, design, data collection, data analysis, interpretation, writing the paper, final approval of the version to be submitted, guarantor.

Felice Pecoraro: study concept, design, data collection, data analysis, interpretation, writing the paper, final approval of the version to be submitted.

Arduino Farina: study concept, design, data collection, data analysis, interpretation, final approval of the version to be submitted.

Alessia Viscardi: study concept, design, data collection, final approval of the version to be submitted.

Guido Bajardi: study concept, design, data collection, data analysis, interpretation, final approval of the version to be submitted.

#### Registration of research studies

Not Applicable.

#### Guarantor

ETTORE DINOTO.

#### Acknowledgements

This article is part of a supplement entitled Case reports from Italian young surgeons, published with support from the Department of Surgical, Oncological and Oral Sciences - University of Palermo.

#### References

- [1] R. Bellosta, G. Gelpi, C. Lomazzi, C. Romagnoni, P. Castelli, S. Trimarchi, et al., Surgical treatment of synchronous type B acute aortic dissection and abdominal aortic aneurysm, *Ann. Vasc. Surg.* 49 (May) (2018) 107–114.
- [2] R.P. Cambria, D.C. Brewster, A.C. Moncure, F.L. Steinberg, W.M. Abbott, Spontaneous aortic dissection in the presence of coexistent or previously repaired atherosclerotic aortic aneurysm, *Ann. Surg.* 208 (November (5)) (1988) 619–624.
- [3] R.A. Agha, A.J. Fowler, A. Saeta, I. Barai, S. Rajmohan, D.P. Orgill, SCARE Group, The SCARE statement: consensus-based surgical case report guidelines, *Int. J. Surg.* 34 (October) (2016) 180–186.
- [4] C.P. van der Zee, M.J. van der Laan, E. Dinoto, I. Tielliu, C.J. Zeebregts, T. Vainas, A different angle in through-and-through body wires in difficult aortic arch stent-graft placement, *J. Cardiovasc. Surg. (Torino)* 60 (February (1)) (2019) 144–146.
- [5] D. Pakeliani, M. Lachat, L. Blohmé, M. Kobayashi, L. Chaykovska, T. Pfammatter, et al., Improved technique for sheath supported contralateral limb gate cannulation in endovascular abdominal aortic aneurysm repair, *VASA Z. Gefasskrankheiten* 49 (January (1)) (2020) 39–42.
- [6] M.S. Patel, H.T. Hassoun, M.G. Davies, A.B. Lumsden, Single-stage repair of a complex type B aortic dissection associated with a pressurized infrarenal abdominal aortic aneurysm, *Ann. Vasc. Surg.* 27 (November (8)) (2013), 1182.e9–12.
- [7] C.S. Roberts, W.C. Roberts, Combined thoracic aortic dissection and abdominal aortic fusiform aneurysm, *Ann. Thorac. Surg.* 52 (September (3)) (1991) 537–540.
- [8] F. Pecoraro, Z. Rancic, D. Mayer, T. Pfammatter, M. Lachat, Acute aortic dissection: a case report showing penetrating thoracic aortic ulcer and infrarenal aortic rupture, *J. Cardiovasc. Med. Hagerstown Md.* 12 (September (9)) (2011) 655–656.
- [9] D. Shikata, A. Omura, J. Matsuo, H. Matsuda, Thoracic endovascular aortic repair for acute type B aortic dissection complicated by total occlusion of the abdominal aorta, *Interact. Cardiovasc. Thorac. Surg.* (February (24)) (2020).
- [10] S.T. Scali, A.W. Beck, G. Torsello, M. Lachat, P. Kubilis, F.J. Veith, et al., Identification of optimal device combinations for the chimney endovascular aneurysm repair technique within the PERICLES registry, *J. Vasc. Surg.* 68 (1) (2018) 24–35.
- [11] A.C. Molinari, E. Leo, M. Ferraresi, S.A. Ferrari, A. Terzi, S. Sommaruga, et al., Distal extended endovascular aortic repair PETTICOAT: a modified technique to improve false lumen remodeling in acute type B aortic dissection, *Ann. Vasc. Surg.* 59 (August) (2019) 300–305.

- [12] Z. Rancic, F. Pecoraro, T. Pfammatter, I. Banzic, H. Klein, K. Kyriakidis, et al., The use of Endurant stent-graft for abdominal aortic aneurysm: the story about extension of instruction for use with persistent good results of stent-graft latest generation, *J. Cardiovasc. Surg. (Torino)* 53 (October (5)) (2012) 579–594.
- [13] F. Pecoraro, G. Corte, E. Dinoto, G. Badalamenti, S. Bruno, G. Bajardi, Cincal outcomes of Endurant II stent-graft for infrarenal aortic aneurysm repair: comparison of on-label versus off-label use, *Diagn. Interv. Radiol. Ank. Turk.* 22 (October (5)) (2016) 450–454.
- [14] F. Pecoraro, S. Gloekler, C.E. Mader, M. Roos, L. Chaykovska, F.J. Veith, et al., Mortality rates and risk factors for emergent open repair of abdominal aortic aneurysms in the endovascular era, *Updates Surg.* 70 (March (1)) (2018) 129–136.
- [15] M.J. Bosiers, K. Tran, J.T. Lee, K.P. Donas, F.J. Veith, G. Torsello, et al., Incidence and prognostic factors related to major adverse cerebrovascular events in patients with complex aortic diseases treated by the chimney technique, *J. Vasc. Surg.* 67 (5) (2018) 1372–1379.

#### Open Access

This article is published Open Access at [sciencedirect.com](https://www.sciencedirect.com). It is distributed under the [IJSCR Supplemental terms and conditions](#), which permits unrestricted non commercial use, distribution, and reproduction in any medium, provided the original authors and source are credited.