

Optic Nerve Head Drusen Masquerading as Papilledema: A Diagnostic Dilemma

Vipin Rana, Atul Arora, Krinjeela Bazgain, Deeksha Sharma

Advanced Eye Centre, Post Graduate Institute of Medical Education and Research (PGIMER), Chandigarh, India

CLINICAL DESCRIPTION

A 16-year-old boy with complaints of global headache for 1 month presented to our tertiary care center for ophthalmic examination. He was elsewhere diagnosed with idiopathic intracranial hypertension (IIH) and was started on Tab Acetazolamide 250 mg O.D. On ocular examination, his uncorrected visual acuity was 20/20 in both the eyes with normal intraocular pressure and pupillary reactions. The optic discs were mildly raised with blurred margins. However, no optic disc hyperemia was seen [Figure 1 a and b]. Ultrasound B scan showed hyperechogenicity of high amplitude over the optic disc in both the eyes [Figure 1 e and f]. Also, fundus autofluorescence (FAF) revealed hyper autofluorescence over the disc in both the eyes [Figure 1 c and d]. Patient was diagnosed to have optic nerve head drusen (ONHD) in both eyes.

DISCUSSION

Originally described by Müller,^[1] optic nerve head drusen (ONHD) are acellular deposits of calcium, nucleic acids, amino acids, and mucopolysaccharides.^[2,3] These are of two types, that is, superficial and deep, and both are common in the nasal part of the disc and represent the same pathology.^[4] Approximately 60% of optic discs with drusen have superficial ONHD on clinical examination which are easily visible as they are lumpy bumpy, refractile, rounded, pale, and vary in size from small foci to large lobulated clusters.^[4,5] Buried ONHD (common in young patients) have a variable appearance, ranging from a near-normal optic disc to an elevated swollen appearance; thus can be difficult to differentiate clinically from optic disc edema. Buried ONHD are more common in young patients. As a consequence, they are more vulnerable to misdiagnosis, such as papilledema.^[6] In addition to blurred optic disc margins and the elevated optic disc, papilledema will have associated optic disc hyperemia with obscuration of the retinal vasculature at the disc margin, and associated hemorrhages and cotton wool spots may also be present which are usually not seen in ONHD.^[7] Different imaging modalities help to differentiate ONHD from true disc edema like ultrasonography (USG B scan), fundus autofluorescence (FAF), and computed tomography (CT). They appear as hyperechoic, highly reflective round structures with posterior acoustic shadowing on USG B scan.^[8] On FAF, ONHD appear as oval or round hyper autofluorescent structures with irregular edges.^[8] There is no definitive treatment for ONHD. Thus, ophthalmologists should conduct

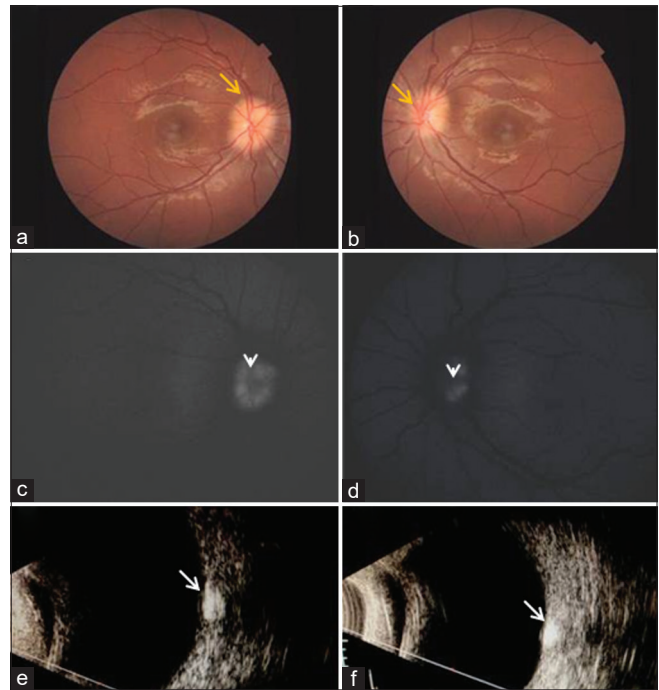


Figure 1: a-b: Fundus photo shows blurred optic disc margins in right and left eye respectively (yellow arrows). c-d: Fundus autofluorescence shows hyper autofluorescence at both optic discs (white arrowheads). e-f: Ultrasound B scan shows hyper-echogenicity at both optic discs. (white arrows)

regular check-ups to rule out accompanying disorders like non-arteritic anterior ischemic optic neuropathy, subretinal neovascularization, and elevated intraocular pressure.^[6]

Clinically, presentation with blurred disc margins and elevated disc may masquerade as papilledema as in our case. Thus, such patients, if not having associated retinal findings like disc hyperemia, cotton wool spots, hemorrhages, and absence of neurological signs, should undergo multimodal imaging like fundus autofluorescence and USG B scan to clinch the diagnosis of ONHD. Therefore, early diagnosis of ONHD prevents unnecessary investigations and spares the patient from the anxiety of intracranial pathology.

Declaration of patient consent

The authors certify that they have obtained all appropriate patient consent forms. In the form the patient(s) has/have given his/her/their consent for his/her/their images and other clinical information to be reported in the journal. The patients understand that their names and initials will not be published

and due efforts will be made to conceal their identity, but anonymity cannot be guaranteed.

Financial support and sponsorship

Nil.

Conflicts of interest

There are no conflicts of interest.

REFERENCES

1. Müller H. Beitrage zur Ophthalmologie. Albrecht Von Graefes Arch Klin Ophthalmol 1858;4:1-40.
2. Friedman AH, Beckerman B, Gold DH, Walsh JB, Gartner S. Drusen of the optic disc. Surv Ophthalmol 1977;21:375-90.
3. Tso MO. Pathology and pathogenesis of drusen of the optic nerve head. Ophthalmology 1981;88:1066-80.
4. Lam BL, Morais CG Jr., Pasol J. Drusen of the optic disc. Curr Neurol Neurosci Rep 2008;8:404-8.
5. Traber GL, Weber KP, Sabah M, Keane PA, Plant GT. Enhanced depth imaging optical coherence tomography of optic nerve head drusen: A comparison of cases with and without visual field loss. Ophthalmology 2017;124:66-73.
6. Auw-Haedrich C, Staubach F, Witschel H. Optic disk drusen. Surv Ophthalmol 2002;47:515-32.
7. Frisen L. Swelling of the optic nerve head: A staging scheme. J Neurol Neurosurg Psychiatry 1982;45:13-8.
8. Hamann S, Malmqvist L, Costello F. Optic disc drusen: Understanding an old problem from a new perspective. Acta Ophthalmol 2018;96:673-84.

Address for correspondence: Dr. Atul Arora,
Advanced Eye Centre, Postgraduate Institute of Medical Education and
Research (PGIMER), Chandigarh - 160 012, India.
E-mail: atul1691@gmail.com

Submitted: 13-Jun-2020 **Revised:** 13-Jun-2020 **Accepted:** 14-Jun-2020

Published: 24-Jul-2020

This is an open access journal, and articles are distributed under the terms of the Creative Commons Attribution-NonCommercial-ShareAlike 4.0 License, which allows others to remix, tweak, and build upon the work non-commercially, as long as appropriate credit is given and the new creations are licensed under the identical terms.

For reprints contact: reprints@medknow.com

DOI: 10.4103/aian.AIAN_606_20