

[CASE REPORT]

Severe Adult-onset Still Disease with Constrictive Pericarditis and Pleuritis That Was Successfully Treated with Tocilizumab in Addition to Corticosteroids and Cyclosporin A

Hoshimi Kawaguchi, Hiroto Tsuboi, Mizuki Yagishita, Toshihiko Terasaki, Mayu Terasaki, Masaru Shimizu, Fumika Honda, Ayako Ohyama, Hiroyuki Takahashi, Haruka Miki, Masahiro Yokosawa, Hiromitsu Asashima, Shinya Hagiwara, Yuya Kondo, Isao Matsumoto and Takayuki Sumida

Abstract:

Adult-onset Still disease (AOSD) is a systemic inflammatory disease characterized by fever, arthritis and rash. Corticosteroids represent a promising therapeutic option for AOSD; however, some resistant cases require immunosuppressants and biologic agents. We herein report the case of a 29-year-old Japanese man with severe AOSD, accompanied by constrictive pericarditis (CP) and pleuritis. Although 2 courses of steroid pulse and subsequent high-dose of prednisolone and cyclosporine A improved the patient's CP and pleuritis, his fever and inflammatory responses persisted. Tocilizumab (TCZ) was added to his treatment, which resulted in a rapid remission. This case suggests the usefulness of TCZ in the treatment of severe AOSD with CP and pleuritis.

Key words: adult-onset Still disease, constrictive pericarditis, pleuritis, tocilizumab

(Intern Med 57: 1033-1038, 2018)

(DOI: 10.2169/internalmedicine.9809-17)

Introduction

Adult-onset Still disease (AOSD) is a systemic inflammatory disease characterized by spiking fever, arthritis, typical salmon-colored rash, and hepatosplenomegaly. It is sometimes accompanied by life-threatening complications, such as serositis, myocarditis, reactive hemophagocytic syndrome (RHS), and disseminated intravascular coagulopathy (DIC) (1, 2). A diagnosis of AOSD is usually based on Yamaguchi's criteria (3). However, there are no specific laboratory or imaging findings to aid in an accurate diagnosis of AOSD. It is therefore necessary to exclude other diseases, including infections, malignancies, and other rheumatic diseases (3).

Although the pathogenesis of AOSD remains unclear, several factors have been reported to be involved in the etiology of AOSD; these include genetic factors, viral and bacte-

rial infections, and immune system disorders (1, 2, 4, 5). Several cytokines, such as interleukins [interleukin (IL)-1, IL-6, and IL-18], tumor necrosis factor (TNF) α , and interferon (IFN) γ play important roles in the pathogenesis of AOSD (1, 2, 6, 7). Thus, treatments with biological agents that target these cytokines have become attractive therapeutic options in recent years.

Corticosteroids are generally considered as the first-line treatment for AOSD. It is reported that corticosteroids are effective in approximately 60% of systemic AOSD cases (8). In cases in which the disease follows a steroid-resistant or steroid-dependent course, disease-modifying antirheumatic drugs (DMARDs) or immunosuppressive agents, such as methotrexate (MTX) or cyclosporine A (CyA), are therapeutic options (8-10). As mentioned above, biological agents that target specific cytokine activity are promising new therapeutics for AOSD. They have been reported to have a dramatic effect and can be used to treat patients with resis-

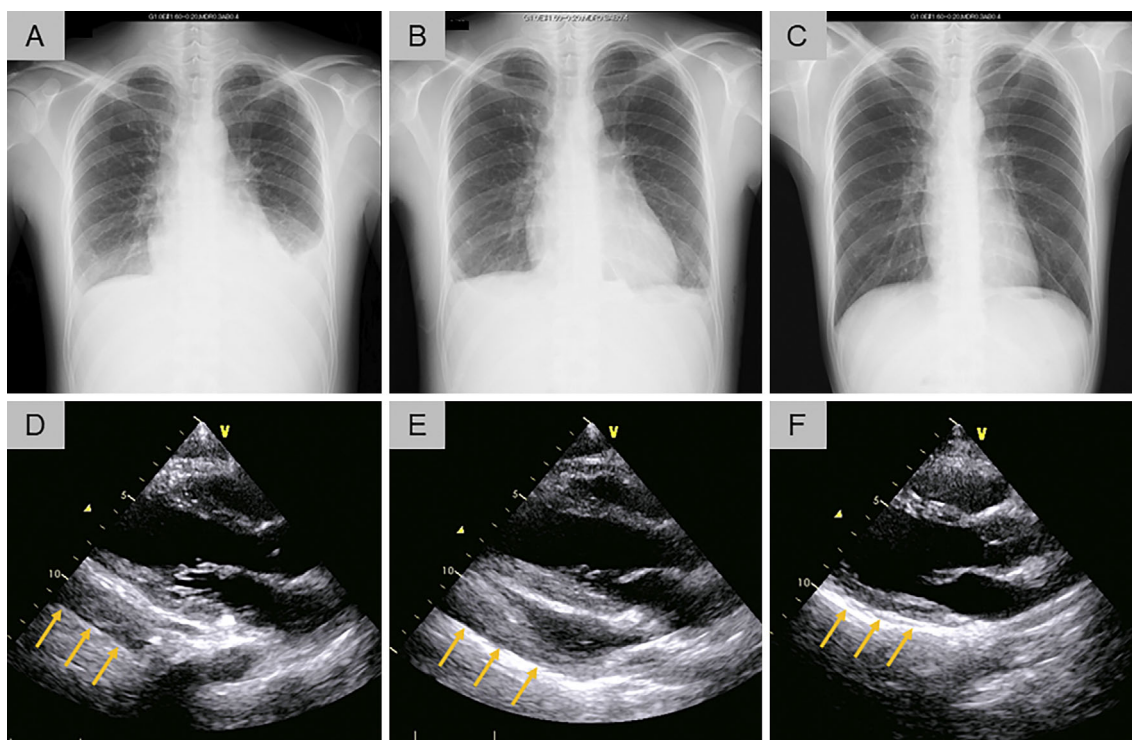


Figure 1. Chest X-rays and cardiac ultrasonography. (A) and (D) (On admission). Chest X-rays showed an enlarged cardiac silhouette and marked bilateral pleural effusion (A), and cardiac ultrasonography showed mild pericardial effusion (indicated by arrows) (D). (B) and (E) (after the first steroid pulse and before the addition of cyclosporine A). A chest X-ray showed the further enlargement of the cardiac silhouette and a decrease of bilateral pleural effusion in comparison to the chest X-ray that was obtained on admission (B). Cardiac ultrasonography showed an increase in pericardial effusion and mild thickening, and the epicardium showed high intensity (indicated by arrows), corresponding to constrictive pericarditis (CP) (E). (C) and (F) After the second injection of tocilizumab (TCZ). Chest X-rays (C) and cardiac ultrasonography (F) showed the improvement of the pleural and pericardial effusion (indicated by arrows).

tant AOSD who do not respond to conventional therapies with corticosteroids, DMARDs, and immunosuppressants (8, 10, 11). The treatment guidelines and recommendations for AOSD have not yet been established; thus, treatment strategies, such as the initial dose of corticosteroids, combination with DMARDs or immunosuppressants, and additional biologics, are decided by the clinician according to the disease course and severity in a case-by-case manner.

We herein report a case of severe and intractable AOSD, accompanied by constrictive pericarditis (CP) and pleuritis, for which a combination therapy that included tocilizumab (TCZ) (a humanized anti-IL-6 receptor antibody), corticosteroids and CyA, proved very effective in the management of the patient's disease.

Case Report

A 29-year-old Japanese man was transferred to our hospital with pleuritis and pericarditis. He had a 1-month history of fever and sore throat followed by the development of serositis prior to admission. Upon admission, he had a spiking fever of 40°C, chest pain, and dyspnea. Chest X-ray, com-

puted tomography (CT), and cardiac ultrasonography revealed bilateral pleural and pericardial effusion (Fig. 1A, D). He was initially treated with several broad-spectrum antibiotics, without effect. On the fourth day after admission, he developed arthritis of the wrists and erythema in the trunk and upper extremities (Fig. 2A, B). Laboratory tests showed an elevated white blood cell (WBC) count (28,500/uL) with 91% neutrophils, C-reactive protein (CRP) (42.7 mg/dL), liver aminotransferases (AST 55 U/L; ALT 47 U/L), and ferritin (45,180 ng/mL). The patient was negative for antinuclear antibody (ANA), anti-DNA antibody, myeloperoxidase (MPO)-anti-neutrophil cytoplasmic antibody (ANCA), proteinase 3 (PR3)-ANCA, and rheumatoid factor (RF). The patient was negative for β -D glucan, a tuberculosis-specific interferon-gamma release assay (IGRA) was negative, and blood cultures for bacteria were all negative. Serum antiviral antibodies for Epstein-Barr virus (EBV), varicella-zoster virus, herpes simplex virus (HSV), and human parvovirus B19 were all either negative or showed a past infection pattern. A cytomegalovirus antigenemia assay was also negative. The analysis of the patient's pleural effusion showed exudative properties without malignant cells, and pleural effusion cul-

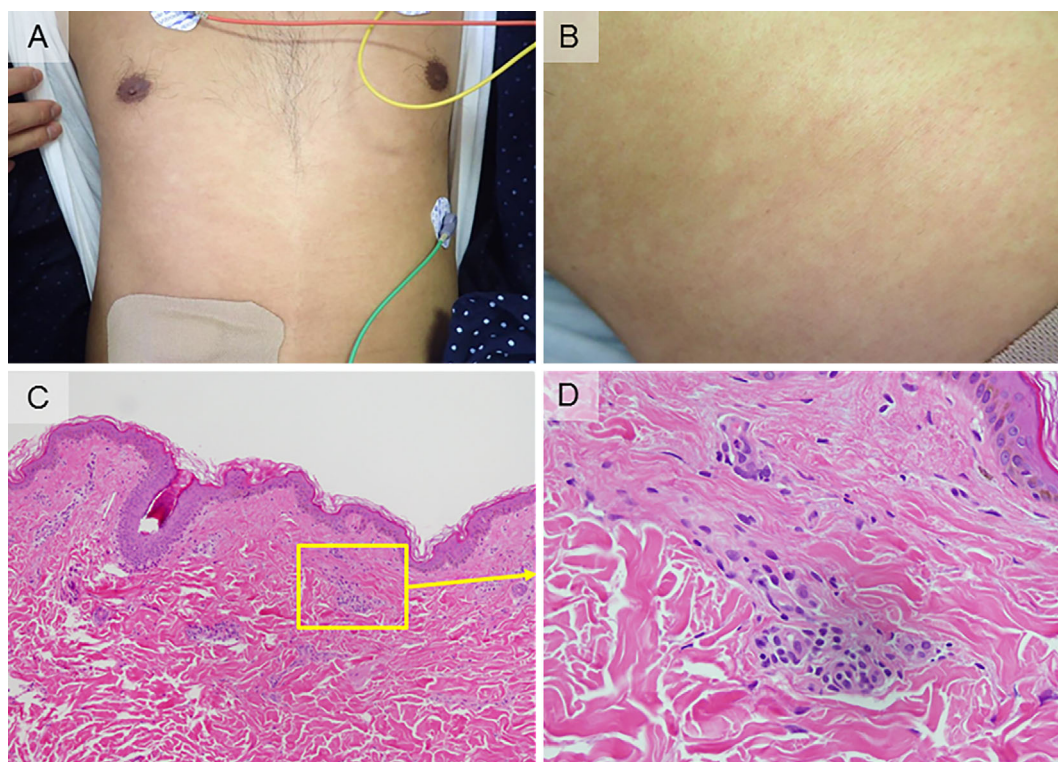


Figure 2. Skin rash of the trunk and its pathological findings. (A) Erythema was distributed on his trunk and upper extremities at 4 days after admission (before the first steroid pulse). (B) An enlarged view of the erythema on the right side of the abdomen. (C) A skin biopsy of the right abdominal region revealed perivascular dermatitis. Mild lymphocytic infiltration around the vessels was detected in the dermal layer (indicated by boxed area), and there were no malignant cells [Hematoxylin and Eosin (H&E) staining, 100× magnification]. (D) An enlarged view of the boxed area in (C) (H&E staining, 400× magnification).

tures for bacteria and mycobacteria were all negative. A random skin biopsy, which was performed to rule out the presence of malignant lymphoma, revealed mild and benign lymphocytic infiltration around the vessels in the dermal layer (Fig. 2C, D).

He was diagnosed with severe AOSD accompanied by pleuritis and pericarditis, according to Yamaguchi's criteria (3); namely, the patient exhibited fever, arthritis, rash, leukocytosis with neutrophilia, sore throat, liver dysfunction, and was negative for ANA and RF, without any evidence of infection, malignancy, or other connective tissue disease. Methylprednisolone (mPSL) pulse therapy (1,000 mg/day, intravenously) was administered for 3 days, and subsequently prednisolone [PSL; 60 mg/day (1 mg/kg/day), orally] was administered as induction therapy. Although his symptoms showed an initial trend towards improvement in response to this treatment, within a week the fever, rash, and chest pain worsened. Furthermore, a chest X-ray film showed the deterioration of cardiac enlargement (Fig. 1B), and cardiac ultrasonography revealed an increase in pericardial effusion, mild thickening and high brightness of the epicardium, diastolic failure of the lateral wall of the left ventricle and dilatation of the inferior vena cava (IVC), which corresponded to constrictive pericarditis (CP) (Fig. 1E). The administration of cyclosporine A (CyA; 100

mg/day, intravenously) was added to the treatment regimen; however, the patient's fever (38°C) and high CRP level (11.7 mg/dL) persisted, and his ferritin level increased further (35,330 ng/mL). Thus, a second mPSL pulse was administered for 3 days followed by the administration of PSL (60 mg/day, orally). The CyA dose was increased to 150 mg/day while monitoring the blood concentration (target trough concentration: 150 ng/mL). The CP and pleuritis gradually improved; nevertheless, the fever and high levels of CRP and ferritin persisted (Fig. 3).

The patient's condition was therefore assessed as being corticosteroid- and CyA-resistant AOSD with a high activity level. Based on the high level of serum IL-6 (56.8 pg/mL) and the extremely elevated level of serum IL-18 (84,000 pg/mL) - the normal ranges of which are <2.41 pg/mL and <211 pg/mL, respectively (Fig. 3) - TCZ (400 mg, 8 mg/kg, intravenously, every 2 weeks) was added to his treatment, after gaining the patient's written informed consent and approval from the local ethics committee. We considered the need for a higher dosage of TCZ based on his high disease activity, and determined that the initial dosage of TCZ should be (8 mg/kg) every 2 weeks, in accordance with the regimen for Castleman's disease [not for rheumatoid arthritis (RA)].

His general condition and fever improved immediately af-

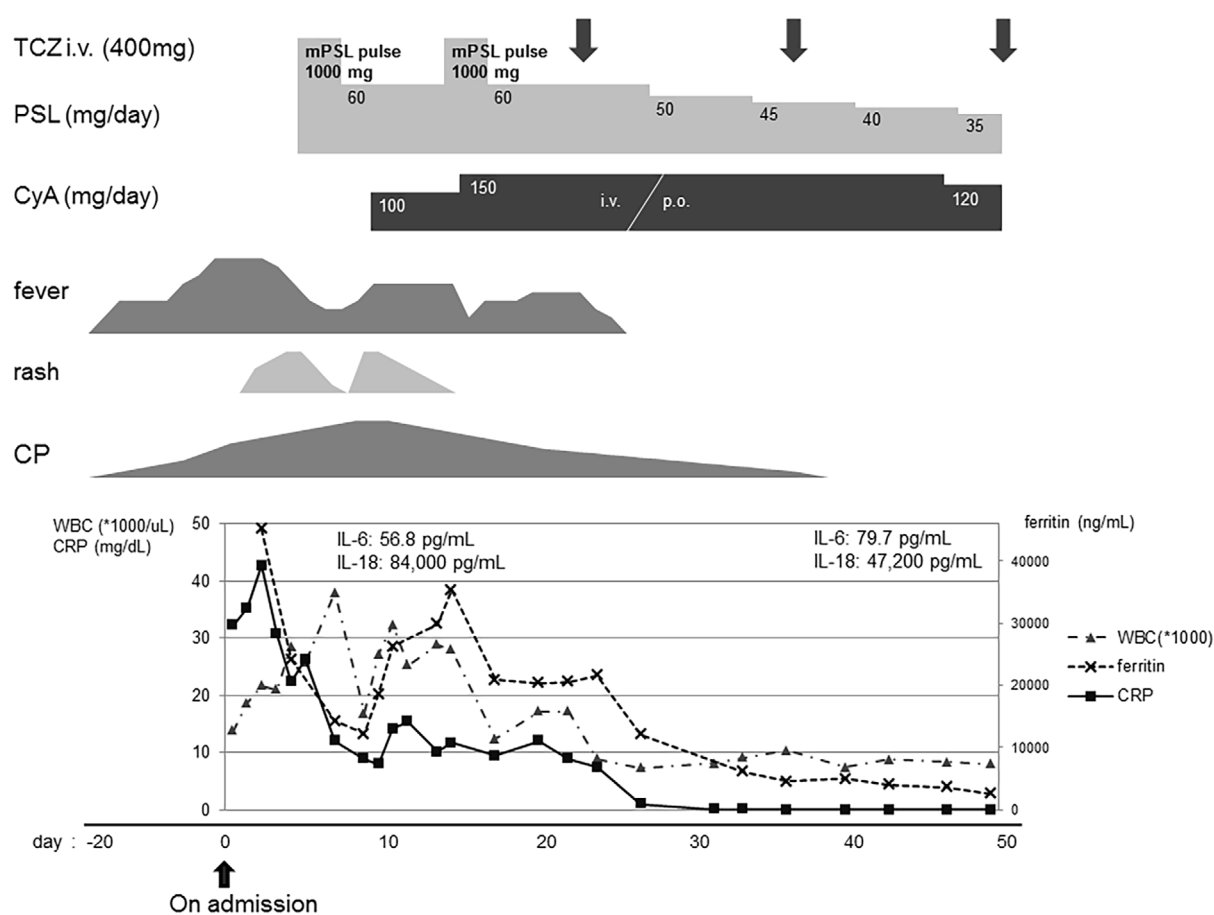


Figure 3. The clinical course. Downward arrows indicate the administration of TCZ. TCZ: tocilizumab, PSL: prednisolone, mPSL: methylprednisolone, CyA: cyclosporine A, i.v.: intravenous, p.o.: per os, CP: constrictive pericarditis, WBC: white blood cell, CRP: C-reactive protein

ter the administration of TCZ. The levels of inflammation markers, including WBC and CRP, were decreased and completely normalized within several weeks, and the ferritin level was decreased. TCZ was administered 3 times every 2 weeks, and the PSL was gradually tapered without any recurrence of the patient's clinical symptoms, inflammatory responses, CP, or pleuritis (Fig. 1C, F). He did develop mild oral candidiasis, which was treated with topical antifungal agents, but he did not experience any other adverse events. After the administration of TCZ 3 times every 2 weeks, we intended to reduce the administration of TCZ to once every 4 weeks, as maintenance therapy, and to continue treating the patient as an outpatient. TCZ combined with corticosteroids and CyA led to continuous remission. Importantly, the patient's serum IL-6 level showed a slight increase from 56.8 pg/mL to 79.7 pg/mL, and his IL-18 level dramatically decreased from 84,000 pg/mL to 47,200 pg/mL after the 2nd injection of TCZ (Fig. 3).

Discussion

We encountered a case of severe and intractable AOSD accompanied with CP and pleuritis that was resistant to treatment with high-dose corticosteroid and CyA. Remission

was ultimately induced by combination therapy with TCZ—a humanized anti-IL-6 receptor antibody. Through our experience of this case, we can make 3 clinically important observations.

Firstly, our patient presented with CP accompanied by marked pericardial effusion and thickening of the pericardium, which is a very rare complication of AOSD. According to previous reports, although pericarditis is observed in 20–40% of patients with AOSD (12, 13), to the best of our knowledge, there has only been 1 previous case report on AOSD with CP (14). Importantly, the report describes CP as being the patient's first clinical manifestation (14). In our case, pericarditis and pleuritis preceded arthritis and rash, which are typical manifestations of AOSD. The pericarditis deteriorated after the first mPSL pulse treatment, but resulted in CP with a thickening of the epicardium and diastolic failure of the left ventricle. In both the previous report and our case, the patients showed pericardial manifestations at the early stage of the disease. CP is very rare in AOSD, but can sometimes be the initial manifestation of AOSD, and requires an early diagnosis and immediate therapeutic intervention due to its potentially life-threatening complications. Thus, it might be necessary to consider AOSD as one of the possible differential diagnoses of CP. Additionally, in a pre-

vious report, the presence of pericarditis at the onset of AOSD was a predictive factor that was used to indicate biological treatment (15). In another report, biological treatment was more often required in cases involving AOSD with pleuritis (16). Taken together, the findings of these reports suggest that the presence of serositis in AOSD is associated with a disease course that is more resistant to conventional therapy with corticosteroids and immunosuppressive agents. Actually, in our case, the additional administration of TCZ was required for the management of the patient's continuous fever and inflammatory responses, while the serositis itself responded well to treatment with corticosteroids and CyA.

The second clinically important observation is that the addition of TCZ had a dramatic effect in our case of intractable AOSD. It is reported that a high level of IL-6 is responsible for some of the clinical features of AOSD, such as fever and the elevation of CRP and ferritin (1, 11, 17), and that it is correlated with disease activity (6, 18). IL-6 is considered to be a suitable target in the treatment of refractory AOSD. Actually, several case studies have reported that TCZ has beneficial effects and its high level of safety in the treatment of refractory or intractable AOSD (17, 19-21). In these reports, TCZ rapidly improved the disease status and maintained remission in patients with refractory or intractable AOSD who were not responsive to corticosteroids and DMARDs. Furthermore, the effect of TCZ persisted for more than 6 months after its discontinuation. TCZ was also reported to have a marked corticosteroid-sparing effect and a good safety and tolerance profile. In our case, the patient's CP and pleuritis gradually improved after corticosteroid and CyA treatment, nevertheless, the fever and high levels of CRP and ferritin persisted with the high level of serum IL-6. The administration of TCZ led to the rapid improvement of the patient's fever and marked improvement of the inflammatory responses and achieved continuous remission without recurrence, even after the tapering of PSL. It is considered that conventional treatment with corticosteroids and CyA had a partial effect on the patient's serositis, but that the patient could not reach remission due to his extremely high disease activity. The administration of TCZ, which is a more specific treatment targeting IL-6, ultimately achieved remission.

The third observation in the present case is that we were able to examine the levels of proinflammatory cytokines IL-6 and IL-18 in serum samples taken before and after TCZ treatment. In previous studies, it was reported that the level of IL-6 was increased in the serum and skin rash specimens of AOSD patients, and that it was correlated with the disease activity (6, 18). On the other hand, one report suggested that the serum IL-6 levels were increased in RA and Castleman's disease patients after the administration of TCZ, because the IL-6 receptor-mediated consumption of IL-6 was blocked by the competitive binding of TCZ to the IL-6 receptor (22). These data suggest that the increased level of IL-6 after TCZ administration closely reflects the actual endogenous production of IL-6 and the true disease activity.

The IL-18 levels were also reported to be increased in the serum, skin rash specimens, synovial membrane, and liver of AOSD patients (6, 23, 24). The serum level of IL-18 was well correlated with the AOSD disease activity and could therefore be useful for monitoring the response to treatment (6, 23, 24). Indeed, our patient's IL-6 level also showed a mild increase from 56.8 pg/mL to 79.7 pg/mL, while his level of IL-18 showed a dramatic reduction from 84,000 pg/mL to 47,200 pg/mL after the 2nd TCZ treatment. The kinetics of these cytokines seem to reflect the reduction of the disease activity by TCZ treatment.

In conclusion, our findings support the efficacy of TCZ in the treatment of resistant AOSD accompanied by CP and pleuritis. TCZ is a promising therapeutic option for patients with severe and intractable AOSD.

The authors state that they have no Conflict of Interest (COI).

References

- Gerfaud-Valentin M, Jamilloux Y, Iwaz J, Sève P. Adult-onset Still's disease. *Autoimmun Rev* **13**: 708-722, 2014.
- Agha-Abbaslou M, Bensaci AM, Dike O, Poznansky MC, Hyat A. Adult-onset Still's disease: Still a serious health problem (a case report and literature review). *Am J Case Rep* **18**: 119-124, 2017.
- Yamaguchi M, Ohta A, Tsunematsu T, et al. Preliminary criteria for classification of adult Still's disease. *J Rheumatol* **19**: 424-430, 1992.
- Wouters JM, van der Veen J, van de Putte LB, de Rooij DJ. Adult onset Still's disease and viral infections. *Ann Rheum Dis* **47**: 764-767, 1988.
- Perez C, Artola V. Adult Still's disease associated with mycoplasma pneumoniae infection. *Clin Infect Dis* **32**: e105-e106, 2001.
- Chen DY, Lan JL, Lin FJ, Hsieh TY. Proinflammatory cytokine profiles in sera and pathological tissues of patients with active untreated adult onset Still's disease. *J Rheumatol* **31**: 2189-2198, 2004.
- Priori R, Colafrancesco S, Alessandri C, et al. Interleukin 18: a biomarker for differential diagnosis between adult-onset Still's disease and sepsis. *J Rheumatol* **41**: 1118-1123, 2014.
- Franchini S, Dagna L, Salvo F, Aiello P, Baldissera E, Sabbadini MG. Efficacy of traditional and biologic agents in different clinical phenotypes of adult-onset Still's disease. *Arthritis Rheum* **62**: 2530-2535, 2010.
- Mitamura M, Tada Y, Koarada S, et al. Cyclosporin A treatment for Japanese patients with severe adult-onset Still's disease. *Mod Rheumatol* **19**: 57-63, 2009.
- Jamilloux Y, Gerfaud-Valentin M, Henry T, Sève P. Treatment of adult-onset Still's disease: a review. *Ther Clin Risk Manag* **11**: 33-43, 2015.
- Al-Homood IA. Biologic treatments for adult-onset Still's disease. *Rheumatology (Oxford)* **53**: 32-38, 2014.
- Drouot MH, Hachulla E, Houvenagel E, et al. Cardiac complications in adult onset Still disease: from pericarditis to tamponade as manifestations. *Rev Med Interne* **15**: 740-743, 1994.
- Parvez N, Carpenter JL. Cardiac tamponade in Still disease: a review of the literature. *South Med J* **102**: 832-837, 2009.
- Buss SJ, Wolf D, Mereles D, Blank N, Katus HA, Hardt SE. A rare case of reversible constrictive pericarditis with severe pericardial thickening in a patient with adult onset Still's disease. *Int J Cardiol* **144**: e23-e25, 2010.

15. Dall'Ara F, Frassi M, Tincani A, Airò P. A retrospective study of patients with adult-onset Still's disease: is pericarditis a possible predictor for biological disease-modifying anti-rheumatic drugs need? *Clin Rheumatol* **35**: 2117-2123, 2016.
16. Quartuccio L, Salvin S, Zuliani F, Mansutti E, De Vita S. Pleuritis is a red flag for adult-onset Still's disease which may require biologic therapies. *Clin Exp Rheumatol* **30**: 807, 2012.
17. Ortiz-Sanjuán F, Blanco R, Calvo-Rio V, et al. Efficacy of tocilizumab in conventional treatment-refractory adult-onset Still's disease: multicenter retrospective open-label study of thirty-four patients. *Arthritis Rheumatol* **66**: 1659-1665, 2014.
18. Scheinberg MA, Chapira E, Fernandes ML, Hubscher O. Interleukin 6: a possible marker of disease activity in adult onset Still's disease. *Clin Exp Rheumatol* **14**: 653-655, 1996.
19. Puéchal X, DeBandt M, Berthelot JM, et al.; Club Rhumatismes Et Inflammation. Tocilizumab in refractory adult Still's disease. *Arthritis Care Res (Hoboken)* **63**: 155-159, 2011.
20. Suematsu R, Ohta A, Matsuura E, et al. Therapeutic response of patients with adult Still's disease to biologic agents: multicenter results in Japan. *Mod Rheumatol* **22**: 712-719, 2012.
21. Cipriani P, Ruscitti P, Carubbi F, et al. Tocilizumab for the treatment of adult-onset Still's disease: results from a case series. *Clin Rheumatol* **33**: 49-55, 2014.
22. Nishimoto N, Terao K, Mima T, Nakahara H, Takagi N, Takeuchi T. Mechanisms and pathologic significances in increase in serum interleukin-6 (IL-6) and soluble IL-6 receptor after administration of an anti-IL-6 receptor antibody, tocilizumab, in patients with rheumatoid arthritis and Castleman disease. *Blood* **112**: 3959-3964, 2008.
23. Kawaguchi Y, Terajima H, Harigai M, Hara M, Kamatani N. Interleukin-18 as a novel diagnostic marker and indicator of disease severity in adult-onset Still's disease. *Arthritis Rheum* **44**: 1716-1717, 2001.
24. Colafrancesco S, Priori R, Alessandri C, et al. IL-18 serum level in adult onset Still's disease: a marker of disease activity. *Int J Inflamm* **2012**: 156890, 2012.

The Internal Medicine is an Open Access article distributed under the Creative Commons Attribution-NonCommercial-NoDerivatives 4.0 International License. To view the details of this license, please visit (<https://creativecommons.org/licenses/by-nc-nd/4.0/>).