

CASE REPORT

A case of pulmonary embolism caused by compression of the vena cava by intra-abdominal masses in autosomal polycystic kidney disease

Christopher Holzmann-Littig  | Georg Lorenz | Ming Wen | Uwe Heemann | Lutz Renders

Department of Nephrology, School of Medicine, Klinikum Rechts der Isar, Technical University of Munich, Munich, Germany

Correspondence

Christopher Holzmann-Littig, Klinikum rechts der Isar der Technischen Universität München, Ismaninger Str. 22, 81675 München, Germany.
Email: christopher.holzmann@mri.tum.de

Abstract

Dyspnea can have among other reasons pulmonological and cardiological causes. In cases with intra-abdominal masses such as in severe autosomal dominant polycystic kidney disease, mechanical occlusion of the vena cava may result in pulmonary embolism.

KEYWORDS

acute medicine, ADPKD, autosomal dominant polycystic kidney disease, emergency medicine, nephrology, pulmonary embolism

1 | INTRODUCTION

Approximately 10% of dialysis patients suffer from autosomal dominant polycystic kidney disease. This disorder leads to several complications including infections, hematuria, and chronic pain. Here, we present a case of a 48-year-old patient with pulmonary artery embolism due to vena cava obstruction by the right polycystic kidney.

Although not very common in the general population, autosomal dominant polycystic kidney disease is one of the more common autosomal dominant inherited diseases. The prevalence in dialysis patients is approximately 10% and approximately 1/1000-1/400 live births.^{1,2} The underlying mutation is found in the polycystic kidney disease 1 (PKD1) gene in 85% of all cases and in the PKD2 gene in 15% of all cases.² Common complications are cyst infections, hematuria, cyst bleeding, nephrolithiasis, and chronic pain.³ Cerebral aneurysms may cause intracranial bleeding, yet the risk for aneurysm ruptures is usually regarded low.³ Other organs, particularly the liver, but also blood vessels and the heart can be affected.³ The increasing kidney volume (due to

growing cyst volume) may lead to a compression of intra-abdominal structures; however, a pulmonary embolism caused by this complication has rarely been reported.

2 | CASE HISTORY/EXAMINATION

A 48-year-old male patient presented to our outpatient center for evaluation of his known autosomal dominant polycystic kidney disease (ADPKD). The patient had already received best supportive therapy, including treatment of his arterial hypertension and proteinuria for several years.

At presentation to our outpatient clinic, the actual chronic kidney disease (CKD) stage was G3aA3⁴ and an ultrasound of the abdomen revealed a kidney length of 60.2 cm (right) and 54.6 cm (left).

The patient suffered from dyspnea (NYHA II-III) since approximately 6 months, without angina pectoris. Further, the patient complained about a progressive postprandial sensation of bloating and loss of appetite. These symptoms had

This is an open access article under the terms of the Creative Commons Attribution-NonCommercial-NoDerivs License, which permits use and distribution in any medium, provided the original work is properly cited, the use is non-commercial and no modifications or adaptations are made.

© 2020 The Authors. *Clinical Case Reports* published by John Wiley & Sons Ltd

increased slightly over the last few months, and the patient gradually developed recurrent emesis after eating. The patient had not undergone any immobilization in the past, either through air travel or hospitalization. The family history regarding more thrombotic events was empty.

Physical examination showed a hypo-resonant percussion sound below the 7th/8th rib on both sides, a massively distended abdomen, and discrete bilateral leg edema without circumferential difference. The rest of the physical examination was unremarkable. The blood pressure was 144/96 mm Hg, heart rate 82/min, rhythmic.

At presentation, the creatinine level was 123.8 $\mu\text{mol/L}$ with an estimated glomerular filtration rate, eGFR, (CKD-EPI) of 59 mL/min/1.73 m². The patient had an albuminuria of 62.7 mg/mmol creatinine. The liver enzymes were normal. There were no positive inflammation markers. The INR value was 0.9, the quick value was increased with >120%, and the aPTT was normal with 35 seconds.

2.1 | Differential diagnosis, investigations, and treatment

In order to assess a potential restrictive disorder which appeared to be likely with regard to the kidney volume and the physical examination, a spirometry was performed which showed a VC max of 3.7 L (72% of target value) and total lung capacity of 6.6 L (88% of target value) suggesting a mild restrictive disorder. Tiffenau index was 87% so no obstructive disorder was present. The blood gas analysis showed an arterial oxygen saturation of 92% without any oxygen supplementation and a slight increase to 94% after administration of 2 L O₂ per minute.

In order to rule out pulmonary diseases and to evaluate the altered intra-abdominal organ topography before a possible operation, we performed a CT examination of the thorax and abdomen. The Geneva Score which is also reflected in the ESC Guideline on pulmonary embolism predicted a low probability of a pulmonary artery embolism with 3 points for a heart rate between 74 and 94/min, an active cancer was not known at that time, and all other points were negative.^{5,6} Beside the bilateral kidney masses (c.f. Figure 1), the CT scan then showed a bilateral pulmonary artery embolism (c.f. Figure 2), due to compression of vena cava by the right kidney (c.f. Figure 3) and a long-segment thrombosis of the v. cava.

The patient was admitted to our emergency department and (in accordance with the guideline) anticoagulation therapy with intravenous unfractionated heparin was immediately initiated and later on transitioned to oral rivaroxaban therapy.⁶ In our vascular medicine department, in addition a deep vein thrombosis of the v. poplitea and of the tibial veins of the lower right leg was diagnosed (c.f. Figure 4). Contrast-enhanced abdomen radiography identified a pylorus stenosis caused by the right kidney. MAC3 scintigraphy showed

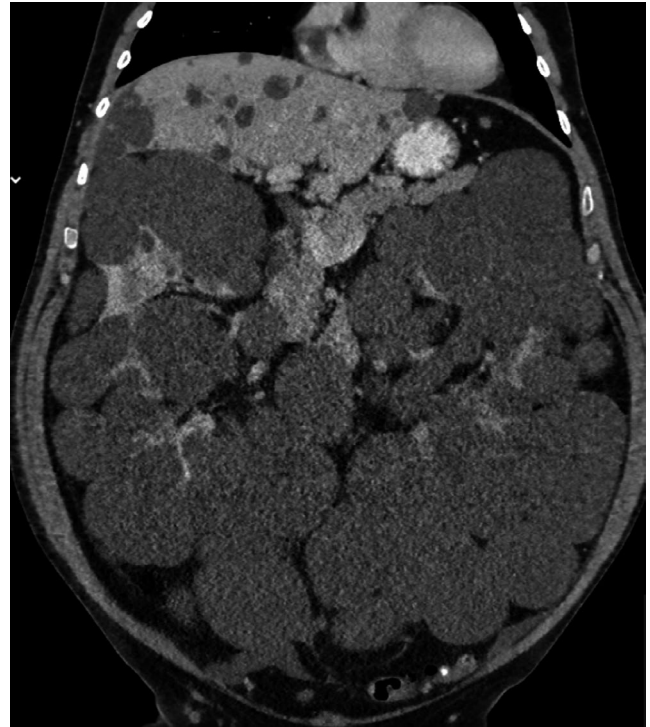

FIGURE 1 Bilateral kidney masses in coronal CT scan. Clinical question: In order to assess a possible indication for surgery, an overview of the topography of the abdominal conditions was needed. This shows that the abdomen is largely filled by the renal masses

that the right kidney contributed 79% to the complete kidney function and the left kidney only 21%. Based on the overall examination results, there was an indication for unilateral nephrectomy. The risk of a partial nephrectomy was considered too high due to the increased risk of bleeding with highly complex organ structure and massively increased cystic kidney volume. Based on the scintigraphy data, the decision was made together with the operating urological colleagues to perform a nephrectomy of the left kidney, as the removal of the right kidney could have led to chronic dialysis. It was expected that the left nephrectomy would also lead to a reduction of the intra-abdominal pressure and thus to a relief of the vena cava and the pylorus. After 6 weeks of anticoagulation, nephrectomy was performed without any complications. The renal function declined moderately from an eGFR (CKD-EPI) of 59–47 mL/min/1.37 m²; the creatinine level was 150.3 $\mu\text{mol/L}$. The postoperative INR value was 0.9, the quick value was normal with 116%, and the aPTT was normal with 31 seconds.

2.2 | Outcome and follow-up

The patient recovered from the surgical intervention. The general condition of the patient and in particular the postprandial

FIGURE 2 Pulmonary embolism (right and left). Clinical question: To clarify pulmonary causes, a CT of the lungs was performed. This revealed a bilateral pulmonary artery embolism

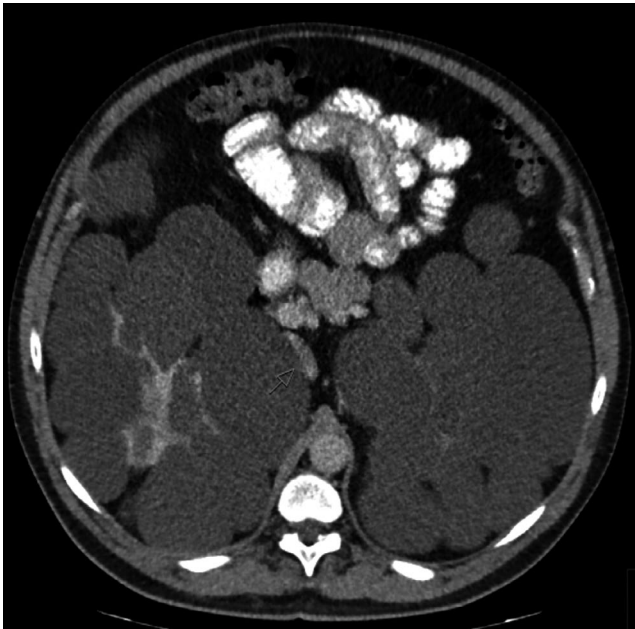
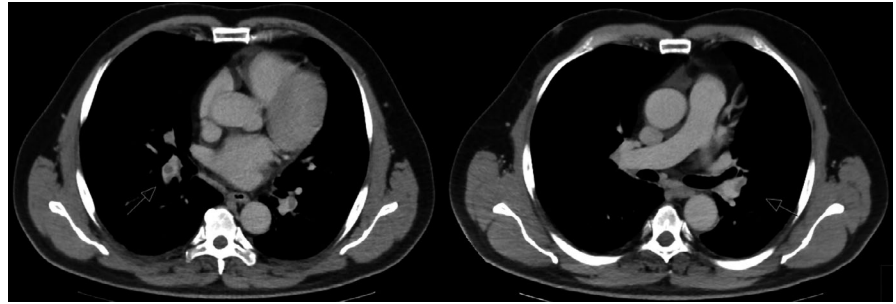


FIGURE 3 Compression and thrombosis of v. cava inferior. Clinical question: The CT was also prepared intraabdominally to clarify the topographic conditions. Here, a compression and thrombosis of the inferior vena cava, caused by the right kidney, was shown

symptoms and dyspnea improved. Additionally, the pathological assessment showed an incidental subcapsular clear cell renal cell carcinoma of 1.2 cm, pT1a, pNX, WHO grade 2, R0, was found in the resected left kidney. The CT scan showed no evidence of any metastases. One week after the operation, the patient was discharged. The follow-up CT scan showed a relief of obstruction of IVC and pyloric stenosis. A follow-up plan according to the guidelines was created, and patient receives interdisciplinary care in the urological and nephrological outpatient department of our hospital.

3 | DISCUSSION

Here, we report a case of pulmonary embolism as a complication of abdominal vena cava obstruction in an ADPKD patient.

According to Virchow's triad hypercoagulability, stasis and endothelial injury lead to venous thrombosis.^{7,8}

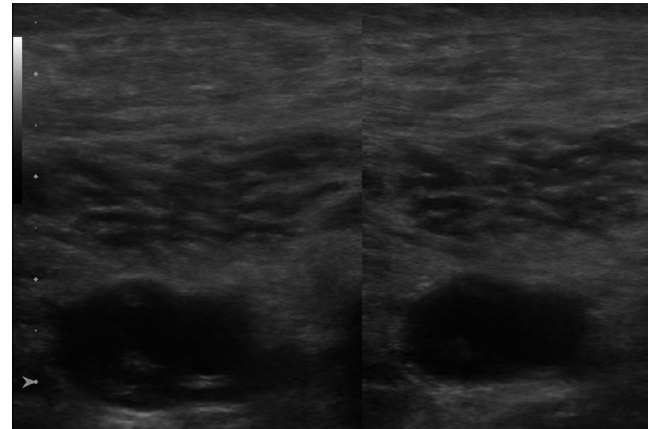


FIGURE 4 Ultrasound of the right distal vena poplitea (no compression possible), Department of Internal Medicine I, Angiology. Clinical question: In case of an obstruction of the drainage via the V. Cava inferior, the question of a consecutive leg vein thrombosis arose. The compression test in sonography revealed a thrombosis of the right popliteal vein

Furthermore, Virchow also described the compression of a vessel as the cause of thrombotic events as early as 1856.⁷ A compression of the inferior vena cava by intra-abdominal masses has been described in the literature; the triggers are often malignant diseases.⁹ The causal factors of pulmonary embolism should be treated as far as feasible. A nephrectomy is usually performed as a last line treatment in patients with recurrent severe cyst infections and episodes of urosepsis, in particular pretransplant. It may also be required in rare cases of pain that cannot be controlled otherwise.³ As the complications were life-threatening, there was an indication for nephrectomy to treat the causative factor, the vascular obstruction.

A small case series of patients suffering from polycystic liver and kidney disease (PLKD) showed clear side differences in MAC3 scintigraphy in three out of five patients, with the largest side difference being 73% vs 27%.¹⁰ In the interest of patient's quality of life, determination of the renal function of each kidney was also carried out by MAC3 scintigraphy preoperatively in this case, despite having approximately the same kidney size on both sides. Also in this case, a clearly different kidney function was shown with 21% vs

79%. Nevertheless, the reasons for these differences remain unclear and still need to be investigated.

In addition to the obstruction of the vena cava by the cyst masses of course, the renal cell carcinoma as an additional risk factor for thrombosis and pulmonary artery embolism in this case may be discussed. A recent study in 2013 showed a preoperative pulmonary embolism in 4.4% of renal cell carcinoma patients with proven venous thrombus.¹¹ Nevertheless, it seems likely that the mechanical obstruction of the vena cava had a significant impact on the development of pulmonary artery embolism.

In addition, this case shows that the symptom dyspnea should always lead to further examination; in this case, several months had passed before the patient also presented himself to our clinic because of this symptomatology. As it is well known, dyspnea may have several reasons such as cardiac pathologies, infections, restrictive, and obstructive disorders as well as pulmonary artery embolism and many other diseases. Cases with pulmonary artery embolism caused by ADPKD are rarely reported. One case report by O'Sullivan et al from 1998 also presented a comparable case.¹² On the other hand, Jacquet et al demonstrated that in kidney transplant patients ADPKD patients showed significantly higher incidence of thromboembolic diseases.¹³ Therefore, either underdiagnosing or underreporting of these events in ADPKD patients may also be discussed. We want to emphasize that in patients with ADPKD and a large kidney volume pulmonary artery embolism is a potential cause of developing dyspnea should be taken into consideration.

CONFLICT OF INTEREST

The authors have declared that no conflict of interest exists.

AUTHOR CONTRIBUTIONS

CHL: involved in conception and design, data acquisition. Georg Lorenz: involved in conception and design. MW: involved in conception and revision of the manuscript. UH: involved in interpretation of the data and revision of the conception of the paper. LR: involved in interpretation of the data/ case and drafting the manuscript.


ETHICAL APPROVAL

This article does not contain any clinical studies with human participants performed by any of the authors.

INFORMED CONSENT

Informed consent was obtained the individual participant in this article.

ORCID

Christopher Holzmann-Littig  <https://orcid.org/0000-0002-9849-148X>

REFERENCES

1. Spithoven EM, Kramer A, Meijer E, et al. Renal replacement therapy for autosomal dominant polycystic kidney disease (ADPKD) in Europe: prevalence and survival—an analysis of data from the ERA-EDTA Registry. *Nephrol Dial Transplant*. 2014;29 (Suppl 4):iv15-25.
2. Noel N, Rieu P. Pathophysiology, epidemiology, clinical presentation, diagnosis and treatment options for autosomal dominant polycystic kidney disease. *Nephrol Ther*. 2015;11(4):213-225.
3. Chapman AB, Devuyst O, Eckardt KU, et al. Autosomal-dominant polycystic kidney disease (ADPKD): executive summary from a kidney disease: improving global outcomes (KDIGO) controversies conference. *Kidney Int*. 2015;88(1):17-27.
4. Levey AS, de Jong PE, Coresh J, et al. The definition, classification, and prognosis of chronic kidney disease: a KDIGO Controversies Conference report. *Kidney Int*. 2011;80(1):17-28.
5. Le Gal G, Righini M, Roy PM, et al. Value of D-dimer testing for the exclusion of pulmonary embolism in patients with previous venous thromboembolism. *Arch Intern Med*. 2006;166(2):176-180.
6. Konstantinides SV, Meyer G, Becattini C, et al. 2019 ESC Guidelines for the diagnosis and management of acute pulmonary embolism developed in collaboration with the European Respiratory Society (ERS). *Eur Heart J*. 2020;41(4):543-603.
7. Virchow RLK. *Gesammelte Abhandlungen zur wissenschaftlichen Medicin*. Frankfurt, Germany: Von Meidinger & Sohn; 1856.
8. Kushner A, West DW, Pillarisetty LS. Virchow Triad. StatPearls. Treasure Island (FL)2020.
9. Kuetting D, Thomas D, Wilhelm K, Pieper CC, Schild HH, Meyer C. Endovascular management of malignant inferior vena cava syndromes. *Cardiovasc Intervent Radiol*. 2017;40(12):1873-1881.
10. Martin AP, Bartels M, Kiehle A, Hauss J, Fangmann J. Polycystic liver and kidney disease: post-transplant kidney function in patients receiving pre-emptive kidney transplantation. *Transpl Int*. 2008;21(3):263-267.
11. Abel EJ, Wood CG, Eickstaedt N, et al. Preoperative pulmonary embolism does not predict poor postoperative outcomes in patients with renal cell carcinoma and venous thrombus. *J Urol*. 2013;190(2):452-457.
12. O'Sullivan DA, Torres VE, Heit JA, Liggett S, King BF. Compression of the inferior vena cava by right renal cysts: an unusual cause of IVC and/or iliofemoral thrombosis with pulmonary embolism in autosomal dominant polycystic kidney disease. *Clin Nephrol*. 1998;49(5):332-334.
13. Jacquet A, Pallet N, Kessler M, et al. Outcomes of renal transplantation in patients with autosomal dominant polycystic kidney disease: a nationwide longitudinal study. *Transpl Int*. 2011;24(6):582-587.

How to cite this article: Holzmann-Littig C, Lorenz G, Wen M, Heemann U, Renders L. A case of pulmonary embolism caused by compression of the vena cava by intra-abdominal masses in autosomal polycystic kidney disease. *Clin Case Rep*. 2020;8:1149–1152. <https://doi.org/10.1002/ccr3.2852>