

Familial adenomatous polyposis with synchronous invasive colonic carcinomas and metastatic jejunal adenocarcinoma in a Nigerian male

Chukwuemeka C. Osuagwu,¹

Okechukwu C. Okafor,²

Emmanuel R. Ezeome,³ Chrisogonus E. Uche,¹

Charles Ememonu,¹ Emeka Kesieme,¹

¹Department of Surgery, Imo State University Teaching Hospital, Orlu, Imo state, Nigeria

²Department of Morbid Anatomy, University of Nigeria Teaching Hospital, Ituku-Ozalla, Enugu State, Nigeria

³Department of Surgery, University of Nigeria Teaching Hospital, Ituku-Ozalla, Enugu State, Nigeria

Abstract

Familial adenomatous polyposis is rare. Three cases were previously reported in Nigeria. An intriguing feature of this case is an ulcerated jejunal carcinoma which was metastatic rather than synchronous carcinoma. This patient presented with partial large bowel obstruction and the pathological analysis revealed 4 invasive adenocarcinomas, 3 in the colon and 1 in the jejunum (Dukes stage D). Palliative pancolectomy and jejunal tumour resection with chemotherapy was offered to him. He died eight months after surgery from disease progression. The challenges of managing a hereditary cancer syndrome in a resource poor country are highlighted.

Case Report

A 40-year-old male small time trader who sells clothes presented at the Emergency Room in 2008 with left lumbar pain and mass. He has two young children. There is no family history of carcinoma of the colon though two of his siblings who lived far away have change in bowel habits. One of the siblings died six months ago following progression of the abdominal symptoms. The diagnosis was never established. He declined further investigations because he presumed his symptoms will resolve spontaneously. He presented one year later with colicky abdominal pain, left lumbar mass, change in bowel habits and

weight loss.

By this time he already had Sister Joseph's nodule and a fixed left lumbar mass. Abdominal ultrasound revealed multiple liver metastases but the chest was radiologically normal. Colonoscopy revealed multiple sessile and pedunculated colorectal polyps and two synchronous invasive ulcerative cancers in the left colon. A stenosing ulcerative tumour was met at the descending colon that prevented the advance of the colonoscope. He paid out of pocket for the cost of his treatment. We did not offer genetic testing to neither him nor his children because we lack the facilities.

A clinical diagnosis of familial adenomatous polyposis (FAP) complicated by partial intestinal obstruction from advanced synchronous colonic carcinomas was made. Informed consent was obtained for pancolectomy and ileorectal anastomosis, with excision of Sister Joseph's nodule. Intra-operative findings included synchronous invasive caecal tumour and two invasive descending colonic tumours. Other findings include invasive jejunal tumour, metastatic masses in the greater omentum, multiple liver metastasis, and carcinomatosis peritonei. Four weeks later, he commenced intravenous leucovorin 20 mg/m² and 5-fluorouracil 500 mg/m² taken weekly for six weeks with two weeks of rest. He had two courses out of six courses. He had esophagogastroduodenoscopy using a 0° gastroscoposcope ten weeks after surgery. We found about three small sessile antral polyps and few duodenal polyps. Two duodenal ulcerated areas were seen in the second and third parts of the duodenum. Our attempt at biopsying these ulcerated areas failed due to the curvature of the duodenum. He was stable initially but later had disease progression despite chemotherapy. He developed a large hepatic mass with ascities. He crossed over to intravenous irinotecan 125 mg/m², 5-fluorouracil 500 mg/m² and leucovorin 20 mg/m² weekly for four weeks. He passed on about eight months after surgery.

The specimen resected consisted of appendix, caecum and colon measuring 72 cm in length with their adjoining mesentery containing nodular masses, (Figure 1) and a jejunal segment measuring 6 cm in length (Figure 3). The colonic mucosa presented numerous sessile polyps (about 100 in number) measuring between 3 mm and 10 mm each (Figure 1) and a single pedunculated polyp measuring 2.5 cm (see white arrow of Figure 1). On the colon were the (primaries), 3 synchronous invasive tumour masses (see black arrows of Figure 1 and yellow arrows of Figure 2) with histological diagnosis of invasive moderately differentiated adenocarcinoma (Figure 4, 5 and 6) with extension into the submucosa. One of these colonic tumours is annular and was stenosing the intestinal lumen. The interesting feature of this case is the invasive

Correspondence: Chukwuemeka C. Osuagwu, Department of Surgery, Imo State University Teaching Hospital, PMB 8, Orlu, Imo State, Nigeria. E-mail: osuagwuemy@yahoo.com

Key words: familial adenomatous polyposis, colon, jejunum, adenocarcinoma.

Contributions: CCO, CEU, CIE, EBK, conceived and designed the brief report; CCO, CEU, CIE, EBK the literature review; CCO, CEU, CIE, EBK wrote and reviewed the final work; CCO, OCO, ERE, CEU, CIE did the literature review; CCO, OCO, ERE, EBK wrote and reviewed the final work.

Conflict of interest: the authors report no conflicts of interest.

Received for publication: 5 January 2010.

Revision received: 24 November 2010.

Accepted for publication: 29 November 2010.

This work is licensed under a Creative Commons Attribution 3.0 License (by-nc 3.0).

©Copyright C.C.Osuagwu et al., 2010
Licensee PAGEpress, Italy
Rare Tumors 2010; 2:e66
doi:10.4081/rt.2010.e66

ulcerated tumour mass on the jejunum measuring 3 cm by 3 cm wide and 2 cm in thickness (Figure 3). In this case the jejunal tumour appears to be radiating from a central point in the subserosal fat, which is more suggestive of a secondary tumour. Secondly, this jejunal tumour is exophytic and pushes into the lumen (see Figure 3) while on the contrary the colonic tumours are cavitating. The histology of this tumour mass is identical to those of the colonic masses but here the tumour extends only to the subserosal fat (Figure 3, Figure 4 and Figure 7).

The nodular masses in the mesentery are ten in number and measure between 15 cm and 0.5 cm in diameter (Figure 1, Figure 2 and Figure 8). They have white glistening external surfaces and their cut surfaces are white and yellowish in colour. The histological examination of these masses shows (metastatic) malignant epithelial proliferation identical to the invasive tumours of the colon and jejunum. The overall TNM Staging of the entire tumour is T4N2M1. The polyps on the colonic mucosa correspond to adenomatous polyps (tubular and villous) with mild to moderate dysplasia (Figure 9 and Figure 10). None had an invasive component.

Discussion

FAP is a disease characterised by the presence of more than a hundred adenomatous colonic polyps which manifest by the second

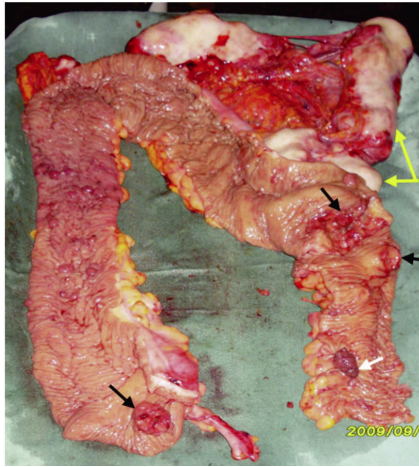


Figure 1. Colectomy specimen showing nodular metastatic masses in the mesentery (yellow arrows), 3 invasive carcinomas on the colonic wall (black arrows), multiple sessile (not indicated by arrows), and a pedunculated (white arrow) adenomatous polyps with mild to moderate dysplasia

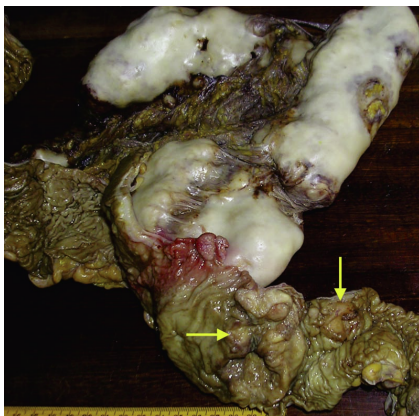


Figure 2. The colonic wall is shown with an 2 invasive ulcerated adenocarcinomas (yellow arrows), one of which is annular and stenoses the intestinal lumen (horizontal yellow arrow). Metastatic nodular masses are seen in the mesentery surrounded by whitish capsules.

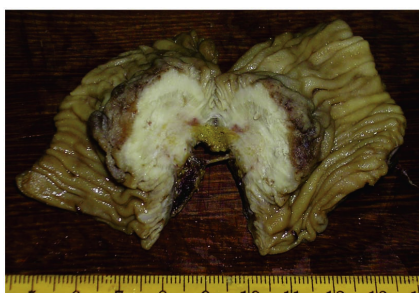

Figure 3. The jejunum is seen with an invasive ulcerated adenocarcinoma. The tumour extends to the subserosal fat but not the serosa. Mass shows whitish tumor growing from the subserosal fat towards the mucosa with elevation of the muscularis propria.

decade of life. It invariably leads to colorectal carcinoma as observed in this patient. It is seen in 1% of colorectal carcinomas.¹ Colorectal carcinoma is one of the three most common cancers² and the commonest gastrointestinal tract cancer.³ There is striking geographical variation in prevalence of colorectal cancer in Nigeria. In the South West, an incidence rate of 26.3 per year⁴ was reported while the South South had low rates of 5.1 per annum.⁵ In the North, the incidence is 12.5-14.4.^{6,7} A recent 10 year review in South West Nigeria highlighted the absence of FAP in 268 cases colorectal cancer.⁸

FAP fortunately is a rare disease.¹ In 80% of cases of FAP, it is inherited as autosomal dominant with incomplete penetrance while in 20% of cases it occurs as a spontaneous mutation without prior family history.⁹ This concurs with our observation in this case and an earlier case in our hospital where a patient with FAP did not have any prior family history.¹⁰ Some authors in Nigeria have reported a case of multiple colorectal polyps presenting with intussusceptions¹¹ and a 3 year old that presented with multiple adenocarcinomas arising in rectal polyps.¹² In the index case two of his siblings who had change in bowel habits could not be evaluated because they were domiciled

far away. The Adenomatous polyposis coli gene (APC) is found on the long arm of chromosome 5 locus 21.¹³ The APC gene can be detected by Protein truncation test.¹⁴ Genetic testing of first degree relatives will help identify the APC gene carriers while allaying the anxiety of non carriers. It also identifies those to be referred for screening colonoscopy. We were challenged with how to discuss the risk of developing FAP and colorectal cancer in the patient's siblings and offsprings considering the patient's grave picture. The Genetic counselling session was made more difficult when the patient offered to have his children undergo genetic tests. Sadly, we lacked facilities to conduct these genetic tests.

The diagnosis was made on colonoscopy which is not readily available in most tertiary hospitals in Nigeria. The practice of screening colonoscopy for relatives, offsprings of FAP and colorectal cancer patients may lead to increased early diagnosis of FAP and colorectal cancer. Routine use of colonoscopy in evaluating patients with lower gastrointestinal symptoms may also improve diagnosis of FAP and other colorectal diseases hence earlier treatment with better prognosis. FAP may occur with other features such as small bowel adenomatous polyposis and gastric polyposis.¹⁵

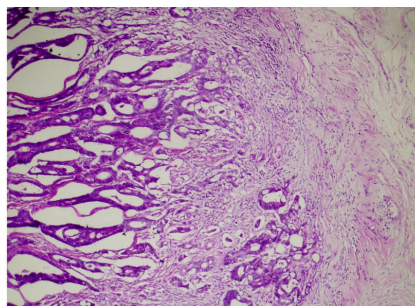


Figure 4. The first colonic adenocarcinoma (Tumour-1) is shown. Note the irregular invasive tumour glands and cord extending into the wall of the colon.

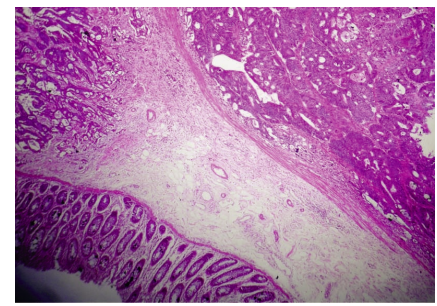


Figure 6. The third colonic adenocarcinoma (Tumour-3) is shown with irregular invasive tumour glands and cords in the mucosa (right side) and submucosa (left side).

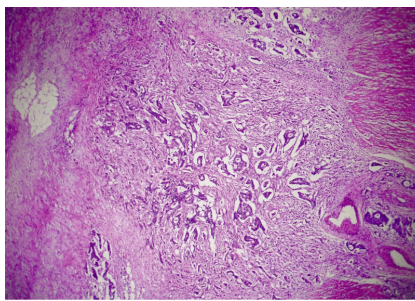


Figure 5. The second colonic adenocarcinoma (Tumour-2) is shown. Note the irregular invasive tumour glands and cords extending beyond the muscularis propria of the wall (right side) into the subserosal tissue.

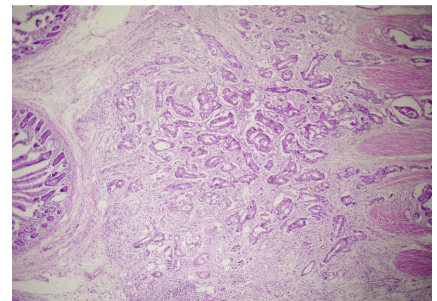


Figure 7. The metastatic adenocarcinoma (Tumour-4) is seen as irregular glands and cords in the submucosa and muscularis propria of the jejunum.

The index patient had upper gastrointestinal endoscopy post operatively which revealed gastric and duodenal polyps with two ulcerated areas in the second and third parts of the duodenum. We had to weigh the benefit of diagnosing upper gastrointestinal polyps against the cost of his surgical treatment and chemotherapy for the advanced disease. This comes into stark focus when this small time trader who sells clothes has to pay out of pocket for these investigations and treatment.

Our patient declined further investigations a year earlier because he presumed he could get better without medical help. He may have been a missed case of FAP but for the compli-

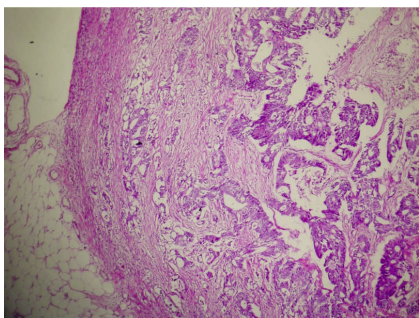


Figure 8. One of the metastatic nodules in the mesentery is shown with similar appearing irregular invasive tumour glands and cords.

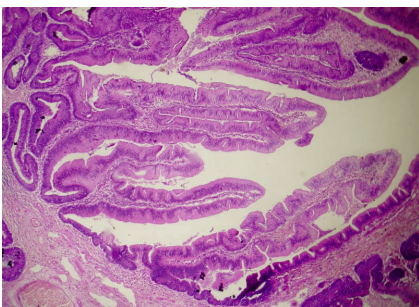


Figure 9. The pedunculated polyp is shown with villous structures lined by tall epithelial cells. There is no stromal invasion.

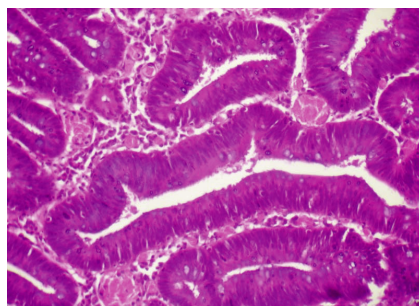


Figure 10. One of the sessile polyps is shown with tubular structures lined by epithelium demonstrating decreased mucin secretion and nuclear pseudostratification with conservation of polarity - moderate dysplasia.

cations and spread that led to his late presentation with partial intestinal obstruction, omental masses, hepatic metastasis and carcinomatosis peritonei (Dukes D).

In some late cases, the omental masses (metastasis) seen in the index patient may present as an epigastric mass hence inducing the physician into believing that the cancer is in the transverse colon or the stomach. The synchronous invasive colorectal carcinoma in association with invasive jejunal adenocarcinoma is interesting as observed in this case. It threw up the debate whether this is a synchronous jejunal tumour or a metastasis. One case of metachronous jejunal adenocarcinoma has been described.¹⁶ In our patient the ulcerated jejunal lesion was radiating from the subserosal fat hence our conclusion that this is a metastatic jejunal adenocarcinoma not a synchronous tumour. Three synchronous colonic ulcerating adenocarcinomas were seen in the colon. The small adenocarcinomas all involved the mucosa and looked similar to the larger stenosing ulcerated adenocarcinoma.

Earlier presentation is associated with a better prognosis after panproctocolectomy and a terminal ileostomy or an ileoanal anastomosis. The decision to offer this patient pancolectomy with ileorectal anastomosis was made preoperatively when liver metastasis was found on ultrasound. We weighed the increased risk involved in performing pancolectomy in the presence of partial intestinal obstruction and metastatic disease against a left hemicolectomy. While a left hemicolectomy will relieve the partial obstruction the patient may develop intussusceptions from other colonic polyps. The surgeon is thus faced with the dilemma of performing extensive resections on cases that present late and with complications. In Africa, history of hereditary diseases are sought in prenuptial enquires before consent for marriage is granted by parents and elders. The history of hereditary cancer may cause stigmatization which will threaten prospects of younger family members getting married. Sometimes, this may limit patients with hereditary diseases from aspiring for prominent administrative positions in the community. The challenges posed by hereditary diseases frequently threaten family unity. The managing Physician also plays the role of genetic and family counsellors. The members of extended family want to know the causes and consequences of hereditary diseases. They also want to be involved in decisions concerning management of their kinsman because they may pool their resources to pay for his treatment. In resource poor countries, there is a great need for development of manpower and facilities for genetic studies which will complement cancer research, screening and management.

Conclusions

It is possible that poverty and ignorance led to this patient declining proper medical attention until the cancer became metastatic. Despite the rarity of this condition it is important that this is brought to the fore as one of the differentials of metastatic colorectal carcinoma. We also wish to point out that the small intestinal mucosa is a possible site of synchronous adenocarcinoma or metastasis in FAP and should be thoroughly evaluated in screening exercises. In resource poor environment, there are serious challenges in terms of cost of investigation and treatment. We also face potential ethical challenges and limitations imposed by lack of the needed skills and facilities for optimal management of these patients in an African setting.

References

1. Elkharwily A, Gottlieb K. Pancreas in familial adenomatous polyposis. *JOP* 2008;9:9-18.
2. Makinen MJ. Colorectal serrated adenocarcinoma. *Histopathology* 2007;50:131-50.
3. Abdulkareem FB, Abudu EK, Awolola NA et al. Colorectal carcinoma in Lagos and Sagamu, Southwest Nigeria: a histopathological review. *World J Gastroenterol* 2008;14:6531-5.
4. Iliyasu Y, Ladipo JK, Akang EE et al. A twenty-year review of malignant colorectal neoplasms at University College Hospital, Ibadan, Nigeria. *Dis Colon Rectum* 1996;39:536-40.
5. Essiet A, Iwatt AR. Surgical management of large bowel cancer 1983-1988, University of Calabar Teaching Hospital audit. *Cent Afr J Med* 1994;40:8-13.
6. Edino ST, Mohammed AZ, Ochicha O. Characteristics of colorectal carcinoma in Kano, Nigeria: an analysis of 50 cases. *Niger J Med* 2005;14:161-6.
7. Sule AZ, Mandong BM, Iya D. Malignant colorectal tumours: a ten year review in Jos, Nigeria. *West Afr J Med* 2001;20:251-5.
8. Irabor DO, Arowolo A, Afolabi AA. Colon and rectal cancer in Ibadan, Nigeria. An update. *Colorectal Dis.* 2009 Apr 27. [Epub ahead of print]
9. Bussey HJR. *Familial polyposis coli. Family studies, histopathology, differential diagnosis and results of treatment.* Baltimore: Johns Hopkins University Press. 1975.
10. Nzegwu MA, Osuagwu CC, Machembarrena JM, et al. Familial adenomatous polyposis complicated with invasive col-

- orectal adenocarcinoma in a 26-year-old Nigerian male - a rare finding. *Eur J Cancer Care* 2007;16:198-200.
11. Adebamowo CA, Yawe T, Ladipo JK. Recurrent intussusception reduced by the patient: a case report. *East Afr Med J* 1995;72:267-8.
 12. Udofot SU, Ekpo MD, Khalil MI. Familial polyposis coli: an unusual case in West Africa. *Cent Afr J Med* 1992;38:44-8.
 13. Nishisho I, Nakamura Y, Miyoshi Y, et al. Mutations of chromosome 5q21 genes in FAP and colorectal cancer patients. *Science* 1991;253:665-9.
 14. Powell SM, Petersen GM, Krush AJ, et al. Molecular diagnosis of familial adenomatous polyposis. *N Engl J Med* 1993;329:1982-7.
 15. Bisgaard ML, Bülow S. Familial adenomatous polyposis (FAP): Genotype correlation to FAP phenotype with osteomas and sebaceous cysts. *Am J Med Genet A* 2006;140:200-4.
 16. Zuidema MF, Dekker W. A patient with a metastasizing jejunal carcinoma 17 years after colectomy for familial polyposis coli. *Neth J Med* 1989;34:317-21.