



Contents lists available at ScienceDirect

## International Journal of Surgery Case Reports

journal homepage: [www.casereports.com](http://www.casereports.com)

## Acute abdominal syndrome revealing an intestinal amoebiasis: Report of two cases in Tunisia

Ghaith Hamdi<sup>a</sup>, Aida Zaghdoudi<sup>b,\*</sup>, Mohamed Taieb Frikha<sup>a</sup>, Mounir Makhlof<sup>a</sup>, Karim Sassi<sup>a,b,c</sup>, Mourad Ben Badr<sup>a</sup>, Mohamed Ben Slima<sup>a,b,c</sup>

<sup>a</sup> General Surgery Department, Hopital La Rabta, Tunis, Tunisia

<sup>b</sup> Infectious Diseases Department, Hopital La Rabta, Tunis, Tunisia

<sup>c</sup> University of Tunis El Manar, Faculty of Medicine of Tunis, Tunisia

## ARTICLE INFO

## Article history:

Received 4 January 2021

Received in revised form 17 January 2021

Accepted 17 January 2021

Available online 20 January 2021

## Keywords:

Intestinal amoebiasis

Colitis

Surgery

Case report

## ABSTRACT

Amoebiasis is a parasitosis, mainly caused by *Entamoeba histolytica* (*E. histolytica*). It is a common disease in tropical and subtropical regions. *E. histolytica* possesses different mechanisms of pathogenicity, and might lead to the invasion and lysis of the intestinal epithelium. Outside of the high-risk regions, acute intestinal amoebiasis is a very rare condition, often leading to misdiagnosis and death, if not promptly treated. We discuss the cases of 18 and 43 year-old men without medical history, who presented to the emergency department complaining of acute abdominal pain along with fever. Following imaging features and clinical presentation, appendicitis and a complicated form of Crohn's disease were respectively suspected. Given the severity of the symptoms, an explorative laparotomy was performed showing in both cases an inflammatory aspect of the intestine. Histological examination concluded intestinal amoebiasis, a diagnosis that wasn't suspected at first. The learning point of these cases is considering invasive intestinal amoebiasis in patients presenting with an acute abdominal syndrome, even with no history of traveling abroad or immunodeficiency.

© 2021 Published by Elsevier Ltd on behalf of IJS Publishing Group Ltd. This is an open access article under the CC BY-NC-ND license (<http://creativecommons.org/licenses/by-nc-nd/4.0/>).

### 1. Introduction and importance

Intestinal amoebiasis caused by *Entamoeba histolytica* is mostly widening in developing countries with poor sanitation, yet becoming increasingly frequent in developed countries. It is an invasive enteric human parasite oro-fecally transmitted. Amoebic infections are asymptomatic in approximately 90% of cases. However, the invasive intestinal form can cause mild to severe dysenteric syndromes. Multiple diagnosis methods are available such as; microscopic stool study, antigen detection in the serum, and histological study of operative samples. A combination of these tests is often needed to establish the diagnosis. Nitroimidazoles are the standard treatment for invasive amoebiasis. Surgery is performed in case of intestinal perforation or necrosis.

Tunisia is a low-risk area for amoebiasis. Many physicians fail to consider intestinal amoebiasis in the differential diagnosis of the acute abdominal syndrome. Thus, it is important to conduct further examinations, including those for amoebiasis, when investigating acute abdominal syndrome. This case report has been reported in line with the SCARE Criteria [1].

\* Corresponding author at: Résidence Jawhara, A5, Ali Mawardi Street, Ennasser 1, Ariana, Tunisia.

E-mail address: [zaghdoudi.aida2@gmail.com](mailto:zaghdoudi.aida2@gmail.com) (A. Zaghdoudi).

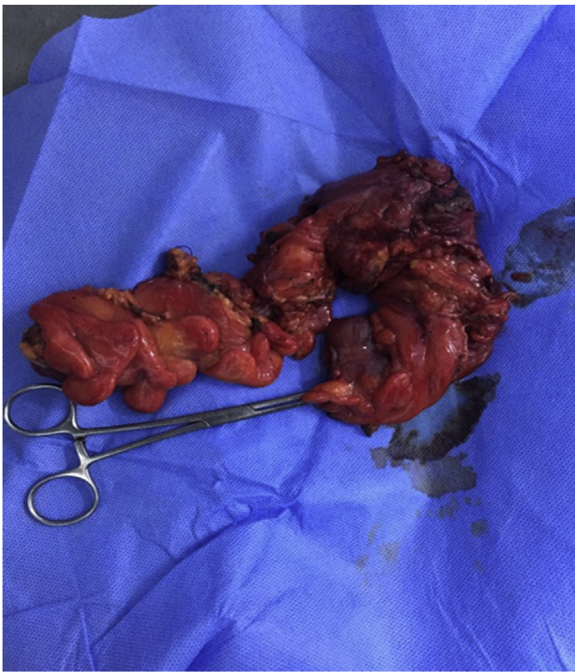<https://doi.org/10.1016/j.ijscr.2021.01.068>

2210-2612/© 2021 Published by Elsevier Ltd on behalf of IJS Publishing Group Ltd. This is an open access article under the CC BY-NC-ND license (<http://creativecommons.org/licenses/by-nc-nd/4.0/>).

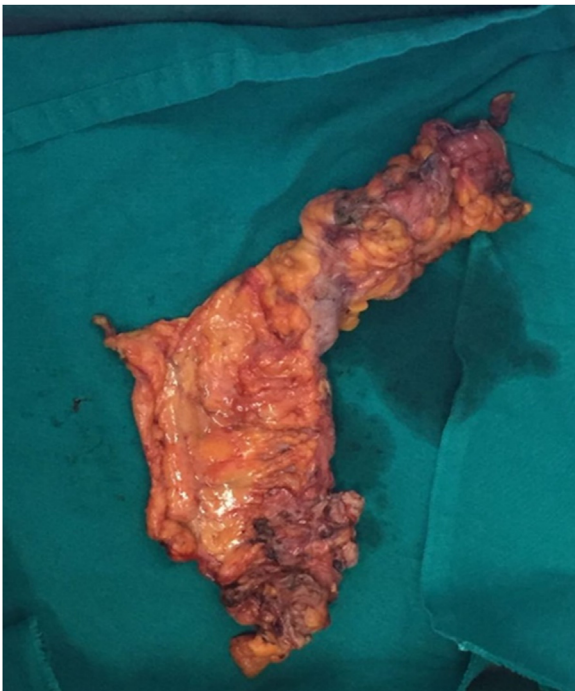
### 2. Case presentation

#### 2.1. 1st case

We report the case of an 18-year-old man with no medical nor specific family history. He did not smoke nor drink alcohol. He was a law student and often ate at the university canteen. He hasn't traveled to tropical nor subtropical areas and wasn't taking any medications. He consulted our teaching hospital's emergency department complaining of acute abdominal pain in the right iliac fossa that was evolving for three days, along with fever. On clinical examination, he had a body temperature of 39-degree celsius. The entire abdomen was tender with a defense on palpation of the right iliac fossa. Routine blood tests showed a C reactive protein rate at 288 mg/L and neutrophilic leukocytosis. Given the peritoneal irritation signs, it was decided to perform a laparotomy. Per-operative exploration showed a purulent effusion in the right iliac fossa and the Douglas. The ileum and cecum were macroscopically healthy, with an inflammatory appendix. No other abnormalities were found. An appendicectomy with a peritoneal lavage was performed. The surgical follow-up was easy and the patient was quickly discharged. However, on the eleventh day post-operatively, he consulted complaining of the worsening of his initial symptoms. The abdominal CT scan showed an effusion facing the ileocecal junction and a thickened caecum. A second explorative

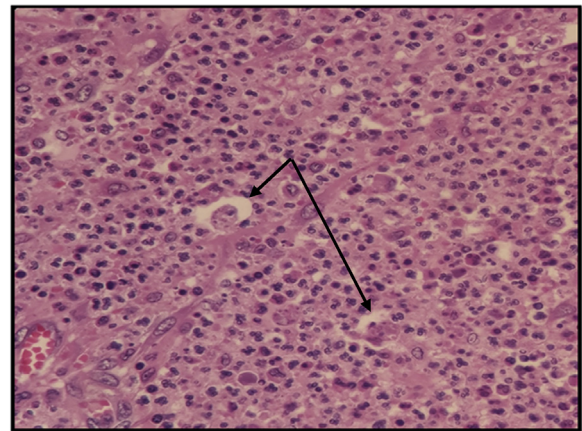


**Fig. 1.** Ileocecal resection specimen showing a inflammatory and perforated coecum.



**Fig. 2.** Ileocecal resection specimen with a perforation in the last ileal loop.

laparotomy was performed by a junior surgeon with 3 years and a half of surgical specialty training and a senior surgeon. An inflamed and perforated caecum was seen (Fig. 1). It was a two-millimeter perforation blocked by the large omentum. An ileocecal resection followed by an ileocolic anastomosis was made. On gross examination, several areas of necrotic defects located in the cecum were seen. The histopathological examination concluded to a polymorphous inflammatory infiltrate with neutrophilic polynuclear cells and hematophagous trophozoites (Fig. 2). The diagnosis of malignant colonic amoebiasis was finally made. Surgical follow-up was



**Fig. 3.** Polymorphous inflammatory infiltrate with neutrophil polynuclear cells and hematophagous trophozoites.

easy. The patient was given broad-spectrum antibiotics including metronidazole. Gastrointestinal transit was recovered 4 days after the intervention. Feeding was authorized after the drainage system's removal, on the 5th day. The patient was discharged 6 days following the surgery and put under low-molecular-weight heparin as venous thromboembolism prophylaxis and metronidazole (1,5 g per day) for an additional 10 days. He was then referred to the gastroenterology department for further investigations.

## 2.2. 2nd case

Our second case is about a 43-year-old man with no medical nor drug history, who consulted for diffuse abdominal pain with diarrhea. The diagnosis of viral gastroenteritis was retained and he received symptomatic treatment.

Thirteen days later, he came back complaining of fever and peritoneal signs. On clinical examination he was hemodynamically stable, the body temperature was 38.2 degrees celsius and the abdominal examination showed periumbilical defense.

Routine blood tests were normal except a functional renal failure and neutrophilic leukocytosis. Abdominal CT scan showed an inflammatory aspect of the last ileal loop and the coecum, multiple collections in the right iliac fossa and the Douglas. No signs of acute appendicitis were seen. Urgent drainage of the largest collection in the radiology department was performed, showing a purulent liquid. Afterward, the patient was transferred to our department and an emergent laparotomy was practiced. Peroperative exploration revealed advanced acute peritonitis with false membranes, generalized purulent effusion, multiple collections, a perforation in the last ileal loop (Fig. 3), an inflammatory cecum, and multiple mesenteric adenopathies. The rest of the digestive tract was normal. Abundant peritoneal lavage with saline solution and ileocecal resection was performed. A double-barrel ileostomy was made in the right iliac fossa after detaching the right colonic angle. This procedure was performed by a senior surgeon and two junior surgeons that had 2 and 3 years of surgical specialty training respectively. Surgical follow-up was also easy for this patient. He was put under a prophylactic antibiotic therapy (third-generation cephalosporin, metronidazole, aminoglycosides) and low-molecular-weight-heparin. The diagnosis of a complicated Crohn's disease was strongly suspected and the patient was transferred on the 6th day postoperatively to the gastroenterology department. The colonoscopy through the ileostomy was normal. The histological examination of the ileal and colonic biopsies concluded an inflammatory infiltrate with hematophagous amoebas (Fig. 3). The final diagnosis was colonic amoebiasis in its fulminant

form. He received metronidazole intravenously for 5 days followed by an oral relay for a total of 14 days. The outcome was satisfactory and the restoration of digestive continuity was performed with an elective approach four months later.

Clinical outcomes as assessed by the surgeons were satisfactory with no post-operative complications in both cases. Both patients had a rapid recovery and returned to their daily activities quickly with no deterioration in the quality of their lives. Current surgical safety practice was perceived positively by both of them. They also expressed a high level of satisfaction with their care. However, they identify physician-patient interactions, relationships, and trust as the main factors that had positively influenced their perception of the intervention. The initial surgical experience and patient's income were the only significant factors that negatively influenced their perception.

### 3. Discussion

Amoebiasis is a parasitosis caused by one of the three amebic species. *Entamoeba histolytica* can be responsible for invasive intestinal or extraintestinal diseases, *E. moshkovskii* causes non-invasive diarrhea, while *E. dispar* is non-pathogenic. *Entamoeba histolytica* has a two-stage life cycle. It can be found as a unicellular mobile trophozoite in the intestine or as a quadri-nuclear cyst in the external environment [2]. These infective cysts are expelled with feces and survive for a long time in moisture areas [3]. Infection is triggered by the ingestion of *E. histolytica* cysts contained in contaminated water or food. Then, trophozoites are formed in the intestinal tract and sometimes, totally invade the colonic epithelium causing its lysis [2].

Thereafter, the infection might expand to the liver through the portal vein or by a direct extension through the peritoneum [4]. The caecum and the rectum are the most frequently invaded but any part of colonic mucosa can be affected [5].

*E. histolytica* is a serious global health issue as it continues to be the third leading cause of death from parasitic diseases [6]. Amoebiasis affects at least 10% of the world's population causing 100,000 deaths per year [5]. Prevalence is the highest in developing countries particularly in the Indian subcontinent, sub-Saharan tropical regions of Africa, and parts of Central and South America. Nowadays, amoebiasis is an emerging parasitic infection in industrialized countries because of the rising immigrant population and the growing number of international travels [7]. Risk factors that have been identified in almost all countries were linked to inadequate barriers between human feces, food and water [8]. Children, pregnant women, and patients taking immunosuppressive drugs are at a higher risk of developing invasive amoebiasis [9]. Besides, bowel perforation caused by invasive amoebiasis has more frequently been described in 40–50 year-old men [10].

Diagnosis of intestinal amoebiasis is challenging and can be mistaken with other conditions such as Crohn's disease. Clinical manifestations can be acute or delayed for several months after infection [6]. Moreover, in 90% of cases, amoebic infection is asymptomatic. It's a cyst passing carrier state [2]. As for symptomatic patients, two types of clinical pictures have been described. The most frequent one is the non-dysenteric form, defined as diarrhea, abdominal cramps, and right lower quadrant tenderness. The dysenteric or invasive infection is defined by mucoid or bloody diarrhea, abdominal cramps. Fever is not constant in this form [11].

Complications such as perforation of the colon, colonic ulcers, amoeboma or chronic carriage are rare [7]. One of the most severe complications is fulminant necrotizing colitis. This condition is observed in about 0.5% of cases and is associated with a 40% mortality rate. Liver-abscess is the most common extraintestinal manifestation and can also lead to extra-abdominal amoebiasis [8].

Thoracic amoebiasis is the most common type of extra-abdominal amoebiasis followed by pericardiac and cerebral localisations [12].

Various laboratory diagnosis methods are used such as microscopic examination of the stool, antigen detection, molecular tests, and amoebic serology [13]. In developing countries, the diagnosis is based on the identification of mature cysts in stool samples' examination [14]. The most sensitive and specific test is antigen detection in stool by a polymerase chain reaction (PCR). However, this test is not widely available because of its significant cost [2]. Antibody detection is helpful in the diagnosis of extra-intestinal forms, where stool studies might not be contributive. Another diagnosis method is histology. Histological samples are obtained during endoscopic examination or surgical procedures. Trophozoites can be found at the margin of the ulcer or in the surrounding tissue. As for imaging, ultrasonography, abdominal CT scan, and magnetic resonance imaging are sufficient to detect liver abscess [13].

All patients infected with *E. histolytica* should be treated. In the asymptomatic form, patients are treated with a luminal cystocidal agent to avoid transmission and invasive infection [13]. Symptomatic patients require the combination of two drugs: an amebicidal tissue-active agent and a luminal cystocidal agent. Amebicidal agents include tinidazole and metronidazole. They are highly effective against invasive trophozoites and remain the first-line treatment for amoebic colitis and also amoebic liver abscesses [12]. In case of fulminant amoebic colitis, fluid resuscitation and broad-spectrum antibiotic therapy will be required. Surgical treatment is necessary in case of bowel perforation or necrosis. An intestinal resection followed by the restoration of digestive continuity should be performed, depending on the severity of the lesions and patient's general condition [15].

### 4. Conclusion

Amoebiasis continues to be one of the world's most common enteropathogens. A better insight into the pathogenesis of invasive amoebiasis will help to develop targeted therapeutics and perhaps a vaccine.

The absence of specific symptoms makes the diagnosis difficult. In countries with intermediate endemicity, such as Tunisia infection with *E. histolytica* must be excluded in the presence of a dysenteric syndrome. Thus, we should strengthen the knowledge of this diagnosis among health workers.

### Declaration of Competing Interest

The authors report no declarations of interest.

### Sources of funding

No funding was received for our work.

### Ethical approval

The study is exempt from ethical approval in your institution please state this.

### Consent

Written informed consent was obtained from the patient for publication of this case report and accompanying images.

### Author contribution

Ghaith Hamdi and Aida Zaghdoudi conceived the case report, collected the data. Ghaith Hamdi Aida Zaghdoudi and Mohamed

Taieb Frikha analysed the data and wrote the manuscript. Mohamed Ben Slima supervised the work. All authors discussed the results and contributed to the final manuscript.

### Registration of research studies

Not applicable.

### Guarantor

Dr. Mohamed Ben Slima.

### Provenance and peer review

Not commissioned, externally peer-reviewed.

### Acknowledgments

None.

### References

- [1] R.A. Agha, T. Franchi, C. Sohrabi, G. Mathew, A. Kerwan, A. Thoma, et al., The SCARE 2020 guideline: updating consensus Surgical CAse REport (SCARE) guidelines, *Int. J. Surg.* [Internet] 84 (2020) 226–230, Dec 1 [cited 2021 Jan 14], Available from: <https://pubmed.ncbi.nlm.nih.gov/33181358/>.
- [2] Mandell, Douglas, and Bennett's Principles and Practice of Infectious Diseases - 9780323482554 | US Elsevier Health Bookshop [Internet], 2020 [cited 2020 Apr 20]. Available from: <https://www.us.elsevierhealth.com/mandell-douglas-and-bennetts-principles-and-practice-of-infectious-diseases-9780323482554.html>.
- [3] A. Lohia, The cell cycle of *Entamoeba histolytica* [Internet], *Mol. Cell. Biochem.* 253 (2003) 217–222 [cited 2020 Apr 13]. Available from: <http://link.springer.com/10.1023/A:1026055631421>.
- [4] L.A. Baxt, U. Singh, New insights into *Entamoeba histolytica* pathogenesis, *Curr. Opin. Infect. Dis.* 21 (2008) 489–494, NIH Public Access.
- [5] M.S. Park, K.W. Kim, H.K. Ha, D.H. Lee, Intestinal parasitic infection [Internet], *Abdom. Imaging* 33 (2008) 166–171 [cited 2020 Apr 13]. Available from: <http://link.springer.com/10.1007/s00261-007-9324-z>.
- [6] S.G. Wright, Protozoan infections of the gastrointestinal tract [Internet], *Infect. Dis. Clin. North Am.* 26 (2012) [cited 2020 Apr 13], p. 323–39. Available from: <https://linkinghub.elsevier.com/retrieve/pii/S0891552012000189>.
- [7] C. Marie, W.A. Petri, Amoebic dysentery, *BMJ Clin. Evid.* 2013 (2013), BMJ Publishing Group.
- [8] S.L. Stanley, Amoebiasis, *Lancet* [Internet] (2003), Elsevier Limited, [cited 2020 Apr 15], p. 1025–34. Available from: <https://linkinghub.elsevier.com/retrieve/pii/S0140673603128309>.
- [9] S. Roure, L. Valerio, L. Soldevila, F. Salvador, G. Fernández-Rivas, E. Sulleiro, et al., Approach to amoebic colitis: epidemiological, clinical and diagnostic considerations in a non-endemic context (Barcelona, 2007–2017), *PLoS One* 14 (February (2)) (2019).
- [10] H. Wang, R. Kanthan, Multiple colonic and ileal perforations due to unsuspected intestinal amoebiasis—case report and review, *Pathol. Res. Pract.* 216 (January (1)) (2020), 152608.
- [11] A. Grosse, Diagnosis of colonic amebiasis and coexisting signet-ring cell carcinoma in intestinal biopsy, *World J. Gastroenterol.* 22 (September (36)) (2016) 8234–8241.
- [12] M.L.M. Gonzales, L.F. Dans, J. Sio-Aguilar, Antiamoebic drugs for treating amoebic colitis, *Cochrane Database Syst. Rev.* 2019 (2019), John Wiley and Sons Ltd.
- [13] A Review of the Global Burden, New Diagnostics, and Current Therapeutics for Amebiasis [Internet], 2020 [cited 2020 Apr 17]. Available from: <https://www.ncbi.nlm.nih.gov/pmc/articles/PMC6055529/>.
- [14] M. Tanyuksel, W.A. Petri, Laboratory diagnosis of Amebiasis, *Clin. Microbiol. Rev.* 16 (2003) 713–729, American Society for Microbiology (ASM).
- [15] D.A. Shirley, S. Moonah, Fulminant amebic colitis after corticosteroid therapy: a systematic review, *PLoS Negl. Trop. Dis.* 10 (July (7)) (2016).

### Open Access

This article is published Open Access at [sciencedirect.com](https://www.sciencedirect.com). It is distributed under the [IJSCR Supplemental terms and conditions](#), which permits unrestricted non commercial use, distribution, and reproduction in any medium, provided the original authors and source are credited.