

## Case Report

# Recurrent Bacterial Meningitis Accompanied by A Spinal Intramedullary Abscess

Min Seong Kim, M.D., Ph.D.,<sup>1</sup> Chang Il Ju, M.D., Ph.D.,<sup>2</sup> Seok Won Kim, M.D., Ph.D.,<sup>2</sup> Hyun Young Lee, M.D., Ph.D.<sup>3</sup>

Departments of Dermatology,<sup>1</sup> Neurosurgery,<sup>2</sup> Anesthesia,<sup>3</sup> College of Medicine, Chosun University, Gwangju, Korea

Bacterial meningitis is rarely complicated by an intradural spinal abscess, and recurrent meningitis is an uncommon presentation of a spinal intramedullary abscess. Here, we report a 63-year-old patient with recurrent meningitis as the first manifestation of an underlying spinal intramedullary abscess. To the best of our knowledge, no previous report has been issued on recurrent meningitis accompanied by a spinal intramedullary abscess in an adult. In this article, the pathophysiological mechanism of this uncommon entity is discussed and the relevant literature reviewed.

**Key Words :** Spinal · Intramedullary abscess · Meningitis.

## INTRODUCTION

Bacterial meningitis is frequently accompanied by intracranial and systemic complications, such as septic shock, adult respiratory distress syndrome, or disseminated intravascular coagulation in children. However, spinal cord involvement is an extremely rare complication of bacterial meningitis in adults<sup>5</sup>. Recurrent bacterial meningitis is defined as repeated episodes of acute infection followed by periods during which signs and symptoms are absent and cerebrospinal fluid (CSF) is normal, and is usually a complication of a cranial anatomical defect or the result of impaired humoral immunity, notably, a complement system defects or agammaglobulinemia<sup>2</sup>. Recurrent bacterial meningitis can present a diverse range of symptoms in children, but no previous report has been issued of recurrent meningitis accompanied by a spinal intramedullary abscess in an adult<sup>2</sup>. In this article, we report a rare and interesting case of recurrent bacterial meningitis in an adult presenting as a spinal intramedullary abscess.

## CASE REPORT

A 63-year-old man was admitted to the emergency department complaining about severe suboccipital headache, fever, and neck pain lasting for 5 days. On physical examination, he was alert and

fully oriented, but febrile (38.3°C) and had apparent nuchal stiffness with positive Kernig and Brudzinski signs. His pupils were midsize and reactive to the light, and bilateral papilledema was not detected in the fundoscopic examination. A laboratory examination revealed a white blood cell count of 13,100/mm<sup>3</sup> and an erythrocyte sedimentation rate (ESR) of 78 mm/hour. For the diagnosis of bacterial meningitis, lumbar puncture (LP) was performed after emergent brain computed tomography (CT) scan, which ruled out any space-occupying lesion within brain parenchyma. CSF contained 792 cells/μL (94% polymorphonuclear cells), protein level was 6.3g/dL, and his CSF glucose level was less than 15% of the serum glucose level. From the CSF Gram-positive cocci were found, and *Staphylococcus aureus* (*S. aureus*) was isolated. Hence, ceftriaxone (Hanmi Pharmaceuticals, Korea) and vancomycin (CJ Pharmaceuticals, Korea), which had been initiated empirically before confirmation of *staphylococcus*, were continued for 14 days. An obvious clinical improvement occurred after LP and antibiotic therapy, and he was discharged after a second LP that revealed infection was resolved by culture (42 white blood cells and normal glucose and protein in CSF). However, 6 days after discharge, he was readmitted due to the reappearance of fever and severe headache. He was also complaining about decreased sensation on the lower extremities, but his motor power remained intact. Laboratory data showed leukocytosis (12300/mm<sup>3</sup> with 89% neutrophils) and elevated

• Received : December 8, 2011 • Revised : March 26, 2012 • Accepted : June 12, 2012

• Address for reprints : Seok Won Kim, M.D., Ph.D.

Department of Neurosurgery, College of Medicine, Chosun University, 365 Pilmun-daero, Dong-gu, Gwangju 501-717, Korea

Tel : +82-62-220-3126, Fax : +82-62-227-4575, E-mail : chosunns@hanmail.net

• This is an Open Access article distributed under the terms of the Creative Commons Attribution Non-Commercial License (<http://creativecommons.org/licenses/by-nc/3.0>) which permits unrestricted non-commercial use, distribution, and reproduction in any medium, provided the original work is properly cited.

ESR at 60 mm/hour. LP revealed 2000 cells/ $\mu$ L (90% polymorphonuclear cells), protein at 9.0 g/L, and a glucose level of 29 mg/100 mL, but the second CSF culture was negative for *S. aureus*. Magnetic resonance imaging (MRI) of the thoracolumbar spine revealed a homogeneously enhanced solid lesion in gadolinium enhanced T1 weighted images (Fig. 1). A 6-week course of high-dose, broad-spectrum antibiotics (ceftriaxone, vancomycin) was administered again and a series of magnetic resonance images were taken every 3 week. Subsequently, previous homogeneously enhanced lesion showed extensive reduction (Fig. 2). No surgical removal was performed, due to rapid improvement of his clinical symptoms and radiological findings. 10 months after first clinical manifestation, the patient has been symptom-free.

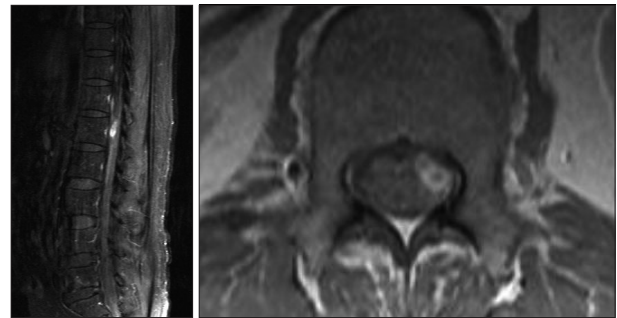
## DISCUSSION

A spinal intramedullary abscess is extremely rare as compared with an intracranial intradural abscess. This rarity is attributed to the absence of sinuses in the spinal cord, the width of filtering epidural space, which filters, and the centripetal pattern of blood flow as compared with the centrifugal pattern of blood flow in the brain<sup>4,7</sup>. Most of these lesions are either secondary to hematogenous spread from a cardiopulmonary source or originate in mediastinal, peritoneal, or retroperitoneal spaces<sup>6</sup>. Acute bacterial meningitis is a potentially life-threatening infection of the cranial and spinal leptomeninges, and although recurrent episodes of meningitis are rarely seen in children, if they occur, an extensive investigation has to be made to identify the etiologic factors. Congenital or acquired anatomical defects are the most common entities that accompanied by recurrent meningitis in children. However, in this case, which developed in an adult, we could not identify the primary source of responsible for the spinal cord abscess, and no congenital defects, such as, a dermoid sinus, were evident. The CSF cultures in our patient were negative at discharge and readmission, which might have been a result of antibiotic therapy. However, given his laboratory CSF findings, a negative CSF culture did not rule out recurrent meningitis. The clinical presentations of acute spinal cord abscess are depend on the location of an abscess and are consistent with fever, back pain, an increased WBC and ESR, and partial or total transverse myelitic features<sup>1</sup>. MRI visualizes the extent and the location of an abscess better than CT or myelography. In addition, MRI also can be used to determine the extent of disease, to distinguish solid lesions, and it may suggest the nature of the lesion<sup>3</sup>. After the diagnosis has been made, prompt decompressive laminectomy, myelotomy, and surgical drainage along with appropriate antibiotics, which are the mainstay of the treatment. Due to the eloquent location of the lesion in our patient and the lack of symptoms at diagnosis, 6 weeks of broad-spectrum antibiotic therapy was considered with close clinical and imaging follow up (MRI was performed 3 weekly to monitor the size of the lesion).

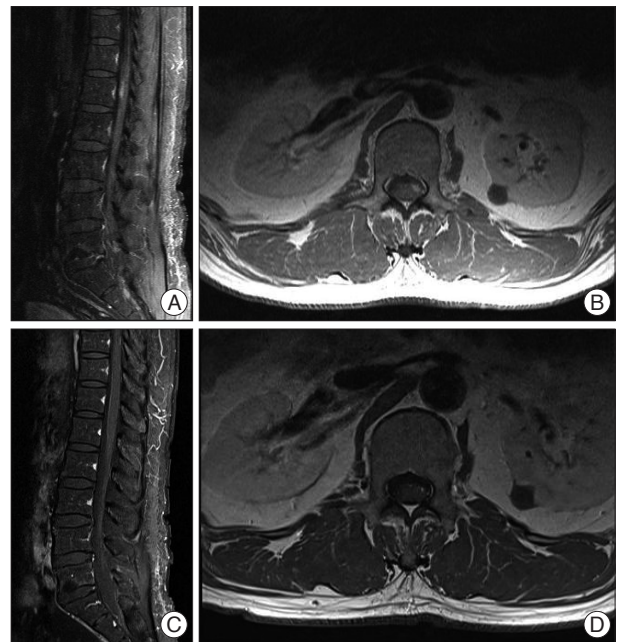This case is rare in some respects. First, a spinal intramedullary abscess combined with a recurrent bacterial meningitis is uncommon in adults. Second, a causative pathogen of the meningitis was identified by lumbar puncture. Third, full recovery was gradually achieved after antibiotic therapy without surgery. Although it is not clear whether the spinal intramedullary abscess was the source of the meningeal infection in this case, it seems that this is the first case to suggest such a relationship between these two entities in an adult.

## CONCLUSION

We report a rare case of recurrent bacterial meningitis who recovered from the disease by antibiotic therapy to treat a spinal intramedullary abscess in an adult. Although rare, the relation-



**Fig. 1.** Sagittal and axial magnetic resonance images of the patient. Gadolinium enhanced sagittal and axial magnetic resonance images reveal homogeneously enhanced mass lesion at L1 level.



**Fig. 2.** Follow up magnetic resonance images of the patient. A and B : Gadolinium enhanced sagittal and axial magnetic resonance images done at the third week after re-admission show extensive reduction of the mass lesion. C and D : Gadolinium enhanced sagittal and axial magnetic resonance images reveal complete resolution of mass lesion at sixth week after re-admission.

ship between spinal intramedullary abscess and recurrent meningeal infection should be borne in mind.

#### References

1. Babu R, Jafar JJ, Huang PP, Budzilovich GN, Ransohoff J : Intramedullary abscess associated with a spinal cord ependymoma : case report. *Neurosurgery* 30 : 121-124, 1992
2. Baradaran N, Ahmadi H, Nejat F, El Khashab M, Mahdavi A, Rahbarimanesh AA : Recurrent meningitis caused by cervico-medullary abscess, a rare presentation. *Childs Nerv Syst* 24 : 767-771, 2008
3. Benzil DL, Epstein MH, Knuckey NW : Intramedullary epidermoid associated with an intramedullary spinal abscess secondary to a dermal sinus. *Neurosurgery* 30 : 118-121, 1992
4. Kulkarni AG, Chu G, Fehlings MG : Pyogenic intradural abscess : a case report. *Spine (Phila Pa 1976)* 32 : E354- E357, 2007
5. Roos KL : Bacterial Meningitis. *Curr Treat Options Neurol* 1 : 147-156, 1999
6. Tacconi L, Arulampalam T, Johnston FG, Thomas DG : Intramedullary spinal cord abscess : case report. *Neurosurgery* 37 : 817-819, 1995
7. Thomé C, Krauss JK, Zevgaridis D, Schmiedek P : Pyogenic abscess of the filum terminale. Case report. *J Neurosurg* 95 : 100-104, 2001