

The Temporal Course of the MRI Findings of Inferior Olive Hypertrophy: The Clinicoradiologic Presentation of a Rare Patient with Holmes Tremor and Palatal Myoclonus

Dear Editor,

A 44-year-old male patient was admitted to our polyclinic due to a left-sided tremor that had started six months ago and progressed gradually. The patient had a history of pontine hemorrhagic stroke 15 months ago, and he was immobile due to severe truncal ataxia since then. However, this readmission was

due to newly-onset left-sided tremor, and further interrogation of the medical history revealed that the patient had also been suffering from clicking noises, and muscle spasms at the back of the throat within this period. The neurological exam showed right-sided peripheral type facial paralysis and slight paralysis on the left upper and lower extremities that were evaluated as

a sequela of the previous stroke. The cerebellar exam showed severe truncal ataxia and cerebellar abnormalities on the left side. Besides, the severe high-amplitude and low-frequency tremor on the left extremity was apparent during the resting posture, and it intensified with action, that was compatible with Holmes tremor [Video 1]. The oropharyngeal examination also revealed palatal myoclonus [Video 2]. Levodopa (up to 3×150 mg) and clonazepam (2 mg) treatments failed to improve the tremor; however, oral biperiden 2×2 mg tablet provided moderate improvement in tremor and quality of life of the patient. The patient had applied multiple times previously due to pontine hemorrhage and newly onset tremor, and he had undergone cranial MRIs several times for etiological investigation of stroke and newly emerging Holmes tremor. The cranial CT and cranial MRI images of the patient were retrospectively re-evaluated. The cranial MRI, performed one month after the pontine hemorrhage, showed a normal appearance of the inferior Olivary nucleus. However, the hypertrophic Olivary degeneration was present on the MRI, performed 10 months after the event, and it persisted on the last MRI four months later [Figure 1].

Symptomatic palatal myoclonus is classically associated with hypertrophic olivary degeneration on MRI due to a lesion in the triangle of Guillain-Mollaret.^[1] The olive receives inhibitory (GABAergic) signals within the dentato-rubro-olivary pathway, which explains that the trans-neuronal degeneration cause enlargement of the olive rather than atrophy.^[1,2] Efferent fibers of the

dentate nucleus project to the contralateral red nucleus via the superior cerebellar peduncle after decussating in the brachium conjunctivum. Thereafter, efferent fibers of the red nucleus traverse through the central tegmental tract to the ipsilateral inferior olivary nucleus and from there to the contralateral cerebellum via the inferior cerebellar peduncle. However, many aspects need to be clarified regarding the pathophysiology of the clinic in association with the lesion in the triangle of Guillain-Mollaret.^[3] The pathophysiology of contralateral tremor in association with the lesion of the Guillain-Mollaret is basically explained via a mechanism of disruption in the afferent and efferent projections to the contralateral cerebellum.^[4] However, there are also many other lesions of the brainstem and also thalamus that are reported to lead to Holmes tremor. Although the lesion of substantia nigra is not typically associated with Holmes tremor, the involvement of the nigrostriatal fibers that might lead to dopaminergic denervation is suggested to be a crucial contributory mechanism in light of the evidence showing a marked decrease of [18F]-fluorodopa uptake in the striatum contralateral to the tremor in a limited number of patients.^[5]

However, we know that many of the cases have normal dopaminergic neuroimaging results.^[6] Besides, the improvement in the tremor is not notable in a large amount of the subjects, and nearly half of the patients are unresponsive to levodopa, suggesting the disruption of networks other than the dopaminergic pathway.^[7] Another interesting point regarding the pathophysiology of Holmes tremor is its specific feature of

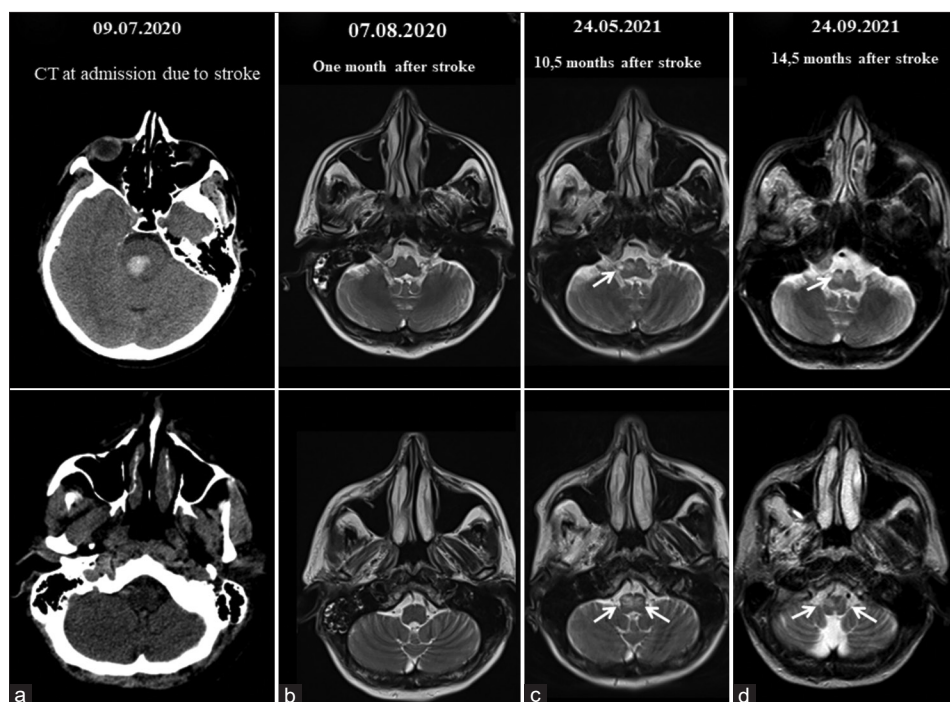


Figure 1: The figure showing the temporal course of the neuroimaging findings of the bilateral hypertrophy of the inferior olivary nucleus, prominent on the right side. (a) The cranial tomography showing the right pontine hemorrhage. (b) Cranial MRI, performed one month after the event, showing a normal appearance of the inferior olivary nucleus. (c) Cranial MRI, performed 10 months after the event, showing the development of the hypertrophic inferior olivary nucleus. (d) MRI, performed 14 months after, shows the persistence of the appearance

being delayed onset after stroke. The compensatory mechanisms or secondary changes in the central nervous system such as brain plasticity have been accused; however, the mechanisms processing from the insult to the occurrence of tremor are poorly understood.^[4] Remarkably, the radiological appearance of inferior olivary degeneration is often seen several months after the original insult as well.^[1] The clinical presentation and the serial imaging data of our patient present a smart clinicoradiological illustration of hypertrophic olivary degeneration. The MRI, performed one month after the event, shows a normal appearance of the inferior olivary nucleus. However, the MRI, performed at admission due to newly emerging tremor, 10 months after stroke, shows the development of the hypertrophic inferior olivary nucleus. The final MRI, four months after, still showed the persistence of the abnormal signal of the Olivary nucleus. The results of the future prospective studies of a larger number of patients may also provide substantial contributions in this regard. The clinicians should be aware of this radiological appearance while performing the differential diagnosis and the palatal myoclonus should be kept in mind as a pathognomonic finding of this entity.^[1,8]

Declaration of patient consent

Informed consent has been obtained from the patient.

Financial support and sponsorship

Nil.

Conflicts of interest

There are no conflicts of interest.

Halil Onder, Bilge Kocer, Selcuk Comoglu

Neurology Clinic, Diskapi Yildirim Beyazit Training and Research Hospital,
Ankara, Turkey

Address for correspondence: Dr. Halil Onder,

Neurology Clinic, Diskapi Yildirim Beyazit Training and Research Hospital, Şehit
Ömer Halisdemir Street, No: 20 Altındag, Ankara - 06110, Turkey.
E-mail: halilonder@yahoo.com

REFERENCES

1. Goyal M, Versnick E, Tuite P, Cyr JS, Kucharczyk W, Montanera W, *et al.* Hypertrophic olivary degeneration: Metaanalysis of the temporal evolution of MR findings. *AJNR Am J Neuroradiol* 2000;21:1073-7.
2. Jun B. The development of hypertrophic inferior olivary nucleus in oculopalatal tremor. *Neuroophthalmology* 2016;40:297-9.
3. Vidailhet M, Jedynak CP, Pollak P, Agid Y. Pathology of symptomatic tremors. *Mov Disord* 1998;13(Suppl 3):49-54.
4. Rieder CR, Reboucas RG, Ferreira MP. Holmes tremor in association with bilateral hypertrophic olivary degeneration and palatal tremor: Chronological considerations. Case report. *Arq Neuropsiquiatr* 2003;61:473-7.
5. Remy P, de Recondo A, Defer G, Loc'h C, Amarengo P, Plante-Bordeneuve V, *et al.* Peduncular 'rubral' tremor and dopaminergic denervation: A PET study. *Neurology* 1995;45:472-7.
6. Gajos A, Budrewicz S, Koszewicz M, Bienkiewicz M, Dabrowski J, Kusmierek J, *et al.* Is nigrostriatal dopaminergic deficit necessary for Holmes tremor to develop? The DaTSCAN and IBZM SPECT study. *J Neural Transm (Vienna)* 2017;124:1389-93.
7. Rocha Cabrero F, De Jesus O. Holmes tremor. In: *StatPearls. Treasure Island (FL); 2021.*
8. Pearce JM. Palatal myoclonus (syn. palatal tremor). *Eur Neurol* 2008;60:312-5.

Submitted: 12-Nov-2021 **Revised:** 23-Dec-2021 **Accepted:** 16-Jan-2022

Published: 06-Apr-2022

Videos available on: www.annalsofian.org

This is an open access journal, and articles are distributed under the terms of the Creative Commons Attribution-NonCommercial-ShareAlike 4.0 License, which allows others to remix, tweak, and build upon the work non-commercially, as long as appropriate credit is given and the new creations are licensed under the identical terms.

For reprints contact: WKHLRPMedknow_reprints@wolterskluwer.com

DOI: 10.4103/aian.aian_983_21