




Original Article

# Traumatic brain injury caused by Brazil-nut fruit in the Amazon: A case series

Mylena Miki Lopes Ideta<sup>1</sup>, Louise Makarem Oliveira<sup>1</sup>, Gustavo Lopes de Castro<sup>1</sup>, Marco Antonio Leal Santos<sup>2</sup>, Erik Leonardo Jennings Simões<sup>3</sup>, Daniel Buzaglo Gonçalves<sup>1</sup>, Robson Luis Oliveira de Amorim<sup>1,4</sup>

<sup>1</sup>Departament of Neurosurgery, Getúlio Vargas University Hospital - Federal University of Amazonas, Manaus, AM, Brazil, <sup>2</sup>Department of Neurosurgery, Hospital Maradei - Clínica dos Acidentados, Belém, PA, Brazil, <sup>3</sup>Department of Neurosurgery, Hospital Regional do Baixo Amazonas, Santarém, PA, Brazil, <sup>4</sup>Department of Neurosurgery, University of São Paulo, São Paulo, SP, Brazil..

E-mail: Mylena Miki Lopes Ideta - mylena.miki15@gmail.com; Louise Makarem Oliveira - louisemakarem@gmail.com; Gustavo Lopes de Castro - gustavolopes@gmail.com; Marco Antonio Leal Santos - marquinho\_santos13@hotmail.com; Erik Leonardo Jennings Simões - erik@paju.net.br; \*Daniel Buzaglo Gonçalves - danielbuzaglo13@gmail.com; Robson Luis Oliveira de Amorim - amorim.robson@gmail.com



\*Corresponding author:

Daniel Buzaglo Gonçalves,  
Faculty of Medicine, Federal  
University of Amazonas,  
Manaus, Amazonas, Brazil.

danielbuzaglo13@gmail.com

Received : 17 March 2021

Accepted : 11 July 2021

Published : 09 August 2021

DOI

10.25259/SNI\_279\_2021

Quick Response Code:



## ABSTRACT

**Background:** Traumatic brain injury (TBI) represents one of the leading public health problems and a significant cause of neurological damage. Unintentional causes of TBI are the most frequent. However, fruit falling over the head causing TBI is extremely rare. In the Amazon region, accidents with ouriços, a coconut-like shell fruit, seem relatively common. However, to the best of our knowledge, it has never been described in a scientific journal before. Therefore, we aim to evaluate a series of TBI caused by this tropical fruit.

**Methods:** This study is a retrospective review of 7 TBI cases due to the fall of ouriços admitted to two tertiary hospitals in the Amazon region from January 2017 to December 2018. The collected data included: age, Glasgow Coma Scale, skull fracture, venous sinus injury, hematoma, surgical treatment, and outcome.

**Results:** All patients were men, with an average age of 38, ranging from 8 to 77-years-old. Four out of seven had skull fractures. Five patients developed an epidural hematoma, and two of them had an associated subdural hematoma. Dura mater injury was observed in two patients, whereas four patients were operated. There was one related death.

**Conclusion:** This case series is the first to describe an unconventional but potentially fatal cause of TBI in the Amazon: the falling of the Brazil-nut fruit. Most patients were diagnosed with mild TBI. Nevertheless, patients may have cranial fractures and epidural hematomas, leading to death when there's a delay in medical assistance.

**Keywords:** Amazon, Brazil nut tree, Epidemiology, Traumatic brain injury, Unintentional injury

## INTRODUCTION

Traumatic brain injury (TBI) represents one of the leading public health problems and an important cause of neurological damage, with high morbimortality rates. It occurs in all age groups, but it is more frequent in young men.<sup>[13]</sup> TBI may be unintentional (falls, motor-vehicles crashes, being struck by or against an object, and mechanism unspecified), intentional (assault or homicide and self-harm), or of undetermined intent.<sup>[7,22]</sup>

This is an open-access article distributed under the terms of the Creative Commons Attribution-Non Commercial-Share Alike 4.0 License, which allows others to remix, tweak, and build upon the work non-commercially, as long as the author is credited and the new creations are licensed under the identical terms.

©2021 Published by Scientific Scholar on behalf of Surgical Neurology International

The unintentional causes of TBI are far more common than the others. Accidentally being struck by or against an object, for instance, was responsible for 15.4% of all TBI emergency department visits, hospitalization, and deaths in the United States from 2007 to 2013, with most cases occurring among those aged 0–24-years-old.<sup>[24]</sup> Therefore, head injury due to falling objects may represent another important, yet not so highlighted event.<sup>[13]</sup>

Grivna *et al.* (2013) have described that falling objects accounted for 6% of all trauma injuries and that the head was the third most commonly harmed anatomical site, representing 19.5% of the cases.<sup>[11,22]</sup> One subtype of this unexpected form of TBI is fruit falling from trees. The current data regarding these specific injuries are scarce, and just few reports describe TBI due to falling coconut fruit.<sup>[3,8,16]</sup> Mulford *et al.* (2001) stated that coconut palm-related injury was implicated in 3.4% of all patients presenting to the surgical department in the Pacific Islands. Most patients had fell from the tree; however, 15.2% (16 patients) had a coconut fruit fall on them. There was no report of death in this series, but two children had severe neurological deficit.<sup>[16]</sup>

In the Amazon Forest, there's the Brazil-nut tree. Its fruit, a coconut-like shell called “ourico,” is much heavier than the coconut from palm trees. Despite the recurrent news in local media,<sup>[20,21]</sup> an extensive literature review showed this phenomenon's paucity report.<sup>[9,10,14,15]</sup> Therefore, we aim to evaluate a series of TBI cases caused by this tropical fruit in this study.

Although, lying in the middle of the Amazon forest and isolated from most of the country due to the lack of roads, Manaus is the only city providing specialized care for TBI patients to Amazonas state,<sup>[6,12]</sup> and Santarém is the city which provides medical assistance to the western of the Para state. However, the countryside's challenging health condition, marked by the lack of proper accessibility and integrality, prevents many victims from being promptly evaluated.

## MATERIALS AND METHODS

This study is a retrospective review of TBI cases due to Brazil-nut fruit - ouriços - fall admitted in the main trauma hospital in Manaus (Hospital e Pronto-Socorro João Lúcio Pereira Machado) and Santarém (Hospital Municipal), from January 2017 to December 2018. The clinical data were collected through medical charts and included: age, Glasgow Coma Scale (GCS), skull fracture, venous sinus injury, hematoma, surgical treatment, and outcome. The tomographic findings were reviewed from the digital files of both hospitals. Due to a lack of information regarding skull fractures in the attending neurosurgeon's operative report, the data “skull fracture” was collected only from the computed tomography (CT) findings. Informed consent was

obtained from all individual participants included in the study.

## ILLUSTRATIVE CASES

### Case 1

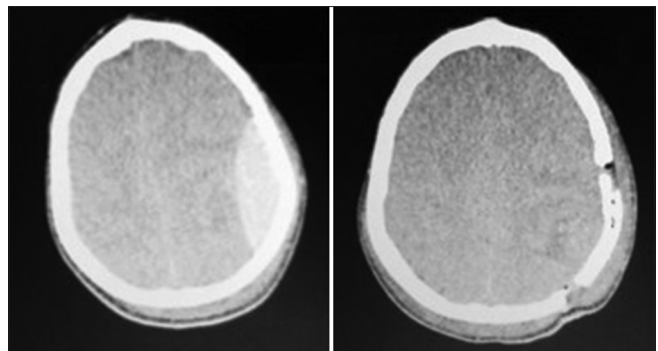
A 13-year-old with emesis, dizziness, dysarthria, right paresis, and paresthesia was admitted to our service with the initial GCS of 13. He was initially evaluated at a local hospital in the countryside, where he received analgesics, mannitol, and corticosteroids. After being transferred to Manaus, he underwent a cranial CT which revealed a left parietal epidural hematoma [Figure 1]. We performed a craniotomy for hematoma drainage and suction drain placement. The time between trauma and the beginning of surgery was approximately 72 h. He was discharged with a GCS of 15 and no alterations in the neurological exam.

### Case 2

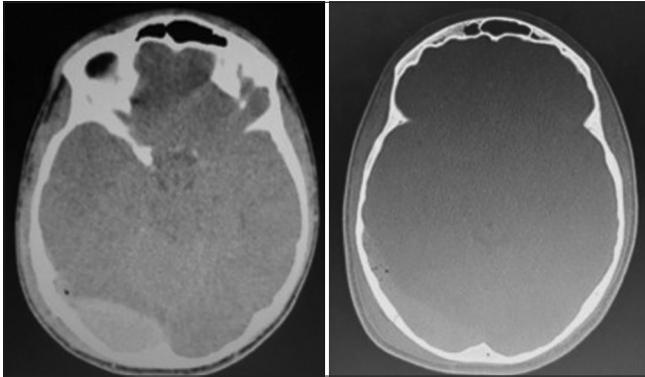
A 15-year-old boy struck by brazil-nut fruit in the occipital region presented with intense headache, emesis, and visual turbidity. At the first evaluation in a local hospital, the patient received analgesics and corticosteroids. He was transferred to Manaus and arrived at our service with a GCS of 15. The cranial CT findings were pneumocephalus and occipital fracture associated with epidural hematoma [Figure 2]. Approximately 120 h after the trauma, he underwent craniotomy for evacuation of the hematoma. He was discharged with a GCS of 15.

### Case 3

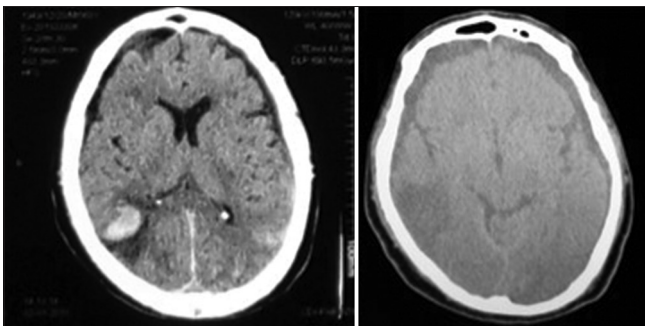
A 68-year-old Brazil-nut collector suffered from TBI due to a falling ouriço over the right parietal region. He presented at the local emergency department with confusion, headache, dizziness, dysarthria, paresis, and blurred vision. The referral to our hospital occurred only after 3 days, with a GCS of 15. Head CT showed a frontal-occipital subarachnoid hemorrhage and right temporoparietal intracerebral hemorrhage [Figure 3]. The treatment was conservative.



**Figure 1:** Cranial CT revealed left parietal epidural hematoma.



**Figure 2:** Cranial CT findings were pneumocephalus, occipital fracture associated with epidural hematoma, and dura mater injury.



**Figure 3:** Cranial CT displayed frontal-occipital subarachnoid and right temporoparietal intracerebral hemorrhage.

**RESULTS**

In this case series, all patients were men and from the countryside, among which two were agriculturists. The average age was 38, ranging from 8 to 77-years-old.

Four patients had skull fractures - half of which were in the frontoparietal region. The most common intracranial finding was extradural hematoma, seen in five patients, and one of them had an associated acute subdural hematoma. Furthermore, two patients had dura mater injury and subarachnoid hemorrhage – and one of them also had an intracerebral hemorrhage. Surgical treatment was performed in four patients. In all of them, we performed craniotomy with hematoma evacuation. Finally, the only death occurred in a child admitted lately in the emergency department, with a GCS of 3 and no brain stem function signs. Head CT revealed a large epidural hematoma that was not evacuated. Details are summarized in [Table 1].

**DISCUSSION**

This case series is the first about TBI caused by ouriços falling. Clinical manifestations may vary, but most patients evolve with total recovery. Epileptic seizures, paresis, and paresthesia are some of the most frequently observed symptoms. It is vital to highlight that resulting lesions can lead to unfavorable outcomes that include death,<sup>[3,8,16]</sup> which occurred in one patient

**Table 1:** Epidemiological characteristics, hospital data, cranial CT findings, and outcome.

Patient No.	Age	Sex	Admission GCS	Cranial CT findings				Surgery	Outcome
				Fracture	Venous sinus injury	Dura mater injury	Hematoma		
1.	22	M	7	Right frontoparietal	No	No	Right frontoparietal epidural and subdural hematoma	Yes	Discharged with GCS 15
2.	77	M	13	Right parietal	No	Yes	Right parietal epidural hematoma	Yes	Discharged with GCS 15
3.	8	M	3	No	No	No	Right temporoparietal epidural hematoma	No	Death
4.	13	M	13	No	No	No	Left parietal epidural hematoma	Yes	Discharged with GCS 15
5.	15	M	3	Occipital	No	Yes	Left occipital epidural hematoma	Yes	Discharged with GCS 15
6.	64	M	15	Right frontoparietal	No	No	Right frontoparietal epidural hematoma	No	Discharged with GCS 15
7.	68	M	15	No	No	No	Frontal-occipital subarachnoid and right temporoparietal intracerebral hemorrhage	No	Discharged with GCS 15

GCS: Glasgow Coma Scale


of these series. Therefore, this novel mechanism of trauma requires medical acknowledgment. Ouriço's fall is particularly interesting for the neurosurgical field as neurosurgeons play an essential role in modifying the disease's course.

Brazil-Nut Tree (*Bertholletia excelsa*) reaches from 30 m to 50 m<sup>[26]</sup> [Figure 4]. It produces a capsular 20-cm fruit, named ouriços, which contains an average of 15 to 25 almonds – the edible part of the fruit<sup>[5]</sup> [Figure 5]. Brazil nut extractivism is a common practice in the countryside of Brazil. Gathered nuts are seen not only as an income source but as a food delicacy. The fruit has a dark brown thick and hard surface, with a medium weight of 750 g.<sup>[23]</sup> The ouriços' fall season is from November to March, a period in which many workers become incredibly susceptible to head injuries.<sup>[25]</sup>

Aiming to assess ouriços' damage when hitting the human's head, it is imperative to consider some variables, such as fall velocity and angle, fruit density, and diameter. If an ouriço weighing 0.75 kg falls from 50 m, the impact velocity is 31.32 m/s – about 1.4 times greater than the impact velocity of a coconut fruit, as described by Barss *et al.* (1984).<sup>[3]</sup> Considering the principle of energy conservation to calculate the impact energy transmitted by an impacting object to a target, the kinetic energy (KE) is approximately 367.875 J. The relationship



**Figure 4:** Brazil-nut tree (*Bertholletia excelsa*) in native region. (Bitencourt, 2020).



**Figure 5:** Brazil-nut tree's ouriço. (A) Ouriço. (B) Trace of the chalice of the flower. (C) Shell. (D) Diameter. (E) Almonds. (Bitencourt, 2020).

between the impactor's KE and its diameter is expressed by the blunt criterion (BC), validated for skull fractures by Raymond *et al.* (2009).<sup>[19]</sup> In this study, BC = 1.61 represented a 50% chance of skull fracture. On a different note, according to Radi (2013), if we consider a curved surface, an object's impact with KE greater than 50J is very likely to cause severe or fatal injuries.<sup>[1]</sup> Hence, a 0.75 kg ouriço would be able to cause severe to fatal injuries by falling from merely 6.8 m.

Children seem to be a risk group for severe and fatal lesions since their skull's resistance to fractures is considerably lower than adults'. For example, the fracture resistance for an adult is 11 times greater than that of a neonate.<sup>[17]</sup> Another important risk group are brazil-nut collectors because of the naturally increased exposition to what can be classified as an occupational hazard.

Due to the nature of the injury - an impact on the head's top - it was expected that the prominent cranial abnormalities were fractures and extradural hematomas. Although most patients were admitted with few clinical manifestations, the presence of an epidural hematoma without any focal neurological symptom is not rare. We must remember that these injuries are associated with a lucid interval, after which the neurological condition may deteriorate.

Thus, in patients with a GCS lower than 15 or with a high-impact trauma history, head CT is mandatory, as well as in children with irritability, subgaleal hematoma, and a history of loss of consciousness after TBI.<sup>[18]</sup>

A paramount issue is that Amazon comprises a large territorial extent without homogeneously distributed health services and efficient transportation. Moreover, primary care may be flawed as many patients receive corticosteroids, not indicated for TBI patients.<sup>[4,6]</sup> In addition, patient transfers may take longer due to the lack of roads. Most are transferred to tertiary hospitals by plane or by speedboats, which is not accessible promptly (REF).<sup>[6]</sup> Conversely, lesions as the epidural hematoma are an emergency and may cause death within a few hours.

Manaus is the only city of the Amazonas state,<sup>[12]</sup> and Santarém is the only city of the west of Pará state with attending neurosurgeons. Then, as aforementioned, patients may die during transfer when the accident occurs far from these cities. Therefore, TBI prevention is a cornerstone when it comes to changing the epidemiological panorama. Daufanamae *et al.* (2016) made some valid recommendations such as training, recruiting, and retaining occupational therapists in the countryside. This simple solution becomes an ordeal when we consider the associated geographical location, transport costs, travel times, limited health professionals, and lack of opportunities for professional growth. Thus, the prevention plan ought to comprise financial and academic incentives in order to overcome such barriers.<sup>[7]</sup> Regarding children and workers' particular

susceptibility, Barss *et al.* (1984) recommend discouraging small children from playing near coconut trees to avoid injuries caused by falling coconuts, locating dwellings away from risk areas, and the using of safety helmets by those who enter on coconut plantations.<sup>[2]</sup> The same can be applied to ouriços falling prevention.

This case series has some limitations, mainly due to its retrospective nature, as the epidemiological data were not seldomly missing or incomplete. However, most critical clinical data were collected, and the CT scans could be reviewed from the digital records.

Implementation of public health measures is essential to prevent these accidents, such as encouraging personal protective equipment whenever collecting ouriços. Furthermore, family orientation programs in at-risk regions should be established. Finally, centers with a prepared team and head CT scans should be implemented in countryside cities, and rapid transportation to Manaus and Santarém should be guaranteed whenever necessary.

## CONCLUSION

These case series is the first to describe an unconventional but potentially fatal cause of TBI in the Amazon: the falling of the Brazil-nut fruit. Although most cases are considered “mild TBI,” patients may have cranial fractures and extradural hematomas, responsible for a significant morbimortality if proper medical assistance is delayed.

## Data availability

The patient history, radiology, and other imaging, ECG, histology and morphology, and other types of data used to support the findings of this study are available from the corresponding author on request.

## Declaration of patient consent

The authors certify that they have obtained all appropriate patient consent.

## Financial support and sponsorship

Nil.

## Conflicts of interest

There are no conflicts of interest.

## REFERENCES

1. Barss P, Dakulala P, Doolan M. Falls from trees and tree associated injuries in rural Melanesians. *Br Med J (Clin Res Ed)* 1984;289:1717-20.
2. Barss P. Injuries due to falling coconuts. *J Trauma* 1984;24:990-1.
3. Beez T, Steiger HJ, Etminan N. Pharmacological targeting of secondary brain damage following ischemic or hemorrhagic stroke, traumatic brain injury, and bacterial meningitis—a systematic review and meta-analysis. *BMC Neurol* 2017;17:209.
4. Bitencourt MA. Isotermas de Dessorção, Secagem e Caracterização Nutricional das Amêndoas das Castanha-do-Brasil da Região Amazônica. Brazil: Instituto Federal Goiano; 2020. Available from: <https://repositorio.ifgoiano.edu.br/handle/prefix/1248>. [Last accessed on 2019 Nov 15].
5. Campos MC, Venzel R, de Oliveira LP, Reis F, de Amorim RL. Management of traumatic brain injury at a medium complexity hospital in a remote area of Amazonas, 2017-2019. *World Neurosurg* 2021;148:e151-4.
6. Daufanamae BU, Franklin RC, Eagers J. Unintentional injury prevention and the role of occupational therapy in the Solomon Islands: An integrative review. *Rural Remote Health* 2016;16:3810.
7. Escoffery CT, Shirley SE. Fatal head trauma from tree related injuries. *Med Sci Law* 2001;41:298-300.
8. Fernandes RN, Silva M. Epidemiology of traumatic brain injury in Brazil. *Arq Bras Neurocir* 2013;32:136-42.
9. Gaudêncio TG, Leão GM. A epidemiologia do traumatismo crânio-encefálico: Um levantamento bibliográfico no Brasil. *Rev Neurocienc* 2013;21:427-34.
10. Grivna M, Eid HO, Abu-Zidan FM. Injuries from falling objects in the United Arab Emirates. *Int J Inj Contr Saf Promot* 2015;22:68-74.
11. Lopes NS. Avaliação Clínica e Terapêutica de Eventos Epilêpticos pós Trauma Cranioencefálico em Pacientes Acompanhados no Ambulatório Araújo Lima no Período de 2013 a 2014. Brazil: Federal University of Amazonas; 2014. Available from: <http://www.rii.ufam.edu.br/handle/prefix/4008>. [Last accessed on 2019 Nov 14].
12. Madeira MZ, Silva AM, Costa FF, Santos AM, Batista OM, Neto GA. Neurological trauma profile of traffic accident victims patients in a rehabilitation center. *Rev Enferm UFPI* 2018;6:22-7.
13. Martins ET, Linhares MN, Sousa DS, Schroeder HK, Meinerz J, Rigo LA, *et al.* Mortality in severe traumatic brain injury: A multivariate analysis of 748 Brazilian patients from Florianópolis city. *J Trauma* 2009;67:85-90.
14. Melo JR, da Silva RA, Moreira ED Jr. Characteristics of patients with head injury at Salvador city (Bahia--Brazil). *Arq Neuropsiquiatr* 2004;62:711-4.
15. Mulford JS, Oberli H, Tovosia S. Coconut palm-related injuries in the Pacific Islands. *ANZ J Surg* 2001;71:32-4.
16. Ommaya AK, Goldsmith W, Thibault L. Biomechanics and neuropathology of adult and paediatric head injury. *Br J Neurosurg* 2002;16:220-42.
17. Paiva WS, de Andrade AF, Mathias L Jr., de Paula Guirado VM, Amorim RL, Magrini NN, *et al.* Management of supratentorial epidural hematoma in children: Report on 49 patients. *Arq Neuropsiquiatr* 2010;68:888-92.
18. Radi A. Human Injury Model for Small Unmanned Aircraft Impacts, Technical Report. Australia: Civil Aviation Safety Authority; 2013.
19. Raymond D, Van Ee C, Crawford G, Bir C. Tolerance of the

- skull to blunt ballistic temporo-parietal impact. *J Biomech* 2009;42:2479-85.
20. Rede Amazônica. Agricultor Morre Após Ser Atingido Por Ouriço de Castanha, No Amazonas. G1 AM; 2012. Available from: <http://www.g1.globo.com/am/amazonas/noticia/2012/03/agricultor-morre-apos-ser-atingido-por-ourico-de-castanha-no-amazonas.html>. [Last accessed on 2019 Nov 14].
  21. Rede Amazônica. Criança Morre Após Ser Atingida Por Ouriço de Castanha no Interior do AM. G1 AM; 2016. Available from: <http://www.g1.globo.com/am/amazonas/noticia/2016/02/crianca-morre-apos-ser-atingida-por-ourico-de-castanha-no-interior-do-am.html>. [Last accessed on 2019 Nov 14].
  22. Rutland-Brown W, Langlois JA, Thomas KE, Xi YL. Incidence of traumatic brain injury in the United States, 2003. *J Head Trauma Rehabil* 2006;21:544-8.
  23. Santos-Silva L, Da Silva LC, Corassa JD, Battirola LD. The Brazil nut tree (*Bertholletia excelsa* Humb. and Bonpl. (*Lecythidaceae*): Importance and biological interactions. *Sci Electron Arch* 2017;10:71-84.
  24. Taylor CA, Bell JM, Breiding MJ, Xu L. Traumatic brain injury-related emergency department visits, hospitalizations, and deaths-United States, 2007 and 2013. *MMWR Surveill Summ* 2017;66:1-16.
  25. Yang J. Brazil nuts and associated health benefits: A review. *LWT Food Sci Technol* 2009;42:1573-80.
  26. Zuidema PA. Demography and Management of the Nut Tree (*Bertholletia excelsa*), PROMAB (Programa Manejo de Bosques de la Amazonía Boliviana), Scientific Series 6, Riberalta, Bolivia. United Kingdom: Cambridge University Press; 2003. p. 113.

**How to cite this article:** Ideta MM, Oliveira LM, de Castro GL, Santos MA, Simões EL, Gonçalves DB, et al. Traumatic brain injury caused by Brazil-nut fruit in the Amazon: A case series. *Surg Neurol Int* 2021;12:399.