



Transfer of the Long Head Biceps Tendon to Conjoined Tendon in Proximal Humerus Fractures with Cleavage or Comminution at the Bicipital Groove

Omid Reza Momenzadeh^{1*}, Seyed Amirreza Mesbahi¹, Fatemeh Sadat Azimi¹, Mohsen Mardani-Kivi²

¹Bone and Joint Diseases Research Center, Shiraz University of Medical Sciences, Shiraz, Iran

²Clinical Research and Development Center, Department of Orthopedics, Ghaem Int. Hospital, Guilan University of Medical Science, Rasht, Iran

*Corresponding author: Omid Reza Momenzadeh

Address: Assistant Professor of Orthopaedics, Bone and Joint Diseases Research Center, Shiraz University of Medical Sciences, Shiraz, Iran. P.O. Box: 4193713191.
Tel: +98-71-36246093; Cellphone: +98-917-714-0512.
e-mail: momenzadeh.o@gmail.com

Received: August 2, 2021

Revised: March 16, 2022

Accepted: April 16, 2022

► ABSTRACT

Objective: To evaluate the clinical and radiographic findings of long head biceps tendon (LHBT) transfer in traumatic proximal humeral fractures with the biceps groove breakage or comminution.

Methods: In this interventional study, subjects surveyed in terms of shoulder function, clinical signs of LHBT tendinitis, radiographic signs of transferred biceps as a possible depressor of the shoulder, and mechanical changes of the scapula. Data were analyzed in SPSS version 21.

Results: Fifteen patients were included in the case group (tendon transfer to the conjoined tendon), and 10 patients were evaluated in the control group (non-transfer or non-manipulation of the exposed tendon in the fracture callus of biceps groove). The mean age of the study population was 46.56±14.31 years, and the majority of patients (14.56%) were men. The differences between two groups were not significant in terms of the American Society of Shoulder and Elbow Surgeons (ASES) score, University of California at Los Angeles (UCLA) score, and constant shoulder score (CSS) ($p=0.535$, $p=0.419$, and $p=0.266$, respectively). Also, there was no significant differences between the case and control groups regarding the biceps muscle involvement (Popeye sign: $p=1.00$; tenderness: $p=0.477$; pain: $p=1.00$; speed test: $p=1.00$; Yergason's test: $p=1.00$).

Conclusion: LHBT transfer to the conjoined tendon in proximal humerus fractures with cleavage or comminution at the bicipital groove showed no advantages.

Keywords: Biceps tendon; Proximal; Humerus; Fractures; Tenodesis

Please cite this paper as:

Momenzadeh OR, Mesbahi SAR, Azimi FS, Mardani-Kivi M. Transfer of the Long Head Biceps Tendon to Conjoined Tendon in Proximal Humerus Fractures with Cleavage or Comminution at the Bicipital Groove. *Bull Emerg Trauma*. 2022;10(3):116-121. doi: 10.30476/BEAT.2022.91063.1268.

Introduction

Considering the high prevalence of pathologies in the long head of the biceps tendon (LHBT)

and the associated pain and movement restrictions, LHBT treatment is one of the major issues in shoulder surgeries [1]. LHBT pathologies may be isolated (e.g., primary tendonitis) or associated with damage

to other parts of the shoulder joint (e.g., rotator cuff tears or other bone fractures) [2]. There are several therapeutic strategies for different LHBT injuries such as tenotomy and tenodesis with arthroscopic and open approaches. Generally, the final treatment decision is made by the surgeon with regard to the comorbid pathologies and the patient's condition [3].

Meanwhile, tendon transfer is one of the methods used to transfer LHBT to the conjoined tendon [4]. Tendon transfer has been evaluated in previous studies which is applied during elective arthroscopy for chronic inflammation [4-6]. Nevertheless, it is not known whether this approach can be an effective emergency approach for proximal humerus fractures, which are among the most common fractures in the shoulder girdle especially when the fracture reaches the bicipital groove [5]. Comminuted proximal humerus fractures are seldom accompanied by the fracture of the intertubercular sulcus (bicipital groove). It is greater tuberosity that detached from the lesser tuberosity lateral to the biceps groove; and a small portion of the anterior greater tuberosity with the groove itself are attached to the lesser tuberosity fragment. Therefore, LHBT would have a smooth bony bed after fracture healing in many proximal humerus fractures. On the other hand, we can infrequently observe the biceps groove direct breakage or comminution and separation of the lesser and greater tuberosities exactly at the bicipital groove. In this rare cases, one of the advantages of the tendon transfer approach is the removal of LHBT away from this site [6]. Because LHBT may be inflamed or damaged during or after fracture repair due to callus formation in the sulcus.

In addition, it has been suggested that the risk of postoperative pain in the shoulder may be reduced with the transfer of tendon and displacement of LHBT [4-6]. It was also noted that tendon transfer may result in mechanical disturbances after biceps surgery with changing the natural location of LHBT [6]. As contradictory findings have been reported in this area, we performed this study to determine which strategies can produce the best therapeutic outcomes in the emergency management of LHBT pathologies. In this study, we aimed to evaluate the clinical and radiographic results in the transfer or non-manipulation of LHBT in patients with proximal humeral fractures, extended or comminuted exactly to the bicipital groove.

Materials and Methods

This retrospective, case-control study included all patients admitted to our hospitals during 2012-2015. The subjects were diagnosed with proximal humerus fractures, extending into the bicipital groove and underwent open reduction internal fixation (ORIF) surgery.

The exclusion criteria were: 1) proximal humerus fractures without cleavage or comminution at the bicipital groove; 2) proximal humerus fractures treated

via closed reduction; 3) fractures in the ipsilateral or contralateral limb; and 4) diagnosis of non-union or malunion of proximal humerus fractures.

Due to time restrictions and availability of medical information, all patients were analyzed and there was no need for a specific sampling method. The participants were classified into two groups: case group (tendon transfer to the conjoined tendon) and control group (non-transfer or non-manipulation of the exposed tendon in the fracture callus).

We reviewed a total of 104 computed tomography (CT) scans in this study. Of which, 40 who had CT finding of cleavage at the biceps groove were selected and evaluated. However, one patient died before the evaluation, one patient underwent total arthroplasty, and one patient was excluded because of heterotopic ossification. Also, three patients had associated fractures (one with an ipsilateral shaft humerus fracture, one with a contralateral acromioclavicular joint fracture, and one with an ipsilateral elbow fracture). Nine patients were not willing to continue participation in the study or were unavailable. Finally, based on the inclusion and exclusion criteria, a total of 25 patients were reviewed in our study (15 patients were in the case group and ten patients in the control group) (Figure 1). They had proximal humerus fractures with cleavage or fracture at the biceps groove (Figure 2 and 3), and were treated randomly after fracture fixation with (cases) or without (controls) long head biceps tendon to coracoid transfer. Two medical examiners performed all the clinical examinations and measurements. The examiners were unaware of patient's classification (case or control group); therefore, this study was a single blind trial.

The groups were surveyed in terms of shoulder function, biceps muscle involvement, radiographic signs of transferred biceps, and scapular dyskinesis. To evaluate shoulder function, the constant shoulder score (CSS), American Society of Shoulder and Elbow Surgeons (ASES) score, and University of California at Los Angeles (UCLA) score were measured. Also, to evaluate the biceps muscle involvement, pain in the biceps area, tenderness in the bicipital groove, speed test, Yergason's test, and Popeye sign were evaluated.

Furthermore, radiographic signs of transferred biceps as a possible depressor of the shoulder were evaluated in this study. Bilateral X-ray was performed at a true shoulder anteroposterior (AP) view to compare the limbs and measure the proximal migration of the humeral head (distance between the top of the humerus bone and inferior border of the acromion). In addition, scapular dyskinesis was determined based on the Kibler classification and observation of both scapulae. For this purpose, the patient was placed in an upright position with arms resting at sides. Next, the arms were simultaneously elevated in the plane of the scapula while observing the scapular motion. It should be noted that

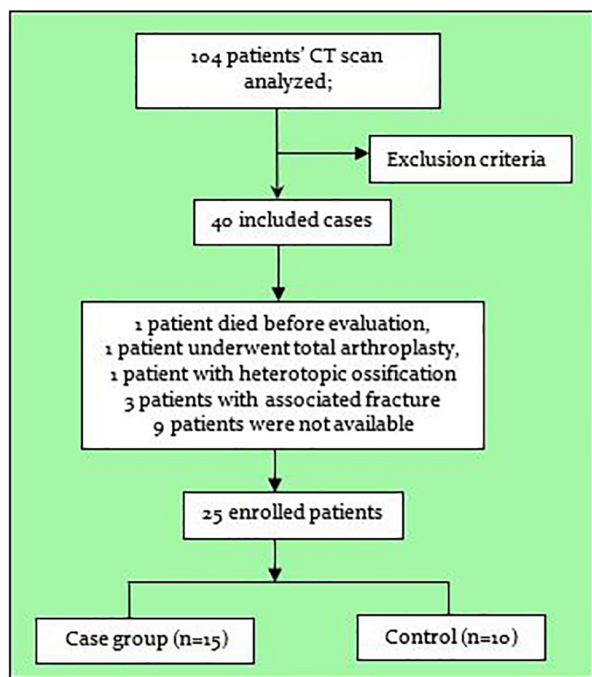


Fig. 1. Enrolled patients according to CT.

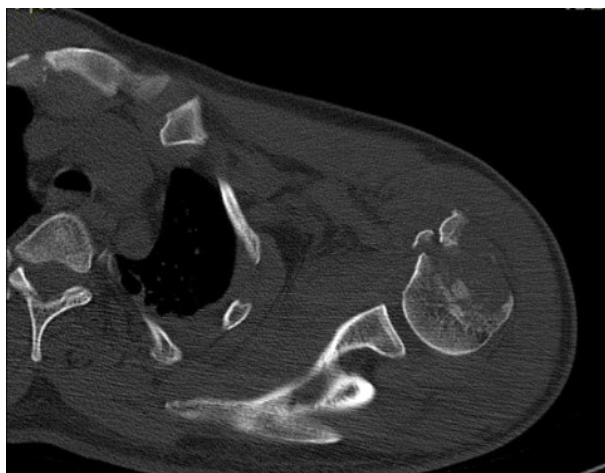


Fig. 3. Preoperative computed tomography (CT) scan of the injured shoulder of a patient from the case group.

observation of the scapula in the resting position might be adequate.

Surgical Techniques

In the case group, the patients underwent general anesthesia after preoperative preparation and surgical draping. They were placed in a semi-setting position and the roof of the bicipital groove was opened via deltopectoral incisions. Next, the bicipital tendon was cut at 2 cm above the superior edge of the pectoralis major and transferred to the lateral edge of the conjoint tendon, based on the soft tissue side-to-side transfer method. After the fracture was reduced, it was fixed to locking compression plate (LCP) proximal humerus plates (Figure 4). On the other hand, all the steps in the control group except for tendon transfer were similar to the case group and internal fixation was carried out via deltopectoral incisions.

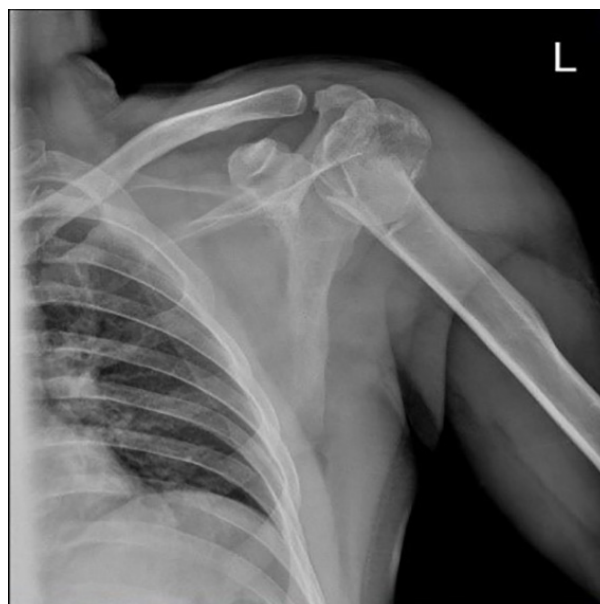

Fig. 2. Preoperative X-ray of the injured shoulder of a patient from the case group.

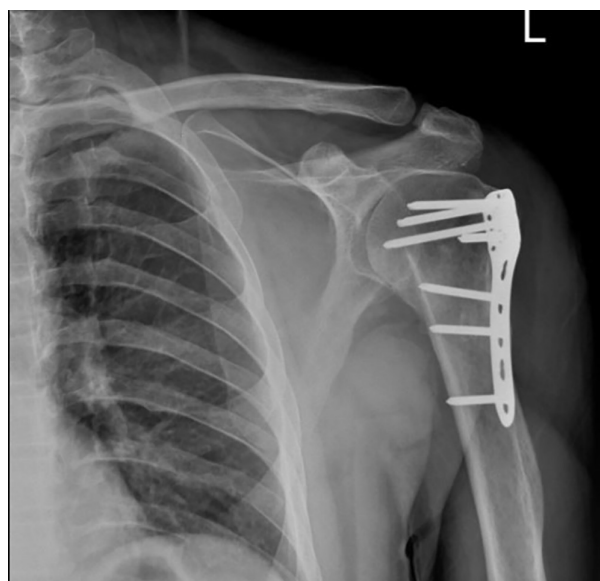

Fig. 4. Postoperative X-ray of a patient from the case group.

Statistical Analysis

The ranked data are presented as percentage and frequency and numerical data as mean±SD. Statistical tests such as Chi-square test, Mann-Whitney test, Kappa statistic, and intraclass correlation coefficient test were used to compare the collected data. The level of significance was set at 0.05 in all tests.

Results

A total of 25 patients were reviewed in our survey (15 patients in the case group and 10 patients in the control group). The findings showed that 14 patients (56%) were men, and 11 patients (44%) were women with the mean age of 46.56±14.31 years (minimum=21 and maximum=66). The baseline characteristics (i.e., age, sex, side of injury, and segmental fractures) showed no significant differences between the two groups. The fracture was on the right side in 8

patients (32%) and on the left side in 17 patients (68%). Based on the Neer classification system, 10 patients (40%) had three-part proximal humerus fractures, while 15 patients (60%) had four-part proximal humerus fractures.

Table 1 presents a summary of the biceps assessment results in the patients. According to the findings, only one patient had a Popeye sign. Tenderness was more common in the control group and was significantly different from the case group. In addition, pain was reported in 7 patients, and abnormal Yergason's test results were reported in 6 patients. The findings did not show any major disagreement between the two examiners.

There was no significant difference regarding the biceps muscle involvement between the case and control groups (Popeye sign: $p=1.00$; tenderness: $p=0.477$; pain: $p=1.00$; speed test: $p=1.00$; Yergason's test: $p=1.00$). Therefore, tendon transfer did not exert any significant effects on the bicipital muscle involvement in the case group. On the other hand, tenderness and pain, along with abnormal Yergason's

and speed tests results were scarcely higher in the case group; however, the differences between the case and control groups regarding these parameters was not significant ($p>0.05$).

Table 2 presents the radiological and scapular evaluations results. The findings showed that 8% of patients had scapular type I dyskinesia, while 8% had scapular type II dyskinesia. The mean acromiohumeral distance (AHD) between the humerus head and the lower border of the acromion was significantly different between the two groups (shorter in the case group). In other words, the humerus head had elevated in the case group and the level of pain was high (Table 2).

Comparison of proximal migration radiographic measurements in the case and control groups with the reference (distance= 6 mm) showed no significant differences (> 6 mm in each group), and proximal migration was not observed in the control or case group. Table 3 presents the mean scores of the scales used in this study to evaluate the shoulder function among patients.

Table 1. Evaluations of the biceps muscle involvement in the participants.

	Groups	First examiner	<i>p</i> -value	Second examiner	<i>p</i> -value
Popeye sign, n (%)	Case	1 (4%)	NS ^a	1 (4%)	NS ^a
	Control	0 (0%)		0 (0%)	
Tenderness, n (%)	Case	8 (53.3%)	0.477	8 (80%)	0.542
	Control	7 (70%)		10 (66.7%)	
Pain, n (%)	Case	4 (28.6 %)	NS ^a	4 (28.6%)	NS ^a
	Control	3 (30%)		3 (30%)	
Abnormal Yergason's test, n (%)	Case	4 (26.7 %)	NS ^a	4 (26.7 %)	NS ^a
	Control	2 (20%)		2 (20%)	
Abnormal speed test, n (%)	Case	3 (20%)	NS ^a	5 (33.3%)	NS ^a
	Control	2 (20%)		3 (30%)	

^aNS: $p>0.05$.

Table 2. Radiological evaluation and scapular examination of the participants.

	Groups	First examiner	<i>p</i> -value	Second examiner	<i>p</i> -value
AHD difference between normal and injured shoulders Mean (SD ^a)	Case	0.08 (2.44)	0.824	0.22±2.49	NS ^b
	Control	-0.16 (2.59)		-0.32±2.63	
Scapular dyskinesia, n (%)	Case	1 (6.7%)	NS	2 (20%)	NS ^b
	Type I	1 (6.7%)		1 (10%)	
	Type II	----		----	
	Type III	Control		1 (10%)	
		1 (10%)		2 (13.3%)	
		----		----	

^aSD: Standard Deviation; ^bNS: $p>0.05$.

Table 3. The scores of the participants.

Parameters	Case group	Control group	<i>p</i> -value
ASES score			
Mean (SD)	71.77 (29.24)	65.32 (25.97)	0.535
Min-Max	26.67-100	28.33-100	
UCLA score			
Mean (SD)	26.73 (8.19)	23.90 (9.01)	0.419
Min-Max	12-35	9-35	
CSS score			
Mean (SD)	78.46 (19.34)	67.60 (22.81)	0.266
Min-Max	42-100	34-98	

Discussion

The present study aimed to compare the outcomes of two methods in tendon transfer surgery and non-manipulation of LHBT in patients with proximal humerus fractures extending to the bicipital groove. Our findings showed that the outcomes of two methods were not significantly different in terms of examination and function results. Also, pain and function assessment indicated similar outcomes in the groups.

So far, the main role of LHBT has not been clearly identified [3]. Some scholars have suggested that this tendon plays an important role in shoulder stability while others have refuted its involvement. Despite some apparently contradictory findings, there is a strong agreement that this tendon plays an important role in the anterior shoulder pain and its pathologies range from isolated tendonitis to bicipital tendinitis, partial or complete tears, and subluxation. It is claimed that the main reason for the high potential of this tendon for inflammation is the presence of the synovial sheath and its passage through the bicipital groove [5-7].

In patients with LHBT tendonitis, surgical treatment is used if supportive treatment is not successful. The common surgical treatments for this condition includes tenotomy, tenodesis and tendon transfer. It is claimed that tenotomy is a suitable approach when the individual suffers from severe localized pain. Overall, this simple method, which is associated with low morbidity, lack of complications due to additional hardware, short surgery time, and short recovery is considered an appropriate treatment strategy.

On the other hand, in a recent survey conducted in 2018, most American shoulder surgeons preferred tenodesis to tenotomy [8]. The primary reason for their preference was that following tenotomy, the supination strength and flexor of the elbow decrease and cause fatigue and discomfort in patients. Also, tenotomy is associated with a higher risk of muscle cramp and cosmetic deformity following treatment. The causes of this deformity in tenotomy include the Popeye sign and occurrence of auto-tenodesis following surgery in the bicipital groove.

In addition, LHBT tenodesis requires specific methods. This surgery can be performed using the arthroscopic, mini-open, or open strategies with two major approaches, i.e., suprapectoral and subpectoral. Advocates of the open subpectoral approach believe that the risk of residual tenosynovitis reduces in this method due to the complete removal of LHBT from the bicipital groove [9]. Also, another technique, called the "slit technique", has been introduced, in which LHBT is fixed to the conjoined tendon using arthroscopic approaches, exposing the entire bicipital groove. Advocates of this technique believe that it provides a more normal axis for the biceps muscles compared to conventional tenodesis [10].

Tendon transfer of LHBT was first introduced in 1926 by Gilcreest [11] for patients with chronic and

painful biceps inflammation. Subsequently, this method was applied using elective arthroscopy in case of LHBT involvement. However, to the best of our knowledge, no other study has evaluated this therapeutic approach in traumatic patients. Also, there is no study comparing the routine technique with tendon transfer in patients with proximal fractures of the arm.

Evidence suggests that fracture repair involves a stage of callus formation. It is said that callus formation in the bicipital sulcus causes LHBT tendonitis in patients with proximal humerus fractures. In addition, the risk of postoperative pain in the anterior shoulder may be reduced with tendon transfer and LHBT displacement [4-6]. In a ten-years follow-up study, Taylor *et al.*, [12] examined the outcomes of arthroscopic tendon transfer in patients with tendinitis or chronic inflammation of LHBT. The results showed that subdeltoid transfer is a reliable method for patients with chronic and resistant pathologies to LHBT treatment. Contrary to these findings, the present study did not confirm the superiority of the case group in terms of shoulder function.

According to the scapular dyskinesis examination, tendon transfer did not cause any significant changes in the clinical outcomes of patients, although dyskinesis occurred following the change of tendon anatomy in the bicipital groove. The measurements in this study showed that statistically significant proximal migration did not occur in any of the patients. Although our findings are not statistically significant, clinical experience suggests that proximal migration occurs by removing the depressor effect of the bicipital muscle.

Moreover, in an autopsy study, Pastor *et al.*, [13] compared LHBT tendon transfer to the conjoined tendon with suprapectoral tenodesis and found similar biomechanical outcomes in patients after surgery. It has been also suggested that tendon transfer may cause mechanical disturbances in the biceps function by changing the natural location of LHBT [6]. However, this intervening effect was only observed in our patients in relation to shoulder pain and there was no significant difference between the two groups regarding other parameters.

Evidence suggests that the tendon transfer technique is effective in maintaining the coracoacromial arch and creating a sling for enhancing the anterior shoulder function; however, this hypothesis has not been confirmed. Additionally, Ahren *et al.*, [14] stated that in case of Neer three- and four-segment proximal humerus fractures or posterior position of the initial fracture line, the bicipital groove may be damaged and subsequently, LHBT involvement may occur. Therefore, a proper treatment strategy should be applied in these fractures.

Our findings did not show any significant difference in the clinical and functional outcomes of LHBT tendon transfer to the conjoined tendon in proximal humerus fractures with cleavage or comminution

to the bicipital groove. Based on the present study results, the biceps muscle involvement in the case group was scarcely more significant than the control group; therefore, tendon transfer is not suggested as an appropriate intervention for these patients. Further investigations are needed on a larger sample size in order to determine the accurate advantages and disadvantages of tendon transfer.

One of the strengths of this study is that only one orthopedic surgeon with at least five years of experience in shoulder surgeries performed all surgeries for the patients. One of the limitations of this study is that patients were examined retrospectively and the results of tests could not be compared with the preoperative stage. Also, a small sample size was recruited in this study. Therefore, it is recommended to conduct similar retrospective studies on a larger sample size for a more accurate analysis.

Declaration

Ethics approval and consent to participate:

References

- Krupp RJ, Kevern MA, Gaines MD, Kotara S, Singleton SB. Long head of the biceps tendon pain: differential diagnosis and treatment. *J Orthop Sports Phys Ther.* 2009;**39**(2):55-70.
- Gilmer BB, Lang SD, Guttman D. Long Head of the Biceps Tendon Complex: Pathology and Treatment Approach. *Textbook of Shoulder Surgery*: Springer; 2019. p. 157-72.
- Lewis RB, Reyes BA, Khazzam MS. A review of recent advances in the diagnosis and treatment modalities for long head of bicep tendinopathy. *Clinical Medicine Insights: Trauma and Intensive Medicine.* 2016;**7**:CMTIM. S39404.
- Sandesh Madi S, Pandey¹ V, Acharya¹ K, Mane¹ P. Long Head of Biceps Tendon: Current Concepts and Controversies. *Journal of Karnataka Orthopaedic Association.* 2018;**6**(2):3-6.
- Franceschi F, Verde LL. Biceps Transfer to the Conjoint Tendon. *Rotator Cuff Across the Life Span*: Springer; 2019. p. 231-40.
- AlQahtani SM, Bicknell RT. Outcomes following long head of biceps tendon tenodesis. *Curr Rev Musculoskelet Med.* 2016;**9**(4):378-387.
- Kwisda S, Flury M. Biceps Disorders: When and How to Operate. *Management of Failed Shoulder Surgery*: Springer; 2018. p. 73-84.
- Corpus KT, Garcia GH, Liu JN, Dines DM, O'Brien SJ, Dines JS, et al. Long Head of Biceps Tendon Management: a Survey of the American Shoulder and Elbow Surgeons. *HSS J.* 2018;**14**(1):34-40.
- Gombera MM, Kahlenberg CA, Nair R, Saltzman MD, Terry MA. All-arthroscopic suprapectoral versus open subpectoral tenodesis of the long head of the biceps brachii. *Am J Sports Med.* 2015;**43**(5):1077-83.
- Mazoch MJ, Frevert WF, Field LD. Identifying and Exposing the Proximal Biceps in Its Groove: The "Slit" Technique. *Arthrosc Tech.* 2017;**6**(4):e1285-e1290.
- Gilcreest EL. Two cases of spontaneous rupture of the long head of the biceps flexor cubiti. *Surg Clin North Am.* 1926;**6**:539-54.
- Taylor S, Baret NJ, Newman A, Delos D, Drakos M, Copple ZM, et al. Arthroscopic Transfer of the Long Head of the Biceps Tendon: 2-10 Year Functional Outcome and Clinical Results. *Orthopaedic Journal of Sports Medicine.* 2013;**1**(4_suppl):2325967113S00090.
- Pastor MF, Kraemer M, Hurschler C, Claassen L, Wellmann M, Smith T. Transfer of the long head of biceps to the conjoint tendon. A biomechanical study. *Clin Biomech (Bristol, Avon).* 2016;**32**:80-4.
- Ahrens PM, Boileau P. The long head of biceps and associated tendinopathy. *J Bone Joint Surg Br.* 2007;**89**(8):1001-9.

The current research was approved by the ethics committee of Shiraz University of Medical Sciences (IR.SUMS.REC.1394.S1008).

Consent for publication: Not applicable.

Conflict of interests: The authors declare that they have no conflict of interest.

Funding: All named authors, their immediate family, and any research foundation with which they are affiliated did not receive any financial payments or other benefits from any commercial entity related to the subject of this article.

Authors' contributions: ORM: Data collection; ORM, FA, SAM: Draft; ORM, MM: Analysis.

Acknowledgements: The authors express their gratitude to Dr. Zahra Haghparast Ghadim Limudahi for critical reading of the manuscript and his insightful suggestions.

Open Access License

All articles published by Bulletin of Emergency And Trauma are fully open access: immediately freely available to read, download and share. Bulletin of Emergency And Trauma articles are published under a Creative Commons license (CC-BY-NC).