

## Non-surgical treatment of primary female urethral cancer

Bruce Libby,<sup>1</sup> David Chao,<sup>2</sup>  
Bernard F. Schneider<sup>1</sup>

<sup>1</sup>Department of Radiation Oncology,  
<sup>2</sup>School of Medicine, University of  
Virginia, Charlottesville VA, USA

### Abstract

Primary carcinomas of the female urethra are extremely rare, with an annual incidence of less than ten in one million. Currently, there is no consensus regarding management of this malignancy. However, there have been several case reports demonstrating the efficacy of chemoradiation in the treatment of female urethral cancer. In this report we present two cases of female primary urethral adenocarcinoma that were treated by concomitant chemotherapy and external beam radiotherapy, followed by interstitial brachytherapy.

### Introduction

Primary carcinomas of the female urethra are extremely rare, and because most present at an advanced stage the overall prognosis is poor.<sup>1</sup> Owing to the rarity of this disease, there is no consensus on the management of primary female urethral cancer.<sup>2,7</sup> Managed with surgery alone, five-year disease-free survival is only 20-30%. Radiotherapy and chemotherapy have been advocated in combination with surgery to improve treatment outcomes.<sup>2,15</sup>

Several studies have shown that interstitial brachytherapy is an effective modality, used alone or in combination with other treatments.<sup>5,15-17</sup> In a study of 34 women with primary urethral cancer, Milosevic *et al.* found that adding interstitial brachytherapy to external beam radiation reduced the risk of local recurrence by a factor of 4.2.<sup>5</sup> Foens *et al.* treated 28 cases of female primary urethral cancer and found that the three-year disease-free survival rates were 29% for those treated with external beam radiation alone, and 57% for those treated with combined external and interstitial radiotherapy.<sup>16</sup> The addition of chemosensitization, for example, cisplatin, to the radiation therapy regimen is also thought to increase local control and survival.<sup>2,18</sup>

In this case report, we describe two cases of female primary urethral adenocarcinoma that have been managed successfully with external beam radiation and concomitant chemotherapy (cisplatin and capecitabine) followed by interstitial brachytherapy.

## Materials and Methods

### Case #1

A 53-year-old white female presented with progressive dysuria, hematuria, and ultimately urinary retention. On physical examination she had a 4-cm peri-urethral mass. Cystoscopy revealed a urethral tumor involving the entire length of the urethra with extension into, but not invading, the bladder. The biopsy was consistent with a well-to-moderately differentiated adenocarcinoma. T2-weighted magnetic resonance imaging (MRI) demonstrated a mildly hyperintense 7.2×3.0×2.8-cm fungating mass in the proximal urethra with invasion of the anterior wall of the distal vagina. The tumor was staged as stage II (cT2N0M0). Transurethral resection of a small intravesical portion of the tumor was performed. The patient then received external beam radiation therapy with concomitant cisplatin (40 mg/m<sup>2</sup> weekly) and capecitabine (500 mg twice daily, 5 days/week). The whole pelvis received 30 Gy delivered in 15 fractions, followed by an additional 20 Gy delivered in 10 fractions to the lower pelvis. Therapy was given with AP/PA fields using 6 and 15 MV photons on a Varian 2300 linear accelerator. Custom blocks were used to spare normal tissues. The patient tolerated the therapy well, with only mild diarrhea and perineal dermatitis as side-effects.

Approximately two weeks after external beam radiation therapy was completed, interstitial low-dose rate (LDR) brachytherapy was performed using transrectal ultrasound and fluoroscopic guidance. Five interstitial catheters were loaded approximately 1-cm apart with 32 <sup>192</sup>Ir sources. A 2-cm diameter vaginal cylinder was placed in the vaginal vault, which was loaded with three 5-mg radium equivalent <sup>137</sup>Cs sources. The brachytherapy dose was 25 Gy prescribed in addition to the 60 cGy per hour isodose line. Treatment planning was performed on the ROCS planning system, using orthogonal X-ray films. The patient tolerated therapy well, with only dyspareunia as a side-effect. At completion of therapy she had normal urinary voiding function and urinary continence.

Sixteen months later, the patient presented with headache, dizziness, and diplopia. MRI of the brain revealed a heterogeneously enhancing 2.0×2.7×2.7-cm mass in the cerebellum. The biopsy was consistent with metastatic adenocarcinoma, and appeared histologically similar to her urethral tumor. The cerebellar tumor was neurosurgically resected. Postoperative external beam radiation therapy was delivered to the posterior fossa to a prescribed dose of 30 Gy in 10 fractions using 6 MV photons with opposed lateral fields. The patient tolerated therapy well. A follow-up MRI of the brain 15 months after the surgery and

Correspondence: Bruce Libby, P.O. Box 800375,  
School of Medicine, University of Virginia,  
Charlottesville VA, 22908 USA.  
E-mail: bl8b@virginia.edu

Key words: urethral cancer, high-dose rate, low-dose rate.

Contributions: BL, compilation of the data and figures, writing and editing the manuscript; DC, compiling the references, writing the background, contributing to the entire manuscript; BS, compiling the case data, writing and editing the manuscript.

Conflict of interest: the authors report no conflicts of interest.

Received for publication: 1 June 2010.  
Accepted for publication: 19 August 2010.

This work is licensed under a Creative Commons Attribution 3.0 License (by-nc 3.0).

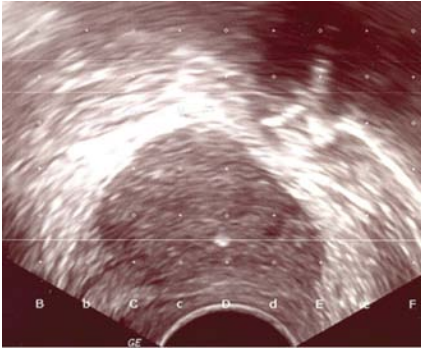
©Copyright B. Libby *et al.*, 2010  
Licensee PAGEPress, Italy  
Rare Tumors 2010; 2:e55  
doi:10.4081/rt.2010.e55

radiotherapy showed no recurrence of disease. A follow-up pelvic examination showed no evidence of recurrent disease three years following chemoradiation.

### Case #2

A 67-year-old white female presented with recurrent urinary tract infections (UTIs) and urinary retention. On examination, she had a 4-cm peri-urethral mass; the biopsy showed a poorly differentiated adenocarcinoma. MRI of the pelvis revealed an enhancing 4.1×3.5×4.1-cm peri-urethral mass with possible involvement of the inferior bladder. The tumor was staged as a stage II (cT2N0M0) adenocarcinoma of the urethra. The patient received external beam radiation therapy with concomitant cisplatin (40 mg/m<sup>2</sup> weekly) and capecitabine (500 mg twice daily, 5 days/week). A prescribed dose of 46 Gy was delivered in 23 fractions to the tumor, as well as to inguinal and pelvic lymph nodes. Therapy was given with AP/PA fields using 6 and 15 MV photons on a Varian 2300 linear accelerator. Custom blocks were used to spare normal tissues. The patient tolerated external beam therapy well, with only diarrhea, urge incontinence, and superficial ulcerative moist desquamation of the inguinal folds as side-effects. At completion of therapy she had normal urinary voiding function and urinary continence.

Approximately four weeks after external beam radiation was completed, interstitial high-dose rate (HDR) brachytherapy was performed using transvaginal ultrasound with a perineal template for needle guidance (Figure



**Figure 1.** Transverse ultrasound image of the tumor for case #2.

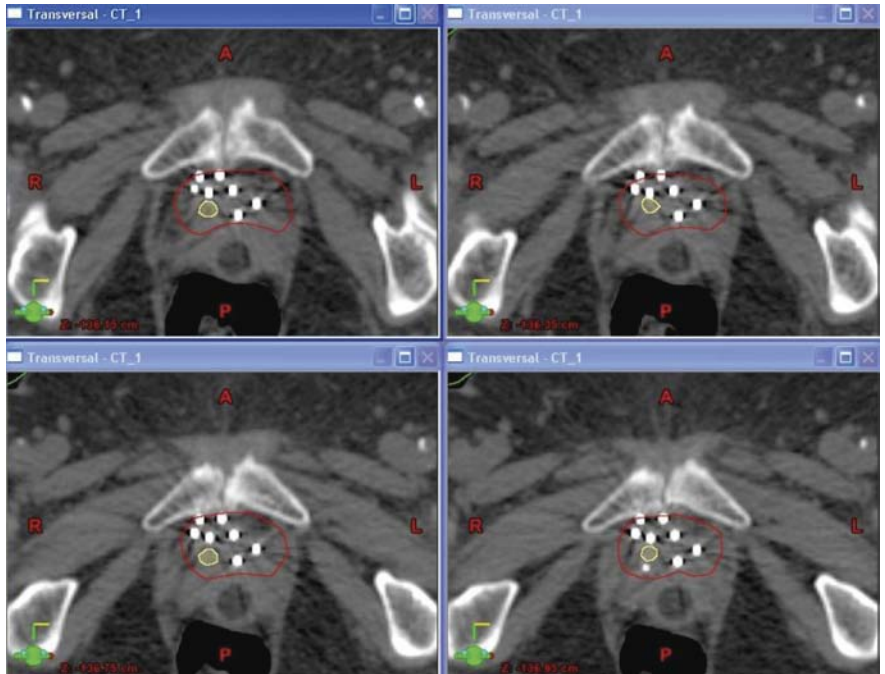
1). Seven interstitial brachytherapy flexi-needles were placed in the tumor. A treatment planning CT of the pelvis was then performed, and the CT images were transferred to the treatment planning system (Brachyvision 7.1, Varian Inc, Sunnyvale CA). The tumor and urethra were contoured, and the indwelling times in each catheter were adjusted manually to deliver an optimized dose of 5 Gy/fraction to the tumor, for a total of 20 Gy (Figures 2 and 3), given over three days.

After interstitial HDR treatments had been completed, the template was removed (with the needles kept in place) so that an MRI could be performed. The MR images were transferred to the treatment planning system and fused with the treatment planning CT images, using the needle locations as the registration points. The tumor was more easily visualized on the MRI data set than on the CT data set. The tumor and urethra were contoured on the MR image set for comparison with those structures on the CT image set (Figure 4).

The fused images showed that the tumor was adequately treated. A follow-up MRI, performed three months after the brachytherapy treatment, showed no residual tumor mass. Fourteen months after treatment, the patient has no evidence of disease recurrence, radiographically or on a physical examination.

## Results and Discussion

Primary urethral cancer is rare, comprising less than 1% of all malignancies.<sup>4</sup> A recent review of the National Cancer Institute Surveillance, Epidemiology, and End Results database showed that 1,075 men and 540 women were diagnosed with primary urethral cancer in the United States from 1973 to 2002, the major histological types being transitional cell carcinoma (55%), squamous cell carcinoma (21.5%), and adenocarcinoma (16.4%).<sup>1</sup> The histology of the neoplasm, however, does not seem to affect prognosis.<sup>2,4,5</sup>

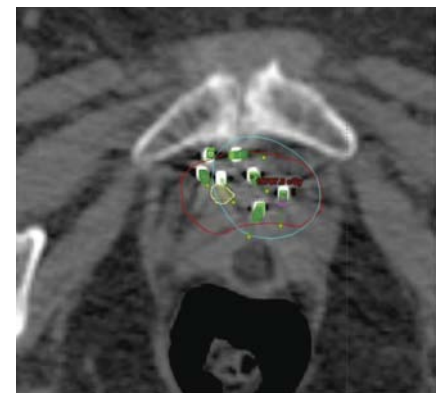


**Figure 2.** Computer tomography images of the tumor (red contour) and urethra (yellow contour) along with the interstitial needles for case # 2.

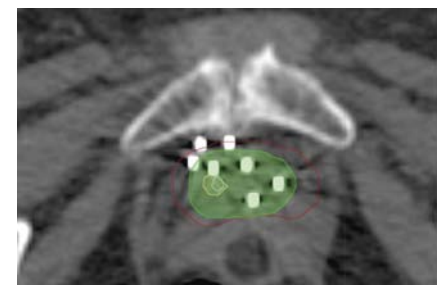
Multiple factors have been correlated with the outcome in women with urethral cancer. This is well illustrated in a series of 72 women treated at Memorial Sloan-Kettering over a period of 36 years.<sup>12</sup> In this study, multivariate analysis showed that the stage of the primary tumor, the presence or absence of regional lymph node involvement, and the site of disease (proximal versus distal urethra) were all independent risk factors for survival. For example, patients with tumors  $\leq 2$  cm in size in the distal urethra had a 60% five-year survival rate, while those with lesions  $>4$  cm in size in the proximal urethra had a five-year survival rate of only 13%. Others have also demonstrated that small, distal tumors have relatively good prognoses, whereas larger, proximal tumors carry relatively poor prognoses.<sup>2-14</sup> Overall prognosis, however, remains relatively poor, with a five-year overall survival rate of approximately 35-45%.<sup>2,5</sup>

Multiple small case studies have suggested that single modality treatment (surgery or radiation therapy) is effective for small, distal tumors; on the other hand, multimodal treatment has been recommended for larger and more proximal tumors.<sup>3-5,7,8,15</sup> Other case reports have suggested that brachytherapy is an effective component of multimodality treatment of primary urethral cancer.<sup>5,8,16,17</sup> Our case report corroborates the assertion that larger, proximal tumors may be effectively treated with chemoradiotherapy, and that interstitial brachytherapy appears to be a significant component of this treatment approach.

The use of advanced imaging technologies, including transvaginal ultrasound to guide the



**Figure 3.** Computer tomography images of the tumor with the 5 Gy isodose line (blue) for case #2.



**Figure 4.** Contours from the fused computer tomography and magnetic resonance images for Case #2. The magnetic resonance tumor volume is in green, the computed tomography tumor volume is in red, the magnetic resonance urethra is in blue, the computed tomography urethra is in yellow.

placement of interstitial needles along with MRI and CT scans, allows for improved diagnosis and treatment of urethral cancer.<sup>19,25</sup> Further advancement of the treatment planning can be made by the utilization of ultrasound-based planning (Vitesse, Varian). Vitesse allows the capture of ultrasound data and its conversion to DICOM RT, which can then be exported to the BrachyVision treatment planning system. The use of ultrasound in planning would shorten the work flow by eliminating the need for a CT scan, and would also provide excellent imaging of the tumor along with the implanted needles.

## Conclusions

There are no consensus recommendations for the treatment of primary female urethral cancer owing to the rarity of this disease and the paucity of information in the literature. As such, the reporting of all cases of primary urethral cancer is necessary to better determine optimal management. Many authors have suggested a combination of surgery, chemosensitization, and radiation therapy. This case report supports the assertion that interstitial brachytherapy after chemoradiation is an effective and well-tolerated treatment option for female primary urethral adenocarcinoma. In the two patients presented in this case study, the responses to therapy have been excellent with only relatively mild side-effects.

## References

- Swartz MA, Porter MP, Lin DW, Weiss NS. Incidence of primary urethral carcinoma in the United States. *Urology* 2006;68:1164-8.
- Dalbagni G, Zhang ZF, Lacombe L, Herr HW. Female urethral carcinoma: an analysis of treatment outcome and a plea for a standardized management strategy. *Br J Urol* 1998;82:835-41.
- Thyaviahally YB, Wuntkal R, Bakshi G, et al. Primary carcinoma of the female urethra: Single center experience of 18 cases. *Jpn J Clin Oncol* 2005;35:84-7.
- Eng TY, Naguib M, Galang T, Fuller CD. Retrospective study of the treatment of urethral cancer. *Am J Clin Oncol* 2003;26:558-62.
- Milosevic MF, Warde PR, Banerjee D, et al. Urethral carcinoma in women: Results of treatment with primary radiotherapy. *Radiother Oncol* 2000;56:29-35.
- Gheiler EL, Tefilli MV, Tiguert R, et al. Management of primary urethral cancer. *Urology* 1998;52:487-93.
- Grigsby PW. Carcinoma of the urethra in women. *Int J Radiat Oncol Biol Phys* 1998;41:535-41.
- Kuettel MR, Parda DS, Harter KW, et al. Treatment of female urethral carcinoma in medically inoperable patients using external beam irradiation and high dose rate intracavitary brachytherapy. *J Urol* 1997;157:1669-71.
- Dimarco DS, Dimarco CS, Zincke H, et al. Surgical treatment for local control of female urethral carcinoma. *Urol Oncol* 2004;22:404-9.
- Davis JW, Schellhammer PF, Schlossberg SM. Conservative surgical therapy for penile and urethral carcinoma. *Urology* 1999;53:386-92.
- Kent D, Gee JR, Amato RJ, Pisters LL. Successful management of metastatic urethral cancer with organ preservation. *J Urol* 2001;166:2308.
- Nicholson S, Tsang D, Summerton D. Aggressive combined-modality therapy for squamous cell carcinoma of the female urethra. *Nat Clin Pract Urol* 2008;5:574-7.
- Gillitzer R, Hampel C, Wiesner, et al. Single-institution experience with primary tumours of the male urethra. *BJU Int* 2008;101:964-8.
- Hakenberg OW, Franke HJ, Froehner M, Wirth MP. The treatment of primary urethral carcinoma--the dilemmas of a rare condition: experience with partial urethrectomy and adjuvant chemotherapy. *Onkologie* 2001;24:48-52.
- Micaily B, Dzeda MF, Miyamoto CT, Brady LW. Brachytherapy for cancer of the female urethra. *Semin Surg Oncol* 1997;13:208-14.
- Foens CS, Hussey DH, Staples JJ, et al. A comparison of the roles of surgery and radiation therapy in the management of carcinoma of the female urethra. *Int J Radiat Oncol Biol Phys* 1991;21:961-8.
- Dalbagni G, Donat SM, Eschwège P, et al. Results of high dose rate brachytherapy, anterior pelvic exenteration and external beam radiotherapy for carcinoma of the female urethra. *J Urol* 2001;166:1759-61.
- Dinney CP, Johnson DE, Swanson DA, et al. Therapy and prognosis for male anterior urethral carcinoma: an update. *Urology* 1994;43:506-14.
- Elsayes KM, Mukundan G, Narra VR, et al. Endovaginal magnetic resonance imaging of the female urethra. *J Comput Assist Tomogr* 2006;30:1-6.
- Takeuchi M, Matsuzaki K, Nishitani H. Clear cell adenocarcinoma of the female urethra: magnetic resonance imaging. *J Comput Assist Tomogr* 2009;33:142-4.
- Prasad SR, Menias CO, Narra VR, et al. Cross-sectional imaging of the female urethra: technique and results. *Radiographics* 2005;25:749-61.
- Kawashima A, Sandler CM, Wasserman NF, et al. Imaging of urethral disease: a pictorial review. *Radiographics* 2004;24 (Suppl 1):S195-216.
- Ryu J, Kim B. MR imaging of the male and female urethra. *Radiographics* 2001;21:1169-85.
- Hricak H, Secaf E, Buckley DW, et al. Female urethra: MR imaging. *Radiology* 1991;178:527-35.
- Vapnek JM, Hricak H, Carroll PR. Recent advances in imaging studies for staging of penile and urethral carcinoma. *Urol Clin North Am* 1992;19:257-66.