

CASE REPORT

doi: 10.5455/medarch.2019.73.61-62

MED ARCH. 2019 FEB; 73(1): 61-62

RECEIVED: NOV 25, 2018 | ACCEPTED: JAN 22, 2019

¹Eye Clinic Svjetlost Sarajevo, Sarajevo, Bosnia and Herzegovina²University Eye Clinic Svjetlost Zagreb, Zagreb, Croatia**Corresponding author:** Ajla Pidro, dr. Mustafe Pintola 23, Sarajevo. ORCID ID: <http://www.orcid.org/0000-0002-1272-3500>. Tel. 060 31 94 709. Fax: 033 762 771. E-mail: ajla@svjetlost-sarajevo.ba.

A Case Study of Choroideremia and Choroideremia Carrier

Ajla Pidro¹, Mirko Ratkovic², Melisa Ahmedbegovic Pjano¹, Alma Biscevic¹

ABSTRACT

Aim: The aim of this case report was to report the clinical and genetic characteristics of choroideremia patient and a family member carrier. **Case report:** A comprehensive ophthalmologic examination, BCVA (best corrected visual acuity), fundus examination and photography, optical coherence tomography (OCT), OCT–angiography (OCTA), perimetry was conducted in choroideremia patient and a family member carrier. Clinical findings of choroideremia patient presented as significant atrophy of the choroid and retinal pigment epithelium (RPE) with the exception of a portion of preserved tissue in the macula. OCT showed foveal thickening with parafoveal RPE and photoreceptor (FR) atrophy. OCTA revealed loss of choriocapillaris vasculature. Clinical diagnosis of CHM mutation was confirmed by multiplex ligation-dependent probe amplification (MLPA), followed by sequencing which revealed pathogen variance (c.1584_1587delTGTT). Clinical findings of carrier: small peripheral zones of atrophy and hyper pigmentation, without any symptoms or major visible changes on OCT or OCTA. **Conclusion:** Following new frontiers in gene therapy it is of curtail importance to diagnose patients correctly as well as confirm clinical diagnosis by genetic testing.

Keywords: choroideremia, choroideremia carrier, CHM, genetic testing.

1. INTRODUCTION

Choroideremia is a rare bilateral X-linked disorder characterized by progressive degeneration of the retinal pigment epithelium (RPE) and choroid, with incidence estimated as 1 in 100,000 (1).

Symptoms are expressed in male patients and include progressive peripheral vision loss, night blindness and later central vision loss, similar to other chorioretinal dystrophies (1). Female carriers are mostly asymptomatic but can present with patchy chorioretinal atrophy (2).

Choroideremia is caused by mutations in the CHM gene (OMIM 303390), which is located at chromosome Xq21.2 (3). The gene has 15 exons spanning about 150 kb (kb) of genomic DNA and is expressed in many tissues like retina, choroid, retinal pigment epithelium and lymphocytes. It encodes an intracellular protein called Rab escort protein-1 (REP-1) (4).

Mutations include large deletions, translocations, an L1 insertion and small mutations (3), all of which lead to premature stop codon, which then results in the dysfunction or complete absence of REP-1. There are 280 identified mutations that result in the CHM phenotype, but even after extensive research there is no

established genotype–phenotype correlation (4).

To the best of our knowledge, this is the first report on genetic diagnosis of choroideremia in Bosnia and Herzegovina.

2. CASE REPORT

A 10 year old patient was diagnosed with retinitis pigmentosa (RP) earlier in other institution. He presented at our complaining of blurred vision on distance even with his glasses which he was using for 1 year. The patient was myopic: right eye -1.50 D and left eye -1,25 D, with UDVA 0.3 and BCVA 1.0 on both eyes. Anterior segment examination was unremarkable.

Fundus examination on both eyes revealed significant atrophy of the choroid with the exception of a portion of preserved tissue in the macula (Figure 1).

OCT (Optopol, findings revealed foveal thickening without signs of atrophy in foveal region, parafoveal finding were diffuse RPE atrophy and photoreceptor loss. OCT angiography (Avanti RTVue XR; Optovue) demonstrated the absence of choriocapillaris, with prominent large choroid vasculature, and normal vascular network within retina. Macular angiograms (3 × 3) showed decreased vascularity in the chorio-

© 2019 Ajla Pidro, Mirko Ratkovic, Melisa Ahmedbegovic Pjano, Alma Biscevic

This is an Open Access article distributed under the terms of the Creative Commons Attribution Non-Commercial License (<http://creativecommons.org/licenses/by-nc/4.0/>) which permits unrestricted non-commercial use, distribution, and reproduction in any medium, provided the original work is properly cited.

capillaris layer and show off larger choroid vessels, but only on the edges of the frame. Perimetry showed concentric reduction in the visual field of both eyes, symmetrical. The patient did complain on somewhat worse vision during night, but he is still able to perform all needed tasks at any period of day.

Genetic testing was performed and diagnosis of CMH was confirmed. First 4 base deletion was identified and further sequencing revealed pathogen variance (c.1584_1587delTGTT), p(VL529Hisfs7). This mutation led to production of truncated REP peptide shortened by 19%.

Later, a carrier, patients 41 years old mother was examined. She had BCVA 1.0, without complaints. Fundus examination of the periphery retina in a carrier with areas of mild chorioretinal atrophy and mottled pigment with hyperpigmentation, otherwise findings were normal. OCT and OCTA showed normal findings.

3. DISCUSSION

Our patient was misdiagnosed due to low interest for genetic testing in underdeveloped countries. Clinically choroideremia can have many different clinical presentation. Differential diagnosis include: gyrate atrophy, RP (X-linked and RPE65), Kearns–Sayre syndrome, Bietti's crystalline dystrophy and thioridazine hydrochloride retinal toxicity (5). Shiqiang et al report out of 157 RP diagnosed families, 6 had been misdiagnosed and had CHM mutation (6). Even earlier studies suggest that 25% of clinically diagnosed choroideremia may have other diseases (5).

Many researchers have come to conclusion that in order to confirm diagnosis combined molecular genetics approach including direct CHM sequencing, multiplex ligation-dependent probe amplification, and RNA (cDNA) sequencing, as well as NGS-based methods should be considered (6). In our study MLPA was negative, and a lack of large chromosome rearrangements was confirmed, followed by sequencing of the PCR product.

Patient is only starting to experience symptoms in form of blurry vision, slight defects in visual field, somewhat poor vision during night, but he is still able to perform all needed tasks at any period of day. Along with myopia, OCT, OCTA all of the findings are consistent to literature (1, 4, 6). Different studies demonstrate damage to choriocapillaris, with prominent choroid vasculature of large vessels (7). In our patient choriocapillaris is still preserved in big portion of 3x3 macula map, henceforth good BCVA. Damaged areas correspond to RPE degeneration.

The female carrier had peripheral pigmentary stippling with regions of hypopigmentation, similar changes on fundus examination as already described by Bonilha et al. (2).

Even though there is no effective treatment for CHM, there is a great progress in genetic and clinical character-

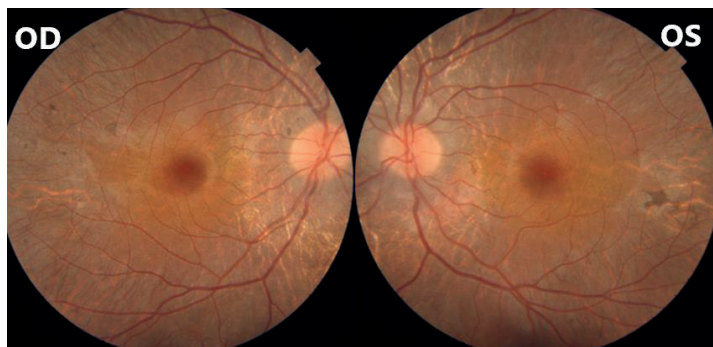


Figure 1. Fundus image of the patient both eyes showing chorioretinal atrophy of the retina central and mid-peripherally, with preservation of macular tissue. (OD oculus dexter, OS – oculus sinister)

ization of CHM. Gene therapy is in phase 3 clinical trials, and many pharmacological compounds and non-viral gene delivery are also being developed (8). CHM monogenic nature enables gene therapy development and future research of diagnostics and novel treatment strategies (8). Following these new frontiers it is of curtail importance to diagnose patients correctly as well as confirm clinical diagnosis by genetic testing.

REFERENCES

1. MacDonald IM, Russell L, Chan C. Choroideremia: New Findings from Ocular Pathology and Review of Recent Literature. *Surv Ophthalmol.* 2009; 54(3): 401-407. doi: 10.1016/j.survophthal.2009.02.008
2. Bonilha VL, Trzupek KM, Li Y, et al. Choroideremia: Analysis of the retina from a female symptomatic carrier. *Ophthalmic Genet.* 2008; 29(3): 99-110. doi: 10.1080/13816810802206499
3. van den Hurk JA, Schwartz M, van Bokhoven H, et al. Molecular basis of choroideremia (CHM): mutations involving the Rab escort protein-1 (REP-1) gene. *Hum Mutat.* 1997; 9: 110-117. doi: 10.1002/(SICI)1098-1004(1997)9:2<110::AID-HUMU2>3.0.CO;2-D
4. Battu R, Jeyabalan N, Murthy P, Reddy KS, Schouten JS, Webers CA. Genetic analysis and clinical phenotype of two Indian families with X-linked choroideremia. *Indian J Ophthalmol.* 2016; 64(12): 924-929. doi: 10.4103/0301-4738.198866
5. Coussa RG and Traboulsi EI. Choroideremia: a review of general findings and pathogenesis. *Ophthalmic Genet.* 2012; 33: 57-65. doi: 10.3109/13816810.2011.620056.
6. Shiqiang Li, Liping Guan, Shaohua Fang, et al. Exome sequencing reveals CHM mutations in six families with atypical choroideremia initially diagnosed as retinitis pigmentosa. *International Journal of Molecular Medicine.* 2014; 34: 573-577. doi: 10.3892/ijmm.2014.1797
7. Jia Y, Bailey ST, Hwang TS, et al. Quantitative optical coherence tomography angiography of vascular abnormalities in the living human eye. *Proc Natl Acad Sci U S A.* 2015; 112(18): 2395-402. doi:10.1073/pnas.1500185112
8. Mitsios A, Dubis AM, Moosajee M. Choroideremia: from genetic and clinical phenotyping to gene therapy and future treatments. *Ther Adv Ophthalmol.* 2018; 10: 2515841418817490. doi:10.1177/2515841418817490