

Post traumatic internal iliac arteriovenous fistula presenting with persistent gross hematuria

Amanda Smart, Michael Wynne^{*}, Daniel Stein

Department of Urology, George Washington University Hospital, Washington, DC, USA

ARTICLE INFO

Keywords:

Traumatic arteriovenous fistula
Pelvic arteriovenous fistula
Internal iliac arteriovenous fistula
Gross hematuria

ABSTRACT

Traumatic pelvic arteriovenous fistulas (AVFs) are exceedingly rare and can lead to significant morbidity. Herein, we describe the case of a 31 year-old male who presented with two months of recurrent gross hematuria following a gluteal gun-shot wound and was found to have a right internal iliac AVF. To our knowledge, this is the first reported case of a post traumatic pelvic AVF presenting with gross hematuria.

1. Introduction

While not frequently encountered, traumatic arteriovenous fistulas (AVFs) are most commonly found within the neck, mediastinum, and extremities. AVFs within the abdomen and pelvis are rare and accounted for less than 4% in one large series.¹ Here we present an unusual case of a post traumatic AVF of the internal iliac artery that presented with intermittent gross hematuria two months after sustaining a pelvic gun-shot wound.

2. Case presentation

A 31 year-old male presented with a left gluteal gun-shot wound and immediate gross hematuria. After transfer to our Level 1 trauma center, a CT scan demonstrated a right pelvic retroperitoneal hematoma and right posterior acetabular fracture. There was fluid noted within the pelvis and the trajectory of the bullet was potentially intrabdominal leading to the decision for exploratory laparotomy. Urology performed a retrograde urethrogram and cystogram intraoperatively and found no evidence of urethral disruption or bladder injury/leak. A 16 Fr catheter was placed without difficulty.

The trauma team then proceeded with exploratory laparotomy and found the right pelvic hematoma was not expanding. No other injuries

were noted, and the abdomen was closed.

The following day the patient had persistent gross hematuria prompting CT cystogram that once again demonstrated no bladder leak but increase in size of the pelvic hematoma between the obturator and bladder wall. He remained stable with conservative management and serial hemoglobin and hematocrit monitoring. His urine color improved to light pink. The catheter was removed after three days and he passed his void trial. His acetabular fracture was managed conservatively by orthopedic surgery. He was discharged home after he passed surgical milestones.

He returned two months later with recurrent gross hematuria and was scheduled for cystoscopy and cystogram in the operating room (Fig. 1). On cystoscopy, a large clot was evacuated and a small os was noted on the right lateral bladder wall with a small outpouching. No overt extravasation was present on cystogram, nor was there any extravasation when contrast was injected via 5 French open-ended catheter at the opening of this os. His urine quickly cleared but he returned two weeks later with sudden onset hematuria and clot retention. He was taken back to the operating room for repeat cystoscopy which once again demonstrated no acute lesions or bleeding; however, a bulge was noted along the right lateral wall with a very small os at the center.

^{*} Corresponding author. 2300 I St NW, Washington, DC, 20052.

E-mail address: mwynne@gwu.edu (M. Wynne).

<https://doi.org/10.1016/j.eucr.2021.101956>

Received 31 October 2021; Received in revised form 18 November 2021; Accepted 21 November 2021

Available online 23 November 2021

This is an open access article under the CC BY-NC-ND license (<http://creativecommons.org/licenses/by-nc-nd/4.0/>).

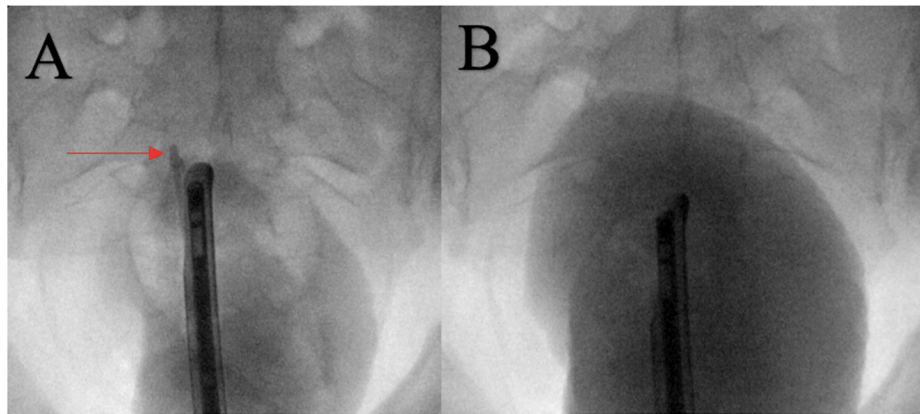


Fig. 1. Cystogram. A) 5Fr open ended catheter (arrow) directed contrast injection at site of right bladder wall. B) Cystogram without evidence of extravasation.

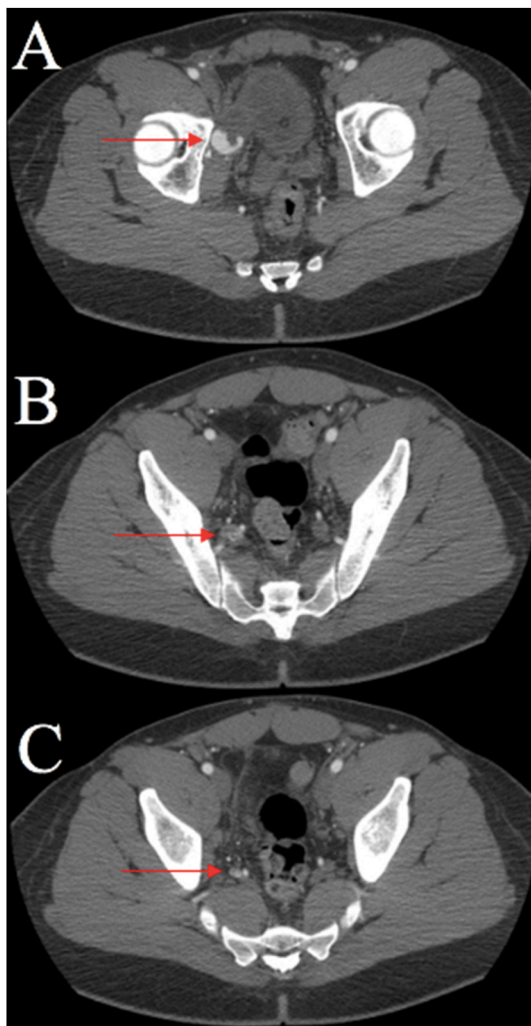


Fig. 2. CT angiography. A) Blush in AVF. B) Active extravasation within AVF. C) Early draining vein consistent with AVF.

Given the persistent hematuria and cystoscopic findings, a CT angiography was obtained and revealed a blush concerning for right internal iliac arteriovenous fistula (Fig. 2). He was taken by interventional radiology for angiogram and coiling the next day. They deployed Azur CX 18 detachable coils X4 and Boston Scientific Interlock coils with near complete stasis (Fig. 3). He recovered well and his catheter was removed without further gross hematuria. On clinic follow up two months later he did not have any further gross hematuria.

3. Discussion

While there are reports of iatrogenic AVFs post renal biopsy diagnosed by persistent gross hematuria, to our knowledge this is the first reported case of a traumatic pelvic AVF presenting with gross hematuria.² An estimated 70% of traumatic AVF are diagnosed in a delayed fashion as in this instance.³ Diagnosis of a pelvic AVF may necessitate a high suspicion of AVF. The classic physical exam findings are a bruit or pulsatile mass. Indeed, in a large series of 202 AVF patients, 96% had a machinery type murmur.^{1,3} Nonetheless, these physical exam findings are far less reliable in pelvic AVFs and, notably, the aforementioned series had only one AVF in the pelvis. CT angiography has been found to have a sensitivity of 90–100% and specificity of 98–100%.⁴ Digital subtraction angiography done in the interventional radiology suite remains the gold standard for diagnosis of AVF and also allows for embolization.

4. Conclusion

Post traumatic pelvic AVFs pose a diagnostic challenge and can lead to significant morbidity due to continued left to right sided shunting of blood.⁵ Given multiple negative cystograms, this case outlines the importance of a high index of suspicion for vascular malformation in a patient with pelvic hematoma near the lateral bladder wall and concurrent unexplained hematuria.

Consent for publication

Informed consent for the publication of the details and images included in this manuscript was obtained from the patient whose clinical case is described in this report.

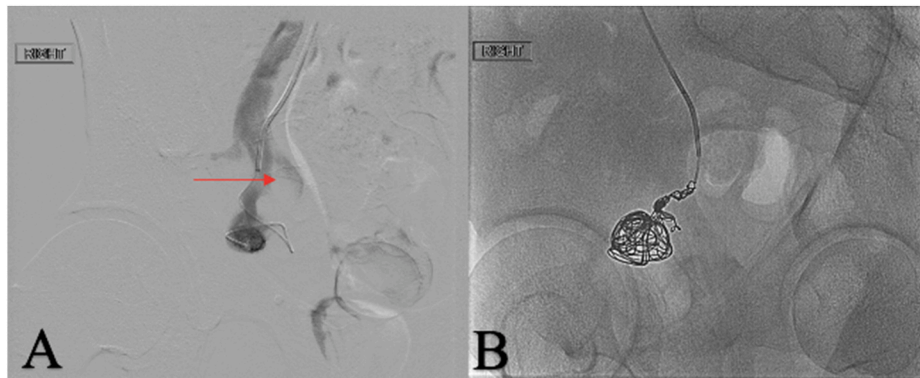


Fig. 3. Angiogram. A) Microcatheter injecting within AVF demonstrating active extravasation. B) Coil embolization of AVF.

Declaration of competing interest

None of the authors have any conflicts of interest in this work.

Acknowledgments & Funding

All authors approved the manuscript and this submission. This research did not receive any specific grant from funding agencies in the public, commercial, or not-for-profit sectors.

References

1. Robbs JV, Carrim AA, Kadwa AM, Mars M. Traumatic arteriovenous fistula: experience with 202 patients. *Br J Surg.* 2005;81(9):1296–1299. <https://doi.org/10.1002/bjs.1800810912>.
2. Shima N, Hayami N, Mizuno H, et al. Arteriovenous fistula-related renal bleeding 5 days after percutaneous renal biopsy. *CEN Case Rep.* 2019;8(4):280–284. <https://doi.org/10.1007/s13730-019-00408-1>.
3. Shaban Y, Elkbuli A, McKenney M, Boneva D. Traumatic femoral arteriovenous fistula following gunshot injury: case report and review of literature. *Ann Med Surg.* 2020;55: 223–226. <https://doi.org/10.1016/j.amsu.2020.05.016>.
4. Chen JK, Johnson PT, Fishman EK. Diagnosis of clinically unsuspected posttraumatic arteriovenous fistulas of the pelvis using CT angiography. *Am J Roentgenol.* 2007;188 (3):W269–W273. <https://doi.org/10.2214/AJR.05.1230>.
5. Perinjilil V, Maraqa T, Chavez Yenter A, et al. Traumatic arteriovenous fistula formation secondary to crush injury. *J Surg Case Rep.* 2018;2018(9):rjy240. <https://doi.org/10.1093/jscr/rjy240>.