



CASE REPORT

Open Access

Primary angiosarcoma of the ovary with prominent fibrosis of the ovarian stroma. Case report of an 81-year old patient

Hans Bösmüller^{1*}, Christine Gruber¹, Sophie Haitchi-Petnehazy¹, Dietmar Wagner², Gerald Webersinke³ and Steffen Hauptmann⁴

Abstract

Primary angiosarcoma of the ovary (AS) is a rare entity with only 31 reported cases. The majority are pure angiosarcomas, the remainder are associated either with teratomas or conventional epithelial tumors. More than 50% of ovarian AS are disseminated at the time of diagnosis, the minority is detected in stage I. The prognosis of ovarian angiosarcoma in general is poor. Most reports refer to younger individuals, aged from 7 to 46 years, and only 2 case reports could be found for patients older than 64 years. Here we present a very unusual case of angiosarcoma in a 81-year-old patient.

Background

Primary angiosarcomas (AS) of the ovary are rare malignancies. Approximately 25% of them are associated with other neoplasms, e.g. mature cystic teratoma, [1-3], mucinous cystadenoma, serous and mucinous carcinoma, [4-6], or fibroma [7]. Metastases to the ovary from soft tissue AS rarely occur [8,9]. 60% of all reported AS were detected in stage III and IV [1-4,6,10-18]. Surgical debulking and chemotherapy provided only short disease-free intervals, and most patients died from lung metastasis within 9 months. Twelve reports with stage I disease indicated better outcome, with only two patients dying within one year [3,5,7,17,19-23]. Ovarian AS usually affects premenopausal women or even children [24], with only two reports in postmenopausal individuals [7,18] (Table 1). Here we describe the oldest patient reported with ovarian AS so far.

Case Presentation

Patient

The 81-year-old patient was admitted to the hospital with abdominal pain and distension. Ultra-sonography and computed tomography revealed a huge cystic mass

of the right ovary. There were no signs of distant tumor deposits. The patient underwent hysterectomy and adnexectomy on the right, the left adnexa had been taken out decades ago. Further exploration of the abdomen and all other clinical investigations were without pathological findings, six weeks after laparotomy the patient underwent chemotherapy with 4 cycles of doxorubicin, and after an follow up of 5 months she is still alive, and there are no signs of recurrence.

Macroscopically the tumor had a weight of 2122 grams and measured 30:18:12 cm. The peritoneal surface was inconspicuous. The cut surface showed a big central cyst with a diameter of 14 cm, containing hemorrhagic debris and some luminal projections. The cyst wall and its immediate surrounding consisted of yellowish fibrous tissue with some myxoid glistening changes and hemorrhagic areas, but no significant necrosis (Figure 1). Microscopically, the cyst wall was composed of fascicularly arranged, densely packed atypical spindle cells with pleomorphic nuclei and sparse cytoplasm. Up to 4 mitoses per high power field were counted. Focally, these spindle cells formed Kaposi-like angiomatous spaces containing erythrocytes. Other tumor components had a more epitheloid character. At the periphery a thick fibrose zone was visible with some edema and foci of well formed angiomatous proliferations, lined by atypical endothelial cells (Figure 2, 3, 4).

* Correspondence: hans-christian.boesmueller@bhs.at

¹Department of Pathology, Krankenhaus Barmherzige Schwestern Linz, Austria

Full list of author information is available at the end of the article

Table 1 Survey of all reported cases of ovarian angiosarcoma including histologic type, stage, author, year of publication and citation number

NR	AGE	HISTOLOGY	STAGE	AUTHOR	YEAR	CITATION
1	7	AS	?	Evtushenko NT	1958	24
2	19	AS	IV	Cunningham MJ	1994	10
3	19	AS	III	Davidson B	2005	16
4	20	AS	I	Nielsen GP	1997	3
5	21	AS	IV	Bouchi J	1993	12
6	25	AS	III	Nucci MR	1998	17
7	25	AS	III	Lifschitz-Mercer B	1998	22
8	20-32 *	AS	I	Nielsen GP	1997	3
9	20-32 *	AS	I	Nielsen GP	1997	3
10	20-32 *	AS	I	Nielsen GP	1997	3
11	20-32 *	AS	III	Nielsen GP	1997	3
12	27	AS	I	Nucci MR	1998	17
13	28	AS	I	Jha S	2005	20
14	31	AS	I	Quesenberry CD	2005	21
15	33	AS	IV	Nara M	1996	15
16	35	AS	IV	Nucci MR	1998	17
17	38	AS	IV	Twu NF	1999	11
18	40	AS	IV	Platt JS	1999	14
19	42	AS	IV	Patel T	1991	13
20	42	AS	I	Nucci MR	1998	17
21	46	AS	I	Furhata M	1998	19
22	67	AS	III	Bradford L	2009	18
23	81	AS	I	Bösmüller H	2011	
24	20-32 *	Mature cystic teratoma + AS	III	Nielsen GP	1997	3
25	20-32 *	Mature cystic teratoma + AS	III	Nielsen GP	1997	3
26	30	Mature cystic teratoma + AS	III	den Bakker MA	2006	2
27	32	Mature cystic teratoma + AS	IV	Contreras AL	2009	1
28	37	Mucinous cystadenocarcinoma + AS	I	Jylling AM	1999	5
29	45	Borderline serous cystadenocarcinoma + AS	IV	Pillay K	2001	6
30	77	Mucinous cystadenoma + AS	III	Ongkasuwan C	1982	4
31	65	Ovarian fibroma + AS	I	Cambruzzi E	2010	7

* age not specified.

It was interesting to note that the spindle shaped high-grade malignant part of the lesion was restricted to the immediate portion of the tumor surrounding the cyst, whereas the angiomatous proliferation at the periphery was much better differentiated. Intact fibrous ovarian stroma could only be identified in areas bordering the intact peritoneal capsule.

The central highly atypical fusiform tumor infiltrate showed intense staining for CD31, reacted weakly for WT1, but had lost expression of CD34. There were nearly no remaining vascular spaces, and we found a Mib-score of 60%. The more angiomatoid proliferation in the periphery did express both, CD31 and CD34, and Ki-67 was expressed only in some of the atypical endothelial cells (Mib-score < 10%). HHV8, epithelial markers (CK7, CAM 5.2, EMA), and smooth muscle actin were negative. Fluorescent in situ hybridisation for SYT-SSX (X; 18) was performed with LSI SYT Dual

Colour Break Apart probe (18q11.2, Abbott, North Chicago, Illinois, USA) and was negative. Based on these findings, the patient was diagnosed with primary angiosarcoma of the ovary, high grade.

Discussion

Ovarian angiosarcoma (AS) is with rare exceptions a disease of premenopausal woman. Only two patients have been reported in postmenopausal age [7,18] and the 81 years old woman described in this report is the oldest patient with this disease in the literature. AS of the ovary is very rare with only two small case series published so far, one with 4 and the other with 7 cases [3,17]. In both publications ovarian AS were described as morphological heterogenous tumors, a fact emphasized in a few other case reports too. The tumor described in this report represented high grade AS only in its central part, towards the periphery an atypical

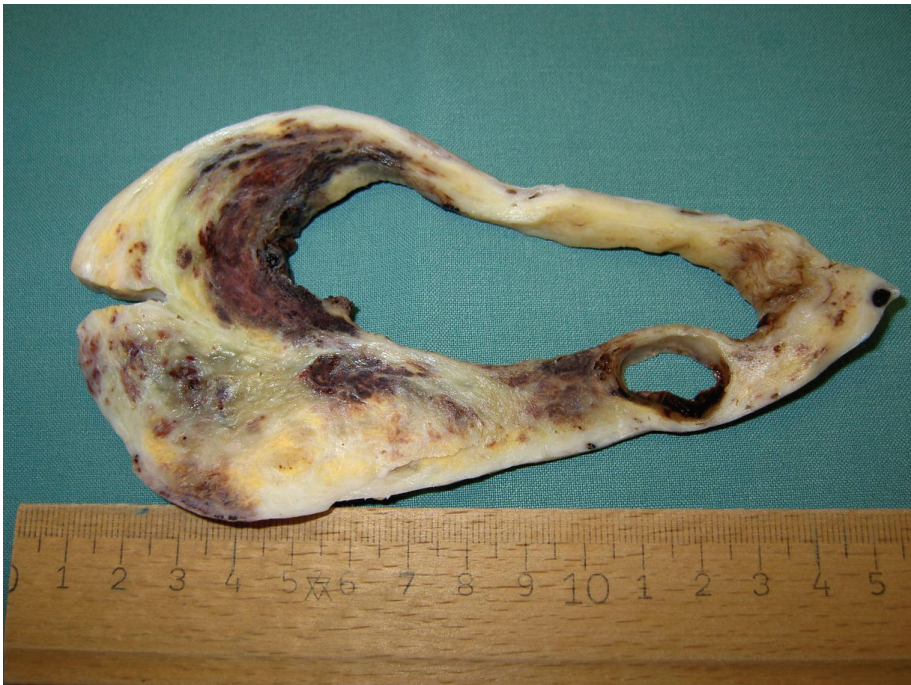

Figure 1 Cut surface of the right ovary featuring a centrally located tumor associated cyst.

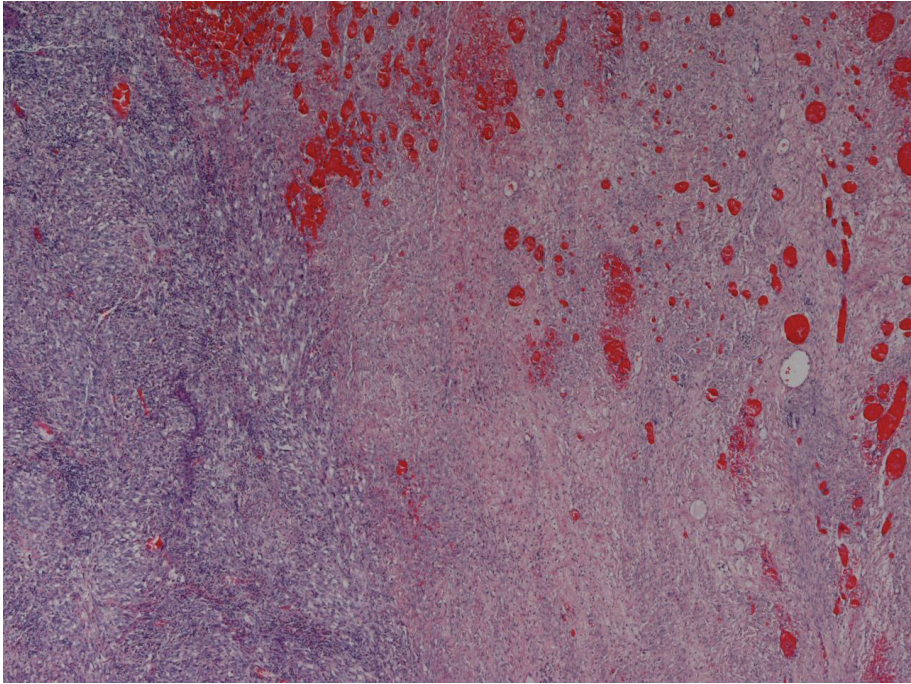


Figure 2 Transformation from centrally located angiosarcoma high grade (left) to more vasculated and well differentiated tumor areas in the periphery; H&E 40x.

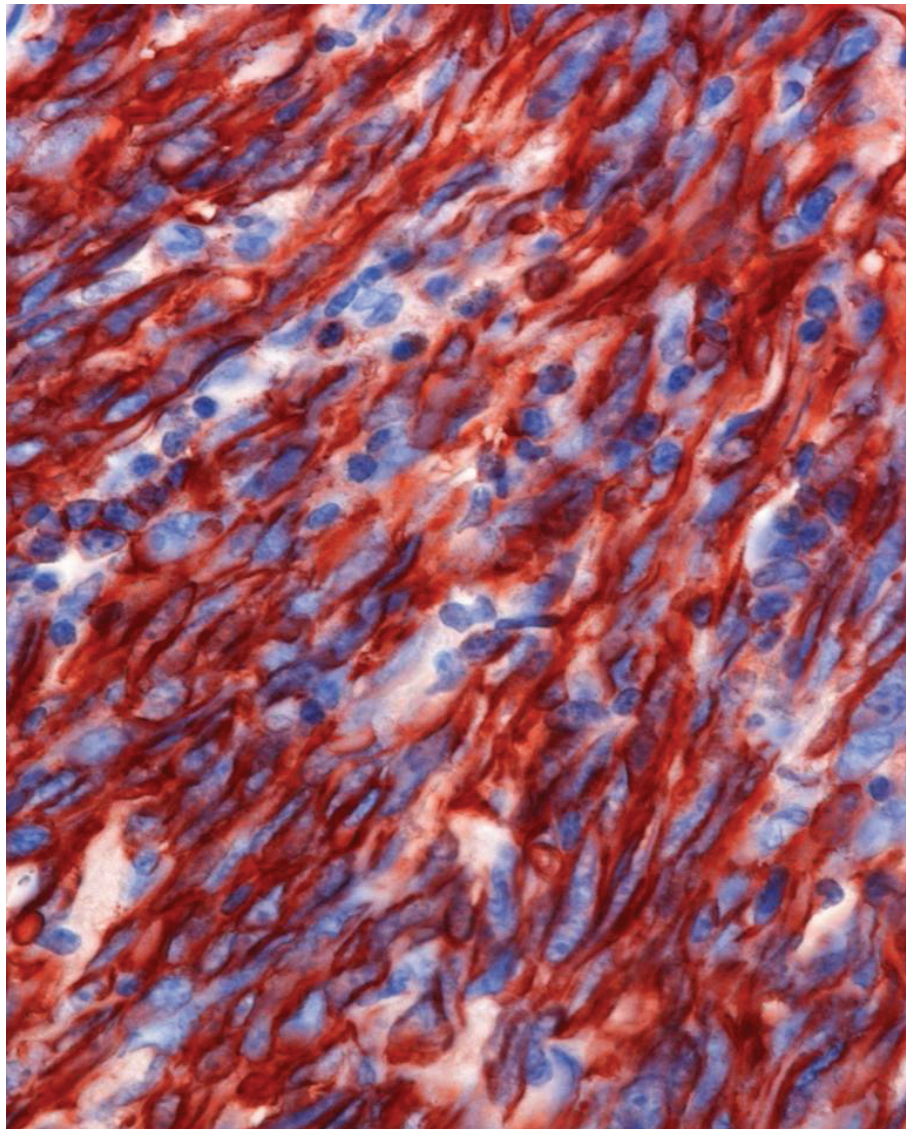


Figure 3 Centrally located angiosarcoma high grade with fusiform tumor component. CD31 staining 400x.

angiomatous proliferation was obvious, alternating with areas of intense fibrosis. A Mib-score of 60% and the marked pleomorphism with atypical mitotic figures in the central areas are striking features for malignancy, so there was no evidence for reactive angioma (Figure 5). Massive fibrosis may obscure a malignant tumor, leading to the misdiagnosis of fibroma or thecoma, similar to our case in the frozen section diagnosis, but nevertheless AS may coexist with true ovarian fibroma [7]. However, massive hemorrhage usually is present and suggests malignancy. Fusiform and fibrous aspects together with only sparse formation of capillary-like spaces, like in our tumor, may focally mimic myogenous origin or metastasis, respectively, but negativity of actin and expression of vascular markers supported the diagnosis of angiosarcoma.

Synovial sarcoma was excluded by negative immunohistochemical staining for epithelial markers and inconspicuous SYT-SSX fluorescent in situ hybridisation [25].

Of 31 reported cases of ovarian angiosarcomas, 23 were pure lesions without coexisting benign or malignant epithelial components. In 5 reports, angiosarcoma was found to be associated with mature cystic teratoma, and in this context it was discussed, whether angiosarcoma is a sarcomatous teratoma, particularly those tumors occurring in younger women[1-3]. In another 3 cases mucinous cystadenoma, mucinous cystadenocarcinoma and borderline serous tumor were coexisting to ovarian AS, rendering the diagnosis adenosarcoma and carcinosarcoma, respectively [4-6], and putting ovarian AS into the context of malignant mesodermal mixed

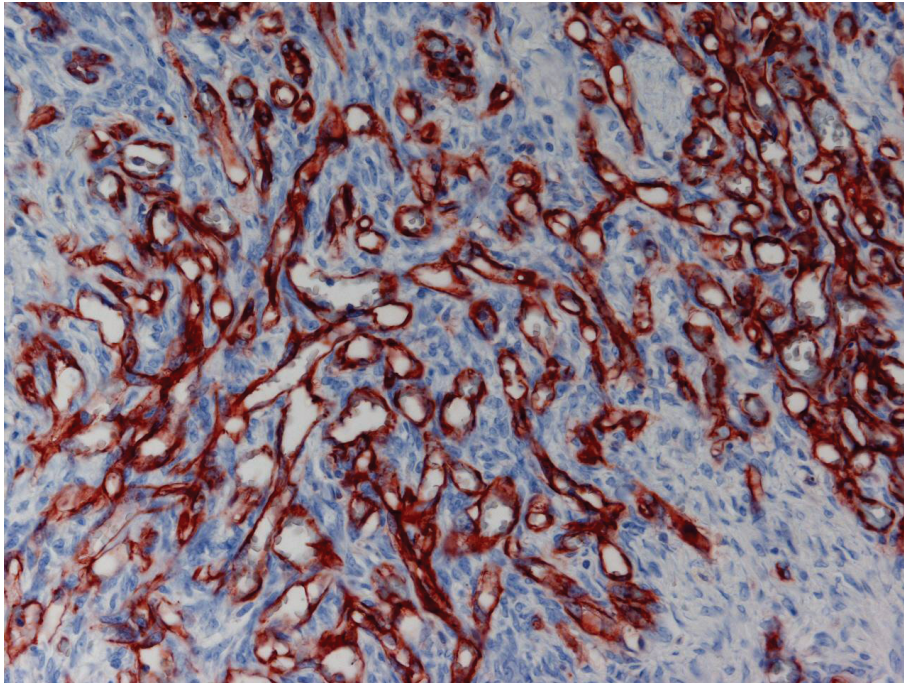


Figure 4 Atypical vascular proliferation in the cortical areas of the ovary. CD31 staining 100x.

tumor (MMMT) [22]. Angiosarcoma itself may show epitheloid features and can therefore be mistaken for carcinoma or metastasis, and one published case had a predominant reticular growth pattern resembling yolk sac tumor [17].

Conclusions

These examples show that the suspicion of ovarian AS opens a broad range of differential diagnostic considerations. The correct histopathological diagnosis, however, is of importance because prognosis of ovarian AS is

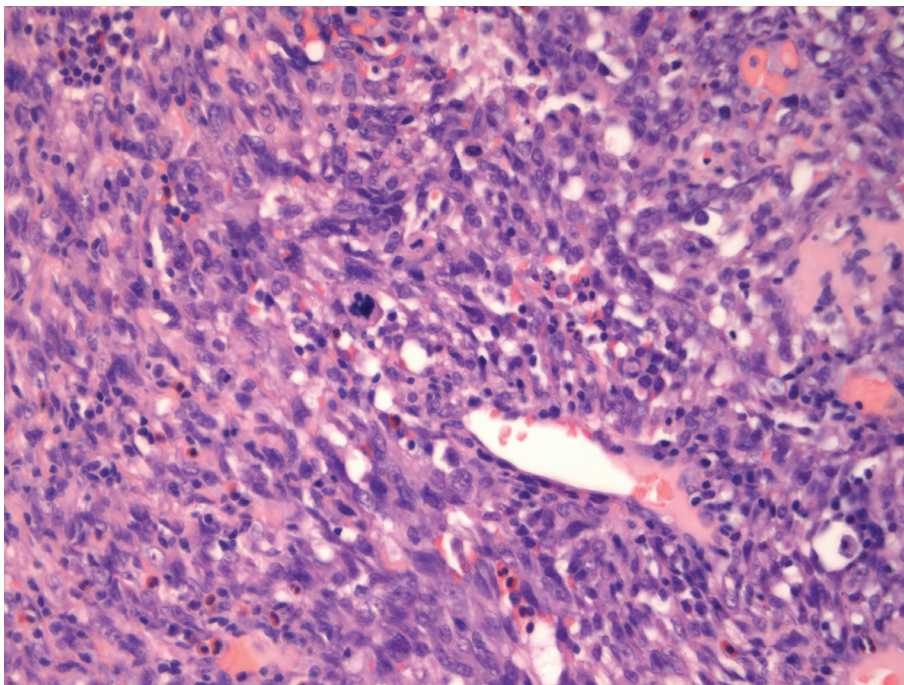


Figure 5 Centrally located high grade angiosarcoma exhibiting atypical mitosis; H&E 200x.

uniformly poor. This could be related to the fact that most patients are diagnosed with advanced disease in stage III or IV. Although patients with stage I disease were shown to survive and even become pregnant [3,20], there are also reports on fatalities of patients with early stage disease.

Consent

Written informed consent was obtained from the patient for publication of this case report and any accompanying images. A copy of the written consent is available for review by the Editor-in-Chief of this journal.

Author details

¹Department of Pathology, Krankenhaus Barmherzige Schwestern Linz, Austria. ²Department of Gynecology, Krankenhaus der Elisabethinen Linz, Austria. ³Laboratory of Molecular Biology und Tumorcytogenetics, I. Internal Department, Krankenhaus Barmherzige Schwestern Linz, Austria. ⁴Department of Pathology, University Hospital of Halle-Wittenberg, Germany.

Authors' contributions

HB conceived the case report and drafted the manuscript, CG and SP carried out histology and immunohistochemistry, DW supplied clinical data, GW carried out molecular analyses, SH supervised the case report and participated in its design and coordination. All authors have read and approved the final manuscript.

Declaration of Competing interests

The authors declare that they have no competing interests.

Received: 21 April 2011 Accepted: 14 July 2011 Published: 14 July 2011

References

1. Contreras AL, Malpica A: Angiosarcoma arising in mature cystic teratoma of the ovary: A case report and review of the literature. *Int J Gynecol Pathol* 2009, **28**:453-457.
2. den Bakker MA, Ansink AC, Ewing-Graham PC: "Cutaneous-type" angiosarcoma arising in a mature cystic teratoma of the ovary. *J Clin Pathol* 2006, **59**:658-660.
3. Nielsen GP, Young RH, Prat J, Scully RE: Primary angiosarcoma of the ovary: a report of seven cases and review of the literature. *Int J Gynecol Pathol* 1997, **16**:378-382.
4. Ongkasuwan C, Taylor JE, Tang CK, Prempre T: Angiosarcomas of the uterus and ovary: clinicopathologic report. *Cancer* 1982, **49**:1469-1475.
5. Jylling AM, Jørgensen L, Hølund B: Mucinous cystadenocarcinoma in combination with hemangiosarcoma in the ovary. *Pathol Oncol Res* 1999, **5**:318-319.
6. Pillay K, Essa AS, Chetty R: Borderline serous cystadenocarcinoma with coexistent angiosarcoma: an unusual form of ovarian carcinosarcoma. *Int J Surg Pathol* 2001, **9**:317-321.
7. Cambuzzi E, Pegas KL, Milani DM, Cruz RP, Guerra EH, Ferrari MB: Angiosarcoma arising in an ovarian fibroma: a case report. *Pathol Res Int* 2010, **842592**.
8. Souza FF, Katkar A, den Abbeele AD, Dipiro PJ: Breast angiosarcoma metastatic to the ovary. *Case Report Med* 2009, **381015**.
9. Cantú De León D, Pérez Montiel D, Chanona Vilchis J: Unusual case of subcutaneous angiosarcoma metastatic to the ovary. *Pathol Oncol Res* 2007, **13**:379-381.
10. Cunningham MJ, Brooks JS, Noumoff JS: Treatment of primary ovarian angiosarcoma with ifosfamide and doxorubicin. *Gynecol Oncol* 1994, **53**:265-268.
11. Twu NF, Juang CM, Yeng MS, Lu CJ, Lai CZ, Chao KC: Treatment of primary pure angiosarcoma of ovary with multiple lung metastases: a case report. *Eur J Gynecol Oncol* 1999, **20**:383-385.
12. Bouchi J, el Asmar B, Couetil JP, Acker M, Taleb N, Gedeon E, Bedran F: Angiosarcoma of the ovary with lung metastases. *Ann Chir* 1993, **47**:740-741.
13. Patel T, Ohri SK, Sundaresan M, Jackson J, Desa LA, Davey AT, Spencer J: Metastatic angiosarcoma of the ovary. *Eur J Surg Oncol* 1991, **17**:295-299.
14. Platt JS, Rogers SJ, Flynn EA, Taylor RR: Primary angiosarcoma of the ovary: a case report and review of the literature. *Gynecol Oncol* 1999, **73**:443-446.
15. Nara M, Sasaki T, Shimura S, Yamamoto M, Oshiro T, Kaiwa Y, Kurokawa Y, Tezuka F, Shirato K: Diffuse alveolar hemorrhage caused by lung metastasis of ovarian angiosarcoma. *Intern Med* 1996, **35**:653-656.
16. Davidson B, Abeler VM: Primary ovarian angiosarcoma presenting as malignant cells in ascites: case report and review of the literature. *Diagn Cytopathol* 2005, **32**:307-309.
17. Nucci MR, Krausz T, Lifschitz-Mercer B, Chan JK, Fletcher CD: Angiosarcoma of the ovary: clinicopathologic and immunohistochemical analysis of four cases with a broad morphologic spectrum. *Am J Surg Pathol* 1998, **22**:620-630.
18. Bradford L, Swartz K, Rose S: Primary angiosarcoma of the ovary complicated by hemoperitoneum: a case report and review of the literature. *Arch Gynecol Obstet* 2010, **281**:145-150.
19. Furihata M, Takeuchi T, Iwata J, Sonobe H, Ohtsuki Y, Wakatsuki A, Morioka N, Sagara Y: Primary ovarian angiosarcoma: a case report and literature review. *Pathol Int* 1998, **48**:967-973.
20. Jha S, Chan KK, Poole CJ, Rollason TP: Pregnancy following recurrent angiosarcoma of the ovary—a case report and review of literature. *Gynecol Oncol* 2005, **97**:935-937.
21. Quesenberry CD, Li C, Chen AH, Zweig SL, Ball HG: Primary angiosarcoma of the ovary: a case report of Stage I disease. *Gynecol Oncol* 2005, **99**:218-221.
22. Lifschitz-Mercer B, Leider-Trejo L, Messer G, Peyser MR, Czernobilsky B: Primary angiosarcoma of the ovary: a clinicopathologic, immunohistochemical and electronmicroscopic study. *Pathol Res Pract* 1998, **194**:183-187.
23. Serrano C, García Á, Brana I, Pérez-Benavente A, Oaknin A: Angiosarcoma of the ovary: is it always a lethal disease? *J Clin Oncol* 2010, **28**:e675-677.
24. Evtushenko NT: Angiosarcoma of the ovary in a 7-year old girl. *Akush Ginekol (Mosk)* 1958, **34**:105.
25. Smith CJ, Ferrier AJ, Russell P, Danieleto S: Primary synovial sarcoma of the ovary: first reported case. *Pathology* 2005, **37**:385-387.

doi:10.1186/1746-1596-6-65

Cite this article as: Bösmüller et al.: Primary angiosarcoma of the ovary with prominent fibrosis of the ovarian stroma. Case report of an 81-year old patient. *Diagnostic Pathology* 2011 **6**:65.

Submit your next manuscript to BioMed Central and take full advantage of:

- Convenient online submission
- Thorough peer review
- No space constraints or color figure charges
- Immediate publication on acceptance
- Inclusion in PubMed, CAS, Scopus and Google Scholar
- Research which is freely available for redistribution

Submit your manuscript at
www.biomedcentral.com/submit

