

Evaluation of embryonic posture using four-dimensional ultrasound and virtual reality

Anne Frudiger¹, Annemarie G. M. G. J. Mulders¹, Melek Rousian¹,
Sophie C. N. Plasschaert¹, Anton H. J. Koning², Sten P. Willemsen^{1,3},
Regine P. M. Steegers-Theunissen¹, Johanna I. P. de Vries⁴ and Eric A. P. Steegers¹

¹Department of Obstetrics and Gynecology, Division of Obstetrics and Prenatal Medicine, Erasmus MC, University Medical Centre Rotterdam, Rotterdam, The Netherlands

²Department of Pathology, Division of Clinical Bioinformatics, Erasmus MC, University Medical Centre Rotterdam, Rotterdam, The Netherlands

³Department of Biostatistics, Erasmus MC, University Medical Centre Rotterdam, Rotterdam, The Netherlands

⁴Department of Obstetrics and Gynecology, Amsterdam Movement Science, Amsterdam UMC-VUmc, Amsterdam, The Netherlands

Abstract

Aim: To assess the possibility of embryonic posture evaluation (=feasibility, reproducibility, variation) at rest at 9 weeks' (+0–6 days) gestational age (GA) using four-dimensional ultrasound and virtual reality (VR) techniques. Moreover, it is hypothesized that embryonic posture shows variation at the same time point in an uneventful pregnancy.

Methods: In this explorative prospective cohort study, 23 pregnant women were recruited from the Rotterdam periconceptional cohort. A transvaginal four-dimensional ultrasound examination of 30 min per pregnancy was performed between 9 and 10 weeks' GA. The acquired datasets were offline evaluated longitudinally (i.e. per frame) using VR techniques.

Results: The ultrasound data of 16 (70%) out of 23 pregnancies were eligible for evaluation. At rest the analysis of the embryonic posture was feasible and showed a strong (>80%) intraobserver and interobserver reproducibility for most body parts. The majority of the body parts were in similar anatomic positions at rest. However, variations in anatomic positions (e.g. 6% rotated head, 9% laterally bent spine), within and between embryos, were seen at 9 weeks' GA.

Conclusion: In this unique study, we showed for the first time that embryonic posture measurements at rest can be performed in a reliable way using state-of-the-art four-dimensional ultrasound and VR techniques. Already early in prenatal life there are differences regarding posture within and between embryos.

Key words: embryonic development, posture, pregnancy trimester, first, ultrasonography, virtual reality.

Introduction

Neurobehavior (i.e. posture and movement) in early life is an expression of embryonic central nervous system maturation. Variations in embryonic development,

as reflected by neurobehavior, may result in variable pregnancy outcomes and hence differences in neonatal health or even health in later life.¹ It has been shown that abnormal developing fetuses show aberrant movement patterns. For instance, fetuses exposed to a

Received: April 28 2020.

Accepted: October 16 2020.

Correspondence: Dr. Annemarie G. M. G. J. Mulders, Department of Obstetrics and Gynecology, Division of Obstetrics and Prenatal Medicine, Erasmus MC, University Medical Centre Rotterdam, PO Box 2040, 3000 CA, Rotterdam, The Netherlands. Email: a.mulders@erasmusmc.nl

© 2020 The Authors. *Journal of Obstetrics and Gynaecology Research* published by John Wiley & Sons Australia, Ltd 397
on behalf of Japan Society of Obstetrics and Gynecology.

This is an open access article under the terms of the Creative Commons Attribution-NonCommercial-NoDerivs License, which permits use and distribution in any medium, provided the original work is properly cited, the use is non-commercial and no modifications or adaptations are made.

diabetogenic environment during early life show a delayed emergence of specific movement patterns during the first trimester.² During pregnancy, neurobehavior can be evaluated using ultrasound to distinguish between periods of rest and movement. Subsequently, the anatomic positions can be examined in periods of rest. At the moment, knowledge on normal neurobehavioral development during embryonic life and its association with pregnancy outcome is still limited. Improvement in ultrasound imaging techniques enables embryonic evaluation from early pregnancy onwards. Moreover, as early fetal structural assessment (=the first trimester anomaly scan) is being introduced in antenatal care, it is important to expand knowledge on normal embryonic neurobehavior prior to describing aberrant neurobehavior.

Knowledge on embryonic posture is restricted and possibly inaccurate, since it is based on two-dimensional (2D) ultrasound examinations performed in the 1990s.^{3,4} Quality of these mostly transabdominally acquired ultrasound data is lower compared to currently available ultrasound techniques. Moreover, interpretation of 2D ultrasound images is hampered by the fact that screens only depict one plane. It is obligatory to image simultaneously in three dimensions to study the posture of a complete human embryo at once. When the embryo moves, a fourth dimension (i.e. time) comes into play. At present, high-quality ultrasound machines are still using 2D computer screens to evaluate the obtained three-dimensional (3D) and four-dimensional (4D) data. Consequently, optimal evaluation of the third dimension cannot be performed. At the Erasmus MC unique innovative software, called V-SCOPE, is utilized facilitating depth perception of 3D and 4D ultrasound data.^{5,6} Ultrasound datasets are displayed as holograms using virtual reality (VR) techniques, like the Barco I-Space CAVE or VR Desktop system. It has already been shown that 3D transvaginal ultrasound imaging used in combination with VR provides accurate and reliable visualization and evaluation of embryonic structures with real depth perception.⁷

From 2D real-time transvaginal ultrasound examinations on movements during the first trimester of pregnancy we know that the onset of the earliest movements is at 7 weeks' postmenstrual gestational age (GA) consisting of simple sideways bending of head and/or rump during 1 s. At 9 weeks' GA also more complex movements appear; the so-called general movements, demonstrating variation in amplitude, speed, direction and participating body parts

and lasting several seconds. The simple sideways bending and the complex general movements coincide during 9 to 13 weeks' GA, the first movement decreasing in incidence and the latter increasing.⁸ Recently, also the position of embryonic body parts in the first trimester of pregnancy was measured. Bogers *et al.* showed that measurements of the embryonic foot position were feasible using 3D ultrasound datasets which were studied using VR.⁹

From this background we hypothesize that embryonic posture at rest during the early prenatal period, even in uneventful pregnancies, will demonstrate already small variations, as a proxy for neurobehavior/neurodevelopment. We therefore aim to assess feasibility and reproducibility of embryonic posture evaluation at rest at 9 (+0–6 days) weeks' GA using 4D ultrasound and VR techniques. Furthermore, the percentage of time the embryo is at rest or in movement during this specific gestational period is described.

Methods

For this explorative prospective cohort study, 23 pregnant women were asked to participate. These women were recruited from the Rotterdam periconceptual cohort (Predict study), an ongoing prospective study, focusing on the influence of lifestyle and environmental factors on human development.¹⁰ This study is embedded in the outpatient clinic of the department of Obstetrics and Gynecology at the Erasmus MC, University Medical Center Rotterdam, the Netherlands. The women had to meet the following inclusion criteria: uncomplicated, singleton pregnancy, maternal age ≥ 18 years, < 10 weeks' postmenstrual GA (equal to ≤ 8 weeks postconceptional age and as such within the embryonic period) and sufficient knowledge of the Dutch language.

The GA was calculated from the last menstrual period (LMP) in spontaneous conceived pregnancies and from the date of oocyte pick-up plus 14 days in pregnancies conceived through in vitro fertilization with or without intracytoplasmic sperm injection. When the menstrual cycle was regular but more than 3 days different from 28 ($28 \pm >3$ days), we adjusted the GA for the duration of the menstrual cycle. If the LMP was missing or the difference between GA determined by crown-rump length (CRL) and LMP was more than 7 days, GA was based on CRL.¹¹

Transvaginal ultrasound examinations were performed by a (basic) trained ultrasonographer (A. M.). A. M. performed the ultrasound examinations after instruction by a sonographer already working with 3D and 4D ultrasound recordings. A General Electric (GE) Voluson E8 ultrasound machine equipped with a transvaginal high resolution (5–9 MHz) 4D probe was used to perform a one-time 4D ultrasound examination of approximately 30 min. The entire gestational sac was included in the region of interest (ROI) during the 4D ultrasound examination. The ultrasound examination was performed according to the safety guidelines of the British Medical Ultrasound Society (BMUS).¹²

After the ultrasound examination, the acquired 45D datasets were converted to Cartesian volumes, using 4D View (Kretz, Zipf, Austria) software, to prepare them for evaluation using V-Scope volume visualization application. V-Scope was used to render a 'hologram' of the ultrasound image in the I-Space. The 'hologram' can be manipulated by means of a virtual pointer controlled by a wireless joystick. This allows the user to rotate the embryo around all axes (Video S1, Supporting Information). Also, the gray scale, color and opacity of the data can be changed. For an extensive explanation of the I-Space VR system and the V-Scope software see earlier publications.^{13,14} For the evaluation of the 4D data we added a functionality to play the volume sequence as a single frame at the time and with 10 consecutive frames, in addition to the continuous playback mode at normal (as recorded) speed. This allows us to accurately monitor changes in posture, with minimal user interaction.

Embryonic rest, movement and posture

All evaluations were performed frame-by-frame instead of per second, since the frame rate differs between recordings. As the frame rate depends on the size of the volume being recorded, it could not be set to a fixed rate for every recording. First, all frames were viewed to determine the quality of the recordings. A self-developed quality score (0–5), based on blurriness (yes/no), acoustic shadowing (yes/no) and overall quality (low/average/good), was given to each recording. If the quality of the recording was very low (0), the ultrasound data were not used for evaluation. Second, for all frames it was determined whether the embryo was at rest or in movement. The embryo was noted to be at rest when the posture did not change compared to the frame before. When the posture did change from the frame before, the embryo was noted to be in movement. If the distinction between rest and movement could not be made, the frame was classified as unevaluable. Following frame-by-frame evaluation periods of embryonic rest and movement together with unevaluable phases were identified (Video S2). Subsequently, embryonic posture was assessed twice during each resting period. After analyzing two embryos, we concluded the embryonic posture remained constant within the same period of rest. Therefore, embryonic posture was evaluated only once during each resting period (Fig. 1). To determine the embryonic posture at rest, a total of 30 items were scored. These items are divided into evaluations of the anatomic positions of the head, spine, upper and lower extremities as described below:

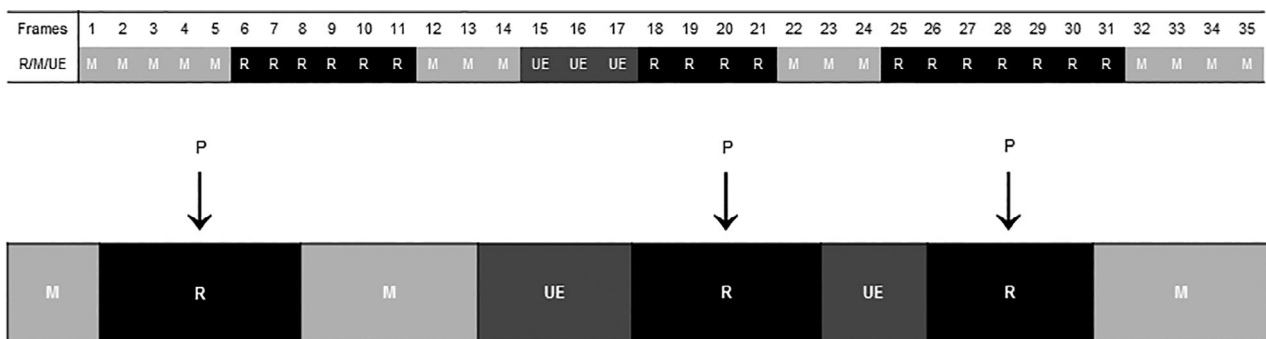


Figure 1 Schematic view of the evaluation of embryonic posture. The upper figure shows the evaluation per frame. Frames can be scored as if the embryo was at rest (R), in movement (M) or unevaluable (UE). The figure below also shows at which time point the embryonic posture (P) is determined. The letter P reflects the exact location of the frame in which the posture evaluation is performed; namely the middle of a resting period.

Table 1 Definition of embryonic positions

Position	Definition
Head	
Neutral	Head is positioned in the extension of the spine
Ante flexion	Head is bent forward
Retro flexion	Head is bent backward
Rotated left	Head has departed from the midline and turned to the left
Rotated right	Head has departed from midline and turned to the right
Spine	
Neutral	Upright position of the spine
Extension	Straight position of the spine, overextension
Flexion	Spine is bent forward
Laterally bent left	Lateral flexion of the spine to the left
Laterally bent right	Lateral flexion of the spine to the right
Shoulder	
Frontal	Upper extremity is positioned in front of the body
Dorsal	Upper extremity is positioned behind the body
Internally rotated	Rotated position of the upper extremity toward the midline of the body
Externally rotated	Rotated position of the upper extremity away from the midline of the body
Adducted	Upper extremity is positioned against the body / thorax
Abducted	Upper extremity is positioned away (lateral) from the body / thorax
Elbow	
Extension	Elbow is positioned in a straight position
Flexion	Elbow is bent
Wrist	
Neutral	Wrist is positioned in a straight position
Palmar flexion	Bent position of the wrist toward the palmar surface
Dorsiflexion	Backward flexion of the wrist; bent in the direction of the dorsum
Radial deviated	Radial flexion, wrist is bent to the radial bone side
Ulnar deviated	Ulnar flexion, wrist is bent to the ulnar bone side
Fingers	
Extension	Fingers are positioned in a straight position
Flexion	Fingers are bent toward the palmar surface of the hand
Height hand	
High	Hands are positioned at the height of the head
Middle	Hands are positioned at the height of the lower part of the thorax
Low	Hands are positioned at the height of the umbilical cord
Hand relative to other hand	
Against	Hands making contact
Close	Hands not making contact and positioned inside the contour of the body
Far	Hands not making contact and positioned outside the contour of the body
Hip	
Extension	Hip is positioned in a straight position
Flexion	Hip is bent
Internally rotated	Rotated position of the lower extremity toward the midline of the body
Externally rotated	Rotated position of the lower extremity away from the midline of the body
Knee	
Extension	Knee is positioned in a straight position
Flexion	Knee is bent
Foot	
Inversion	The plantar surface of the foot is positioned toward the midline of the body
Eversion	The plantar surface of the foot is positioned away from the midline of the body
Foot relative to other foot	
Against	Feet making contact
Close	Feet not making contact and positioned inside the contour of the body
Far	Feet not making contact and positioned outside the contour of the body

Table 2 Characteristics included pregnant women

Characteristics	Pregnant women (<i>n</i> = 16)
Age, years (range)	30.0 (25.5–41.3)
BMI, kg/m ² (range)	24.0 (18.0–32.7)
Gestational age, weeks ^{+days} (range)	9 ⁺³ (9 ⁺⁰ –10 ⁺¹)
Primigravida (%)	7 (43.8)
Nulliparous (%)	12 (75.0)
Mode of conception (%)	7 (43.8)
IVF/ICSI	
No congenital abnormality (%)	16 (100.0)
Gestational age at birth, days (range)	39 ⁺¹ (35 ⁺⁴ –41 ⁺⁶)
Birth weight, grams (range)	3269 (2390–4345)

Continuous data is presented as median, categorical data as *N*. BMI, body mass index; IVF/ICSI, in vitro fertilization with or without intracytoplasmic sperm injection.

- The position of the head was scored as neutral, in ante flexion versus in retro flexion and as rotated to the left or right.
- The position of the spine was scored as neutral, in flexion versus in extension, and as laterally bent to the left or right.
- For both (left and right) upper extremities the position of the shoulder, elbow, wrist, hand and fingers was assessed.
- For both (left and right) lower extremities the position of the hip, knee and foot was analyzed.

For an extensive description of the anatomic positions of each body part (head, spine, shoulder, elbow, wrist, fingers, hand, hip, knee, foot) see Table 1.

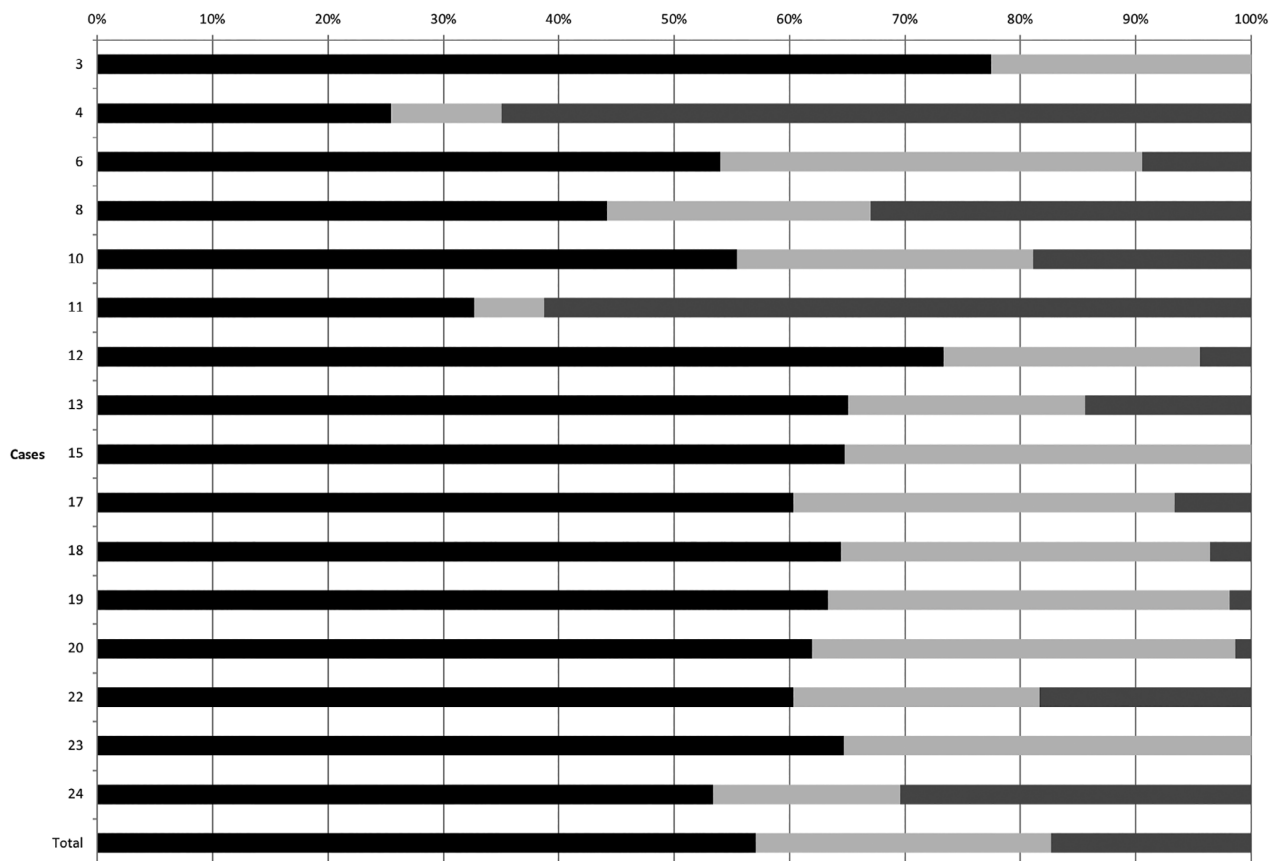


Figure 2 Schematic view of periods representing an embryo being at rest or in movement. Unevaluable periods are also shown. This figure shows per case the percentage of time in which the embryo was at rest, in movement and unevaluable. ■, Rest; ■, Movement; ■, Unevaluable.

Table 3 Reproducibility of embryonic position

Body part	Intraobserver reproducibility (SD)		Interobserver reproducibility % (SD)	
Head				
Neutral/ante flexion/retro flexion	100 (0)		100 (0)	
Rotated, left/right	94 (8.8)		89 (15.1)	
Spine				
Neutral/extension/flexion	100 (0)		100 (0)	
Laterally bent, left/right	91 (13.7)		84 (20.8)	
Hand relative to other hand				
Against/close/far	99 (2.4)		84 (26.7)	
Foot relative to other foot				
Against/close/far	99 (3.7)		83 (21.3)	
	Left extremities		Right extremities	
	Intraobserver reproducibility % (SD)	Interobserver reproducibility % (SD)	Intraobserver reproducibility % (SD)	Interobserver reproducibility % (SD)
Shoulder				
Frontal/dorsal	100 (0)	100 (0)	100 (0)	100 (0)
Internally rotated/externally rotated	100 (0)	100 (0)	100 (0)	100 (0)
Adducted/abducted	83 (15.6)	81 (23.9)	87 (17.2)	85 (16.1)
Elbow				
Extension/flexion	100 (0)	100 (0)	100 (0)	98 (8.9)
Wrist				
Neutral/palmar flexion/dorsal flexion	96 (11.5)	84 (33.2)	98 (6.9)	90 (22.1)
Radial deviated/ulnar deviated	94 (13.1)	77 (25.3)	89 (14.8)	81 (26.5)
Fingers				
Extension/flexion	100 (0)	100 (0)	100 (0)	100 (0)
Hands height				
Head/low thorax/umbilical cord	100 (0)	97 (8.6)	100 (0)	99 (2.1)
Hip				
Extension/flexion	100 (0)	100 (0)	100 (0)	100 (0)
Internally rotated/externally rotated	100 (0)	100 (0)	100 (0)	100 (0)
Knee				
Extension/flexion	100 (0)	100 (0)	100 (0)	100 (0)
Foot				
Inversion/eversion	100 (0)	100 (0)	100 (0)	100 (0)

The intraobserver and interobserver reproducibility per body part showing agreement expressed as a percentage.

Statistics

To analyze reproducibility, all evaluations were performed by two investigators (A. F. and S. C. N. P.), separately. A. F. performed the evaluation twice with a 2-week interval to prevent recall bias. The reproducibility of the evaluability per frame and the evaluation of the embryo being at rest or in movement per frame were calculated by the agreement per

frame in percentages. We determined the reproducibility of this distinction as very strong when the reproducibility was above 90%. A reproducibility score between 80% and 90% was assessed as strong.

Periods designated with an embryo to be at rest or in movement and frames classified as unevaluable were analyzed using descriptive statistics (percentages and means). For this description, the number of frames

was converted into time in seconds by dividing the number of frames by the frame rate.

The reproducibility of the anatomic position at rest was calculated for each body part. Agreement on the designation of the anatomic position was calculated in the evaluable frames and expressed as percentages. Furthermore, per body part the percentage of frames was calculated in which a body part was in a specific anatomic position by dividing the amount of frames in that specific position by the total evaluable frames.

Study approval

The study was approved by the Medical Ethics Committee of the Erasmus MC on the December 1, 2015 (NL54526.078.15 OZBS72.15068.). All participants were extensively informed and signed a written informed consent form.

Results

The number of recruited women for this study was 23. The ultrasound data of one woman was excluded

because the 4D recording was missing (due to a technical problem) and the datasets of six women were not eligible due to low quality (quality score = 0) of the ultrasound data. The remaining 16 4D ultrasound datasets were used for further evaluation.

The characteristics of the 16 included women are depicted in Table 2. No differences were found in the characteristics between the included and excluded women. The median duration of the recordings was 23.3 min (range: 14.5–29.7). The total of 363.8 min of ultrasound data consisted of 18 743 frames (median: 1196; range: 701–2129) of which 14 904 (79.5%) frames were evaluable (median per embryo: 916; range: 488–1359). The median frame rate was 0.75 frames per second (range: 0.5–2.2).

Embryonic rest and movement

The distinction between frames showing an embryo at rest or in movement was feasible using 4D ultrasound and the I-Space VR system. In 83% of the time, it was possible to determine whether the embryo was at rest or in movement. Furthermore, the intraobserver

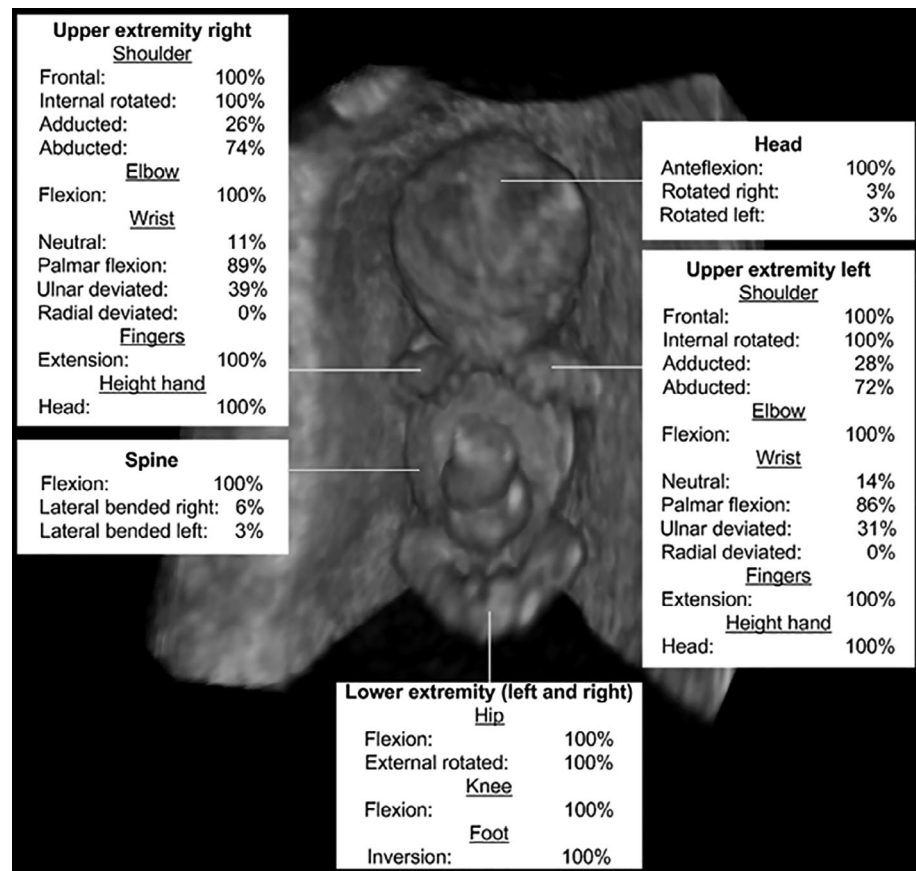


Figure 3 Overview embryonic posture. This figure shows the position of the head, spine, upper and lower extremities of an embryo between 9 and 10 weeks' GA at rest. The percentage of frames in which a body part was in a specific anatomic position is depicted per body part.

and interobserver reproducibility of the distinction between frames at rest or in movement and unevaluable frames showed an agreement of respectively, 98.5% (SD: 1.0) and 90.7% (SD: 5.0). The frames which were not classified equally by the two observers more often showed a discrepancy between rest and movement, than a discrepancy between rest and unevaluable frames or movement and unevaluable frames. The distribution between frames at rest or in movement and unevaluable frames is depicted in Figure 2. Overall, embryos were at rest in 57% (SD: 14), in movement in 26% (SD: 10) and unevaluable for assessment in 17% (SD: 21) of the time.

Embryonic posture

Evaluation of the embryonic posture was evaluated at rest. The total number of resting periods was 210. The median number of resting periods per embryo was 14 (range: 7–18). In each resting period 30 items are scored. The total amount of evaluations is 18 900. A total of 12 600 evaluations were performed by operator 1 and a total of 6300 evaluations by operator 2.

The wrists and fingers could not be described in respectively, 27% (range: 19–32) and 37% (range: 31–43) of the frames in which the position of body parts was evaluated. At rest, the embryonic posture of the head, spine, elbow, hip and knee was evaluable in 100% of the frames in which the position of body parts was evaluated (Table S1).

The intraobserver and interobserver reproducibility of the evaluation of the anatomic positions of the head, spine, upper and lower extremities at rest is shown in Table 3. Overall, a strong (80–90%) to very strong (>90%) reproducibility was seen. The interobserver reproducibility of the left wrist position showed an agreement of 77%.

Evaluation of embryonic posture at rest showed the embryos were always (100% of the frames) in the following anatomic position: head in anteflexion, spine in flexion, shoulders in frontal position and internally rotated, elbows in flexion, fingers in extension, hips in flexion and externally rotated, knees in flexion and feet in inversion (Fig. 3; and for further details Table S1).

A rotated position of the head was found in 6% of the frames and observed in 7 of the 16 embryos. The spine was laterally bent in 9% of the frames and seen in 6 out of 16 embryos. Furthermore, the left shoulder showed an abducted position in rest in 72% and the right shoulder in 74% of the frames. The wrist of the left upper extremity was in palmar flexion in 86% of

the frames and the wrist of the right upper extremity in 89% of the frames. Ulnar deviated position was seen in 31% of the frames in the left wrist and in 39% of the frames in the right wrist. No radially deviated position of the left and right wrist was seen. Additionally, the hands were in 86% of the frames positioned close to each other. The feet were positioned against each other in 85% of the frames.

Discussion

This study shows for the first time that differentiation between an embryo being at rest or in movement is feasible and reproducible using 4D ultrasound and VR techniques. Embryos at 9 weeks' GA were at rest in 57%, in movement in 26% and unevaluable for assessment in 17% of the time. Second, it is feasible to evaluate the embryonic posture at rest with a strong intraobserver and interobserver reproducibility for most body parts. At rest, the majority of the body parts were in similar anatomic positions with hands and feet close to each other. Most importantly, variations in anatomic positions at rest were already seen at 9 weeks' GA, which is an unique observation. These variations consist of the presence or absence of rotated head and lateral bended spine. The position of the shoulders and wrists respectively vary between abducted and adducted and flexed and extended.

Since the 1980s research has been performed on fetal movements to investigate the relation between neurobehavior and development.^{8,15–18} From 9 weeks onwards general movements in normally developing fetuses are fluent and complex. There is a variation in amplitude, speed, direction and participating body parts. In abnormal developing fetuses, for example, those with diabetes, fetal growth restriction and anencephaly, these characteristics do no longer exist.^{19,20} These findings form the basis to investigate the association between neurobehavior and subsequent development and health. Expanding knowledge on neurobehavior to the first trimester of pregnancy might add insights with respect to embryonic health. Moreover, the relation between first trimester embryonic health and pregnancy outcome, neonatal health or even health in later life can be explored from a new perspective.²¹ With the current unique study we have started to seek feasible and reproducible methods for exploring the hypothesis embryonic health is reflected by neurobehavior.

Strengths and limitations

This research has multiple strengths. It is the first time such detailed ultrasound examinations are performed in embryos of 9 weeks' GA. Furthermore, the ultrasound examinations, though performed in a small number of pregnancies, with a median duration of 23.3 min resulted in a large amount of 4D ultrasound data (363.8 min; 18 743 frames). Following a frame-by-frame analysis, this amount is sufficient to calculate the reproducibility which was the aim of the study. Moreover, with the use of the I-Space VR system, the third and fourth dimension can be fully explored.⁵⁻⁷ In the current study the posture of the complete embryo at rest is evaluated already in the first trimester of pregnancy, which is to the best of our knowledge the first description in literature. In previous studies, research on posture has mainly focused on position of the head and upper extremities from 12 weeks' GA onwards.^{3,4} Ververs *et al.* studied the position of the fetal head and upper extremity longitudinally in 10 uncomplicated pregnancies from 12 to 38 weeks' GA. They showed the position of the head changed from a midline to a lateralized preference.³ The current study shows lateralization of the head even earlier (9 vs 12–16 weeks' GA). With regards to the position of the upper extremity Ververs *et al.* found increasing flexion of the wrist from 12 to 38 weeks with preference from 28 weeks' GA onwards,⁴ while the current study shows the wrist to be in palmar flexion in 90% of the time already at 9 weeks' GA. Optimal image quality provides improved evaluation of posture. Adding 4D ultrasonography, which is 3D ultrasonography in time, and depth perception by using the innovative unique VR technique instead of an evaluation in 2D may also have resulted in different findings. Depth perception is obligatory for optimal visualization of the position of complex body parts, such as the joints.^{6,7} This is also the reason why we did not compare the VR findings to the 3D recordings; since 3D ultrasound without VR does not allow visualization and measurements of body parts requiring depth perception.

This study also has limitations. First, the frame rate of the 4D ultrasound examinations is low (median: 0.75 frames/s), which might result in the missing of short movements. This is in line with the study of Kuno *et al.* who examined fetal behavior, rest and activity periods, in fetuses at 14–18 weeks GA using 3D ultrasound acquiring images every 1 to 2 s.²² Promising is the ongoing attempt to expand real-time

imaging performing 3D ultrasound, as realized by the group of Lu *et al.*, using two parallel planes for fetal evaluation.²³

However, when we compare our findings and those of de Vries *et al.*, who investigated longitudinally (between 7 and 19 weeks' GA) embryo rest and movement time in 12 healthy nulliparous women by means of 2D transabdominal ultrasound,²⁴ we find a higher percentage of movement. They found a percentage of movement for nine and 10 weeks' GA of respectively 9% and 17%. In the current study, the embryo is in movement in 31% of the evaluable time, which is comparable to >11 weeks' GA in the study of de Vries *et al.* The discrepancy in time of embryonic movement might be due to the different applied techniques.

Second, 6 of the 23 datasets (26%) had to be excluded due to the low quality of the entire recording. Factors such as maternal adiposity or uterine position (ante- or retroversion) could have affected overall quality. Of the remaining 16 included datasets (18 743 frames), some frames (3839; 20.5%) were unevaluable because it was not possible to determine whether the embryo was at rest or in movement in these frames. An explanation for this result is the learning curve with regards to acquiring the best quality 4D ultrasound dataset. By enlarging the ROI including the whole gestational sac, the number of unevaluable frames decreased.

Subsequently, performing evaluation of the anatomic position of body parts, in particular the position of the small body parts (i.e. wrists and fingers), was in some frames difficult due to lack of resolution of the recording. Both the low frame rate and the low quality of the 4D ultrasound data are inherent to the current technological limitations of the ultrasound equipment, which cannot be overcome at this moment.

Since embryonic posture evaluation at rest using 4D ultrasound and VR at 9 weeks' GA is feasible and reproducible this research can be expanded over a wider range of gestational weeks in the first trimester of pregnancy. Consequently, we will be able to study embryonic posture using a longitudinal approach. Thereafter, it may allow us to detect aberrant embryonic postures and also to investigate the influences of maternal conditions, lifestyle and other environmental and genetic factors on embryonic and subsequent fetal neurobehavioral development. Expanding knowledge on neurobehavioral development and its association with pregnancy and health outcomes will

lead to a better understanding of the impact on embryonic health.

Disclosure

None declared.

References

1. Barker D, Barker M, Fleming T, Lampl M. Developmental biology: Support mothers to secure future public health. *Nature* 2013; **504**: 209–211.
2. Mulder EJ, Visser GH. Growth and motor development in fetuses of women with type-1 diabetes. II. Emergence of specific movement patterns. *Early Hum Dev* 1991; **25**: 107–115.
3. Ververs IA, de Vries JI, van Geijn HP, Hopkins B. Prenatal head position from 12–38 weeks. I. Developmental aspects. *Early Hum Dev* 1994; **39**: 83–91.
4. Ververs IA, Van Gelder-Hasker MR, De Vries JI, Hopkins B, Van Geijn HP. Prenatal development of arm posture. *Early Hum Dev* 1998; **51**: 61–70.
5. Koning AH, Rousian M, Verwoerd-Dikkeboom CM, Goedknecht L, Steegers EA, van der Spek PJ. V-scope: Design and implementation of an immersive and desktop virtual reality volume visualization system. *Stud Health Technol Inform* 2009; **142**: 136–138.
6. Rousian M, Koning AH, van der Spek PJ, Steegers EA, Exalto N. Virtual reality for embryonic measurements requiring depth perception. *Fertil Steril* 2011; **95**: 773–774.
7. Rousian M, Koster MPH, Mulders AGMJ *et al.* Virtual reality imaging techniques in the study of embryonic and early placental health. *Placenta* 2018; **64** (Suppl 1): S29–S35.
8. Luchinger AB, Hadders-Algra M, van Kan CM, de Vries JI. Fetal onset of general movements. *Pediatr Res* 2008; **63**: 191–195.
9. Bogers H, Rifouna MS, Cohen-Overbeek TE *et al.* First trimester physiological development of the fetal foot position using three-dimensional ultrasound in virtual reality. *J Obstet Gynaecol Res* 2019; **45**: 280–288.
10. Steegers-Theunissen RP, Verheijden-Paulissen JJ, van Uitert EM *et al.* Cohort profile: The Rotterdam Periconceptional cohort (predict study). *Int J Epidemiol* 2016; **45**: 374–381.
11. Verburg BO, Steegers EAP, de Ridder M *et al.* New charts for ultrasound dating of pregnancy and assessment of fetal growth: Longitudinal data from a population-based cohort study. *Ultrasound Obstet Gynecol* 2008; **31**: 388–396.
12. BMUS: Guidelines for the safe use of diagnostic ultrasound equipment [Cited 21 April 2020]. Available from URL: <https://www.bmus.org/static/uploads/resources/BMUS-Safety-Guidelines-2009-revision-FINAL-Nov-2009.pdf>
13. Rousian M, Verwoerd-Dikkeboom CM, Koning AH *et al.* Early pregnancy volume measurements: Validation of ultrasound techniques and new perspectives. *BJOG* 2009; **116**: 278–285.
14. Verwoerd-Dikkeboom CM, Koning AH, Hop WC, van der Spek PJ, Exalto N, Steegers EA. Innovative virtual reality measurements for embryonic growth and development. *Hum Reprod* 2010; **25**: 1404–1410.
15. de Vries JI, Fong BF. Changes in fetal motility as a result of congenital disorders: An overview. *Ultrasound Obstet Gynecol* 2007; **29**: 590–599.
16. de Vries JI, Visser GH, Prechtl HF. The emergence of fetal behaviour. I. Qualitative aspects. *Early Hum Dev* 1982; **7**: 301–322.
17. de Vries JI, Visser GH, Prechtl HF. The emergence of fetal behaviour. II. Quantitative aspects. *Early Hum Dev* 1985; **12**: 99–120.
18. Ianniruberto A, Tajani E. Ultrasonographic study of fetal movements. *Semin Perinatol* 1981; **5**: 175–181.
19. Sival DA, Visser GH, Prechtl HF. The effect of intrauterine growth retardation on the quality of general movements in the human fetus. *Early Hum Dev* 1992; **28**: 119–132.
20. Visser GH, Laurini RN, de Vries JI, Bekedam DJ, Prechtl HF. Abnormal motor behaviour in anencephalic fetuses. *Early Hum Dev* 1985; **12**: 173–182.
21. Steegers-Theunissen RP, Steegers EA. Embryonic health: New insights, mHealth and personalised patient care. *Reprod Fertil Dev* 2015; **27**: 712–715.
22. Kuno A, Akiyama M, Yamashiro C, Tanaka H, Yanagihara T, Hata T. Three-dimensional sonographic assessment of fetal behavior in the early second trimester of pregnancy. *J Ultrasound Med* 2001; **20**: 1271–1275.
23. Lu Y, Taizhu Y, Hong L *et al.* Visualization and quantitation of fetal movements by real-time three-dimensional ultrasound with live xPlane imaging in the first trimester of pregnancy. *Croat Med J* 2016; **57**: 474–481.
24. de Vries JI, Visser GH, Prechtl HF. The emergence of fetal behaviour. III. Individual differences and consistencies. *Early Hum Dev* 1988; **16**: 85–103.

Supporting information

Additional Supporting Information may be found in the online version of this article at the publisher's web-site:

Table S1 Embryonic positions.

Video S1 Supporting rotations procedure.

Video S2 Embryonic rest and movement.