

Three-Dimensional Finite Element Analysis of Stress Distribution and Displacement of the Maxilla Following Surgically Assisted Rapid Maxillary Expansion with Tooth- and Bone-Borne Devices

Mohsen Dalband¹✉, Jamal Kashani², Hadi Hashemzahi³

¹Assistant Professor, Dental Research Center, Department of Oral and Maxillofacial Surgery, Faculty of Dentistry, Hamadan University of Medical Sciences, Hamadan, Iran

²PhD in Mechanical Engineer, Medical Implant Technology Group, Faculty of Biosciences and Medical Engineering, Universiti Teknologi, Malaysia, Malaysia

³Assistant Professor, Department of Oral and Maxillofacial Surgery, Faculty of Dentistry, Zahedan University of Medical Sciences, Zahedan, Iran

Abstract

Objectives: The aim of this study was to investigate the displacement and stress distribution during surgically assisted rapid maxillary expansion under different surgical conditions with tooth- and bone-borne devices.

Materials and Methods: Three-dimensional (3D) finite element model of a maxilla was constructed and an expansion force of 100 N was applied to the left and right molars and premolars with tooth-borne devices and the left and right of mid-palatal sutures at the first molar level with bone-borne devices. Five computer-aided design (CAD) models were simulated as follows and surgical procedures were used: G1: control group (without surgery); G2: Le Fort I osteotomy; G3: Le Fort I osteotomy and para-median osteotomy; G4: Le Fort I osteotomy and pterygomaxillary separation; and G5: Le Fort I osteotomy, para-median osteotomy, and pterygomaxillary separation.

Results: Maxillary displacement showed a gradual increase from G1 to G5 in all three planes of space, indicating that Le Fort I osteotomy combined with para-median osteotomy and pterygomaxillary separation produced the greatest displacement of the maxilla with both bone- and tooth-borne devices. Surgical relief and bone-borne devices resulted in significantly reduced stress on anchored teeth.

Conclusion: Combination of Le Fort I and para-median osteotomy with pterygomaxillary separation seems to be an effective procedure for increasing maxillary expansion, and excessive stress side effects are lowered around the anchored teeth with the use of bone-borne devices.

Keywords: Maxillary; Expansion; Finite Element Analysis; Displacement; Stress

Journal of Dentistry, Tehran University of Medical Sciences, Tehran, Iran (2015; Vol. 12, No. 4)

✉ Corresponding author:
M. Dalband, Dental Research Center, Department of Oral and Maxillofacial Surgery, Faculty of Dentistry, Hamadan University of Medical Sciences, Hamadan, Iran

M_dalband@umsha.ac.ir

Received: 27 June 2014

Accepted: 26 January 2015

INTRODUCTION

More than 145 years ago, orthopedic maxillary expansion (OME) was first described in a case report [1]. After initially falling to disrepute, it was introduced once again in the middle of the past century [2]. Orthopedic maxillary expansion has now become a routine method

in treating maxillary transverse deficiency (MTD) in a variety of malocclusions in young orthodontic patients. There is lack of definitive guidelines enabling the orthodontists to select an age-appropriate procedure for treating MTD. Also, OME can produce unwanted effects when used in a skeletally mature

patient, including lateral tipping of posterior teeth [3,4], extrusion [5,6], periodontal membrane compression, buccal root resorption [7], alveolar bone bending [4], fenestration of the buccal cortex [8], inability to open the midpalatal suture, pain, and instability of the expansion [4]. Several reasons have been speculated for limitation of orthopedically-induced maxillary expansion in patients with skeletal maturation. They all seem to be related to age-dependent changes in osseous articulations of the maxilla with the adjoining bones. However, there are a few contradictory reports, which state that nonsurgical maxillary expansion is as much successful in adults as it is in children [9]. The incidence of MTD in the deciduous and mixed dentitions is estimated at 8–18% of patients having orthodontic consultations [10]. The incidence of MTD in the adult population or in skeletally mature subjects cannot be elucidated from the literature. Surgical procedures to facilitate transverse discrepancy corrections have been classified into two categories: segmenting the maxilla during a Le Fort osteotomy to reposition the individual segments in a widened transverse dimension, and surgically assisted rapid palatal expansion (SARPE). Many surgical procedures for SARPE have been designed to resect the areas of resistance to lateral expansion in the midface. The areas of resistance have been classified as anterior support (piriform aperture pillars), lateral support (zygomatic buttresses), posterior support (pterygoid junctions), and median support (midpalatalsynostosed suture) [11]. Usually, the midpalatal suture is thought to be the area of greatest resistance to expansion [3,12]. However, recent studies have emphasized the zygomatic buttress and the pterygomaxillary junction as critical areas of resistance [13,14].

To reduce resistance of these areas, surgery often involves Le Fort I osteotomy, midpalatal split, and occasionally pterygomaxillary separation. However, there are apparently no

definitive data about the extent or the procedure for SARPE.

In addition, few studies have been performed for the analysis of SARPE-induced stresses and displacement of the maxilla through the finite element method (FEM), which has been successfully used for the mechanical study of stresses and strains [15]. The aim of the present study was to evaluate the displacement of the maxilla in different surgical techniques for SARPE and to analyze stress distributions using 3D FEM with tooth- and bone-borne devices.

MATERIALS AND METHODS

Skull of a 20-year-old male requiring SARPE was digitized by cone beam computed tomography (CT) scan and saved in DICOMS format. Then inputs were made to the Mimics 10 (Materialise HQ, Leuven, Belgium), and bones were isolated from soft tissues to create a CAD model by using Solid Works 2009 (SolidWorks Co., MA, USA). In this way, five different CAD models were created, including one control group (G1) and four experimental groups (G2–G5).

The experimental groups were as follows: G2: Le Fort I osteotomy; G3: Le Fort I osteotomy + para-median osteotomy; G4: Le Fort I osteotomy + bilateral pterygomaxillary separation; and G5: Le Fort I osteotomy + para-median osteotomy + bilateral pterygomaxillary separation. The RME appliance used in this study was of the Hyrax type. It was placed in a position to deliver the force as close to the palate as possible by banding it to the maxillary first premolar and molar. The force was applied at about 100 N to the tooth- and bone-borne devices [16,17].

Three-dimensional finite element model of the maxilla was analyzed with Cosmos Works 2009 (SolidWorks Co., MA, USA) after assignment of the corresponding material properties and boundary conditions. Figure 1 shows the boundary conditions; the arrows show the rest points of our structure.

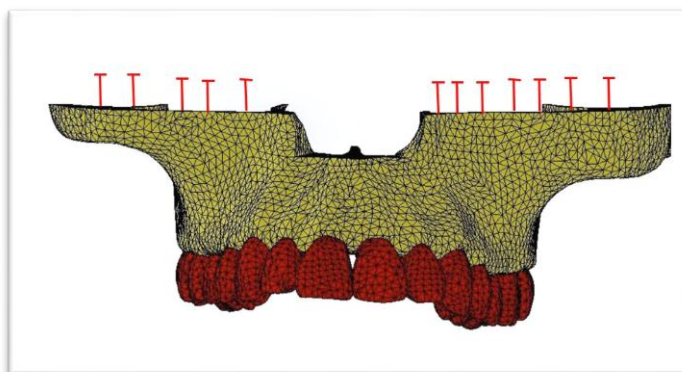


Fig. 1. Boundary conditions

The mechanical properties of the periodontal ligament (PDL), tooth and the alveolar bone were obtained from previous studies (Table 1)[18]. In each 3-D model, the stress and displacement produced in the maxilla were analyzed.

The displacements were measured on X (transverse plane), Y (anteroposterior plane), and Z (sagittal plane) axes. The internal stress reaction was measured by von-Mises stress in kg/mm^2 and presented in color contour bands; different colors represented different stress levels in the deformed state. Positive or negative values in the column of stress spectrum indicated tension or compression, respectively.

RESULTS

Displacement in the X axis:

The displacement of the maxilla in the X axis in response to different surgical techniques is illustrated in Fig. 1 and Table 2. Displacement to the right side was indicated as a positive sign (red color) and to the left side as a negative sign (blue color). In the tooth-borne control group, the maxillary premolars and first molars, which were the anchored teeth showed maximum movement. In both tooth-borne and bone-borne groups displacement in the X axis gradually increased from G1 to G4, exhibiting maximum displacement in G5 (Table 2). The increase was mainly observed in the posterior region of the maxilla.

Table 1. Mechanical properties (measured in Pa)

Material	Young's Modulus	Poisson's Ratio
Tooth	2.6×10^6	0.3
PDL	5.0×10^3	0.49
Alveolar bone	1.4×10^6	0.3

Table 2. Comparison of the mean values of displacements (mm) in X, Y, and Z axes in tooth-borne devices

Group	X axis			Y axis			Z axis		
	Min	Max	Mean	Min	Max	Mean	Min	Max	Mean
1	-6.60	6.30	6.45	-1.40	2.40	1.90	-2.90	3.00	2.95
2	-2.10	17.00	19.00	-3.20	6.50	4.75	-7.80	17.00	12.40
3	-26.00	21.00	23.50	-3.20	11.00	7.10	-14.00	19.00	16.50
4	-24.00	20.00	22.00	-3.00	7.10	5.05	-8.60	21.00	14.80
5	-29.00	26.00	27.50	-3.00	12.00	7.50	-16.00	24.00	20.00

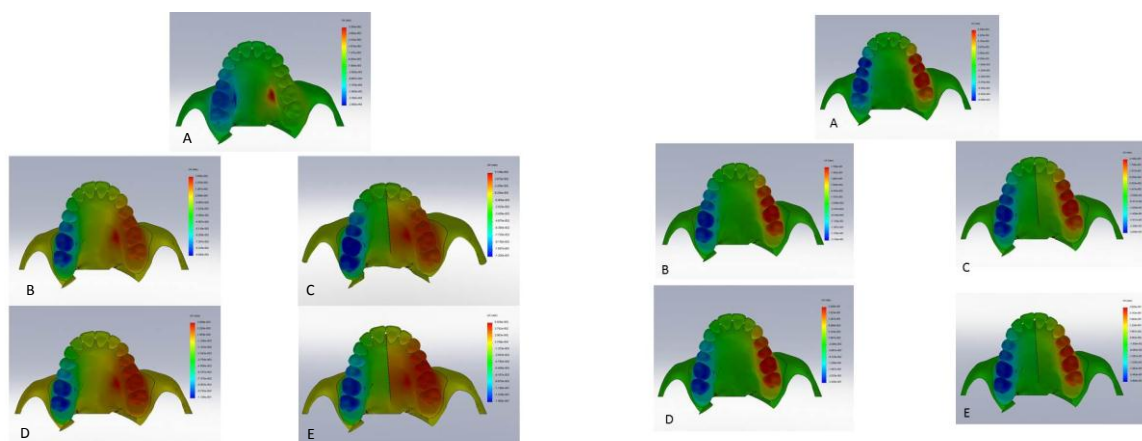


Fig. 2. Displacement of the maxilla in the X axis with SARPE by different surgical procedures (top view) with bone-borne (left) and tooth-borne (right) devices. (A), Group 1 (no surgery); (B), Group 2 (Le Fort I osteotomy); (C), Group 3 (Le Fort I osteotomy + para-median osteotomy); (D), Group 4 (Le Fort I osteotomy + pterygomaxillary separation); (E), Group 5 (Le Fort I + para-median osteotomy + pterygomaxillary separation).

In tooth-borne groups, the anchored teeth and the area around their roots showed the greatest displacement in all the groups. In both tooth-borne and bone-borne groups, the maxillary anterior teeth moved to the labial side. From G1 to G4, displacement gradually increased and in G5, a significant increase was observed (Table 2). In the bone-borne group, posterior displacement of molars was minimal.

Displacement in the Z axis:

Displacement of the maxilla in the caudal (occlusal) direction was indicated as positive (red color) and in the cephalic direction as negative (blue color) (Fig. 4). In G1, as in the X and Y axes, the anchored teeth and their root areas showed increased displacement in the inferior direction. Maximum displacement was observed in the maxillary central incisors and the roots of first molars (extrusive movement), while minimum displacement was detected around the Le Fort I osteotomy line in G1. In G4 and G5, the posterior part of the palate showed the greatest displacement in the inferior direction with movement of the incisor teeth in the superior direction. From G1 to G5, a gradual increase in displacement occurred in all the axes except in G4, in which the displacement in all the directions was smaller than that in G3.

Patterns of stress distribution:

Stress distribution was measured by von-Mises stresses and positive or negative values in the column of stress spectrum indicated tension or compression, respectively (Fig. 5, Table 3). In tooth-borne G1, the area around the roots of the anchored teeth and Le Fort I osteotomy line showed stress concentration. Although the stress distribution was relatively even in G4, the mean stress in the maxilla was the greatest (79.47 kg/mm^2 , Table 3).

In G5, the pattern of stress distribution was different.

Little stress concentration was observed around the anchored teeth and a localized concentration of stress was shown in the anterior and posterior parts of the palate. In bone-borne devices, stress values decreased from groups 1 to 5 around teeth and maxillary bone. There was no concentration of stress around specific teeth.

DISCUSSION

The SARPE is a useful method to treat MTD in adults. The surgical approaches for SARPE are different. Midpalatal osteotomy [19], Le Fort I osteotomy and maxillary segmental osteotomy [20], and zygomaticomaxillary buttress osteotomy are routine procedures [21].

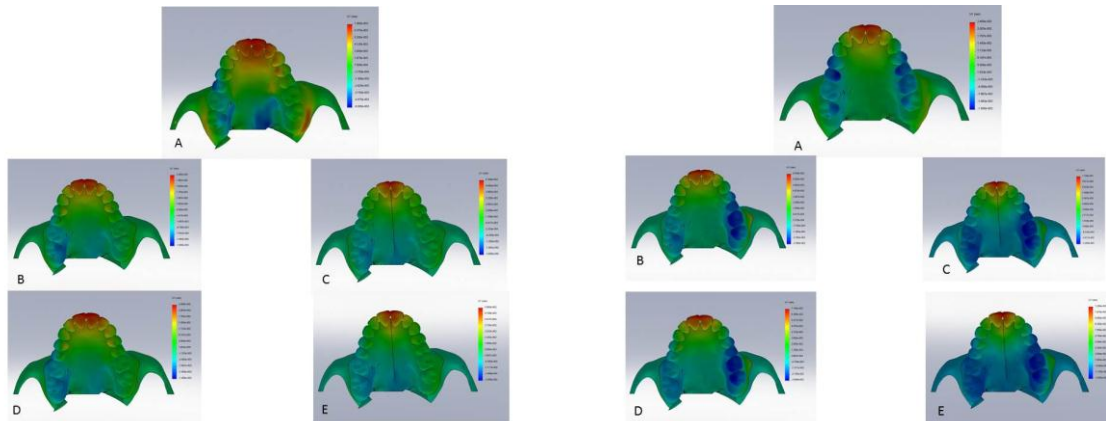


Fig. 3. Displacement of the maxilla in the Y axis with SARPE by different surgical procedures (top view) in bone-borne (left) and tooth-borne (right) devices. (A), Group 1 (no surgery); (B), Group 2 (Le Fort I osteotomy); (C), Group 3 (Le Fort I osteotomy + para-median osteotomy); (D), Group 4 (Le Fort I osteotomy + pterygomaxillary separation); (E), Group 5 (Le Fort I + para-median osteotomy + pterygomaxillary separation).

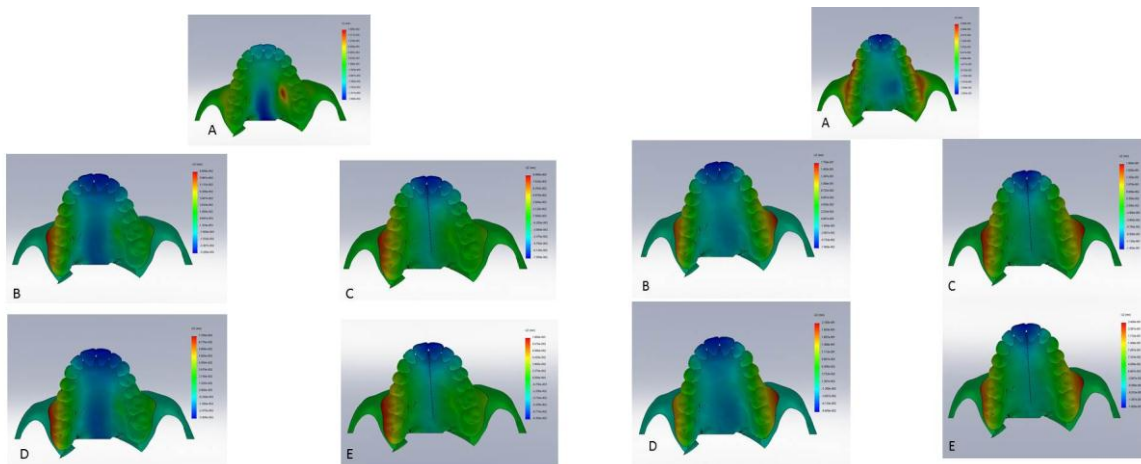


Fig. 4. Displacement of the maxilla in the Z axis with SARPE by different surgical procedures (top view) in bone-borne (left) and tooth-borne (right) devices. (A), Group 1 (no surgery); (B), Group 2 (Le Fort I osteotomy); (C), Group 3 (Le Fort I osteotomy + para-median osteotomy); (D), Group 4 (Le Fort I osteotomy + pterygomaxillary separation); (E), Group 5 (Le Fort I + para-median osteotomy + pterygomaxillary separation).

Several osteotomies are used for SARPE but there is no agreement about minimal osteotomy with favorable results. In this study, five different CAD models were constructed using FEM to evaluate stress distribution and displacement of the maxilla during SARPE in tooth-borne devices and five similar groups with bone-borne devices. Finite element analysis has been widely used for investigating stresses in the field of medicine where clinical simulations are impractical and difficult to undertake.

The patterns of the maximum and minimum displacements were not the same in all the groups because the constructed maxilla was not completely symmetrical. However, the results showed no significant differences between the groups and the overall pattern in bone-borne groups was the same as that in the tooth-borne groups. Under different surgical procedures, significant differences in the amount of displacements were observed. In the X axis, the displacement increased posteriorly from G1 to G5, except in G4.

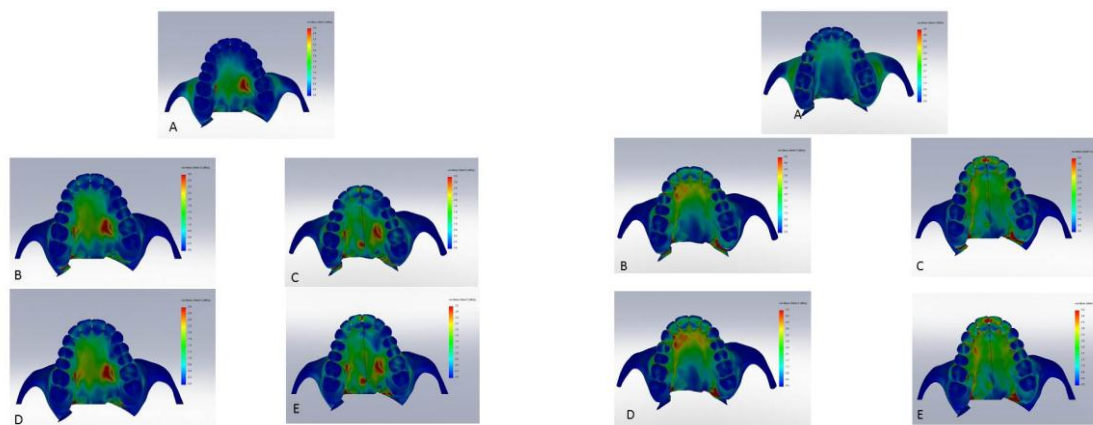


Fig. 5. Patterns of von-Mises stress with SARPE by different surgical procedures (top view) in bone-borne (left) and tooth-borne (right) devices. (A), Group 1 (no surgery); (B), Group 2 (Le Fort I osteotomy); (C), Group 3 (Le Fort I osteotomy + para-median osteotomy); (D), Group 4 (Le Fort I osteotomy + pterygomaxillary separation); (E), Group 5 (Le Fort I + para-median osteotomy + pterygomaxillary separation).

Displacement in G4 was smaller than that in G3. In G5, the area of maximum displacement moved from the first premolars and first molars to the first and second molars; thus, it seems that for establishing a favorable maxillary expansion in the posterior maxilla, all the three osteotomy procedures are required.

In the Y axis, displacement also increased from G1 to G5, except in G4, in which the displacement was lower than that in G3. Maxillary anterior teeth moved labially in G1 to G5. Molar teeth moved posteriorly with tooth-borne devices but with bone-borne devices their movement was minimal, so that labial protrusion of the anterior teeth was possible with all the methods and also in both groups. In the Z axis, the displacement increased from G1 to G5, except in G4, in which the displacement was less than that in G3.

It should be noted that the separation of pterygomaxillary junction resulted in a significant increase in the mean displacement in all the three axes, when combined with Le Fort I and para-median osteotomy.

Holberg et al. reported that additional pterygomaxillary junction release is a reasonable procedure for reducing stresses near the cranial base. The results of our study were consistent with those of Holberg et al [15].

Another finding of our study was that the patterns and magnitude of stresses were significantly different, depending on the surgical procedure. A limitation of our study was exact comparison of the amount of stresses in the maxillary bone. The surgical osteotomy resulted in a significant decrease in stresses around the anchored teeth and the maxilla with both tooth-borne and bone-borne devices (Table 3).

Table 3. Comparison of the mean values of displacements (mm) in X, Y, and Z axes in bone-borne devices

Group	X axis			Y axis			Z axis		
	Min	Max	Mean	Min	Max	Mean	Min	Max	Mean
1	-2.90	3.20	3.05	-0.60	0.75	0.67	-1.60	1.80	1.70
2	-9.40	3.40	6.40	-1.40	2.30	1.85	-3.20	6.80	5.00
3	-12.00	5.10	8.55	-2.60	5.30	3.95	-7.50	9.00	8.25
4	-11.00	3.50	7.25	-1.40	2.40	1.90	-3.40	7.70	5.55
5	-15	5.50	10.25	-2.50	5.80	4.15	-8.30	10.00	9.15

Thus, to minimize complications such as root resorption [22], extrusion of teeth attached to the appliance [23], and gingival recession [24], the bone support of the teeth should not be compromised in the SARPE patients considering the concentration of stresses around the anchor teeth, as suggested by Anttila et al [25]. In addition, the increase in the maxillary stress (total maxillary area in Table 3) may be correlated with the decreased stress in suture area and subsequently, re-distribution of stress within the palatal vault. Recently, some bone-borne devices have been introduced to resolve complications caused by using tooth-borne devices. These devices were used in cases of missed anchor teeth or periodontally compromised patients [26,27]. However, some problems such as difficult handling, or lack of sufficient stability result in an increased risk of aspiration reported by using these devices [28,29]. The results of our study showed no more stress concentration by using bone-borne devices compared with the use of tooth-borne devices. The results of our study were obtained from a CAD model, which might be different from the clinical situations. Therefore, the results can be interpreted as a reference to help make clinical judgments. Since assessment of stress concentration in suture area is difficult, future studies are recommended for measuring stress concentration in this area.

CONCLUSION

Under the limitations of this study, combination of Le Fort I and para-median osteotomy with pterygomaxillary separation seems to be an effective procedure for increasing maxillary expansion, and excessive stress side effects are lowered around the anchored teeth with the use of bone-borne devices.

REFERENCES

1- Pektas ZO, Kircelli BH, Cilasan U. Modified osteotomy to manage anterior

constriction with surgically assisted rapid maxillary expansion. *J Oral Maxillofac Surg.* 2008 Jul;66(7):1538-41.

2- Ribeiro GLU, Retamoso LB, Moschetti AB, Mei RMS, Camargo ES, Tanaka OM. Palatal expansion with six bands: an alternative for young adults. *Rev Clín Pesq Odontol.* 2009; 5(1):61-6.

3- Timms D, Vero D. The relationship of rapid maxillary expansion to surgery with special reference to midpalatal synostosis. *Br J Oral Surg.* 1981 Sep;19(3):180-96.

4- Doruk C, Sökücü O, Biçakçı AA, Yılmaz U, Taş F. Comparison of nasal volume changes during rapid maxillary expansion using acoustic rhinometry and computed tomography. *Eur J Orthod.* 2007 Jun;29(3): 251-5.

5- Garrett BJ, Caruso JM, Rungcharassaeng K, Farrage JR, Kim JS, Taylor GD. Skeletal effects to the maxilla after rapid maxillary expansion assessed with cone-beam computed tomography. *Am J Orthod Dentofacial Orthop.* 2008 Jul;134(1):8-9.

6- Kartalian A, Gohl E, Adamian M, Enciso R. Cone-beam computerized tomography evaluation of the maxillary dentoskeletal complex after rapid palatal expansion. *Am J Orthod Dentofacial Orthop.* 2010 Oct;138(4): 486-92

7- Cortese A, Savastano M, Savastano G, Papa F, Howard CM, Claudio PP. Maxillary constriction treated by a new palatal distractor device: surgical and occlusal evaluations of 10 patients. *J Craniofac Surg.* 2010 Mar;21(2): 339-43.

8- Shetty V, Caridad JM, Caputo AA, Chaconas SJ. Biomechanical rationale for surgical-orthodontic expansion of the adult maxilla. *J Oral Maxillofac Surg.* 1994 Jul;52 (7):742-9.

9- Hansen L, Tausche E, Hietschold V, Hotan T, Lagravère M, Harzer W. Skeletally-anchored rapid maxillary expansion using the Dresden Distractor. *J Orofac Orthop.* 2007 Mar;68(2):148-58.

- 10- Wehrbein H, Göllner P. Skeletal anchorage in orthodontics--basics and clinical application. *J Orofac Orthop.* 2007 Nov;68(6):443-61.
- 11- Suri L, Taneja P. Surgically assisted rapid palatal expansion: a literature review. *Am J Orthod Dentofacial Orthop.* 2008 Feb;133(2):290-302.
- 12- Lagravère MO, Carey J, Heo G, Toogood RW, Major PW. Transverse, vertical, and anteroposterior changes from bone-anchored maxillary expansion vs traditional rapid maxillary expansion: a randomized clinical trial. *Am J Orthod Dentofacial Orthop.* 2010 Mar;137(3):304.e1-12
- 13- Handelman C. Palatal expansion in adults: The nonsurgical approach. *Am J Orthod Dentofacial Orthop.* 2011 Oct;140(4):462, 464, 466 passim.
- 14- Bell WH, Jacobs JD. Surgical-orthodontic correction of horizontal maxillary deficiency. *J Oral Surg.* 1979 Dec;37(12):897-902.
- 15- Holberg C, Steinhauser S, Rudzki I. Surgically assisted rapid maxillary expansion: midfacial and cranial stress distribution. *Am J Orthod Dentofacial Orthop.* 2007 Dec;132(6):776-82.
- 16- Cozza P, Giancotti A, Petrosino A. Rapid palatal expansion in mixed dentition using modified expander: a cephalometric investigation. *J Orthod.* 2001 Jun;28(2):129-34.
- 17- Harzer W, Schneider M, Gedrange T, Tausche E. Direct bone placement of the hyrax fixation screw for surgically assisted rapid palatal expansion (SARPE). *J Oral Maxillofac Surg.* 2006 Aug;64(8):1313-7.
- 18- Lamparski D, Rinchuse D, Close J, Sciote J. Comparison of skeletal and dental changes between 2-point and 4-point rapid maxillary expanders. *Am J Orthod Dentofacial Orthop.* 2003 Mar;123(3):321-8.
- 19- Crismani AG, Bernhart T, Baier C, Bantleon HP, Kucher G. Chair-side procedure for connecting transpalatal arches with palatal implants. *Eur J Orthod.* 2002 Aug;24(4):337-42.
- 20- Steinhauser EW. The midline-splitting of the maxilla for correction of malocclusion. *J Oral Surg.* 1972 Jun;30(6):413-22.
- 21- Lee K, Sugiyama H, Imoto S, Tanne K. Effects of bisphosphonate on the remodeling of rat sagittal suture after rapid expansion. *Angle Orthod.* 2001 Aug;71(4):265-73.
- 22- Carmen M, Marcella P, Giuseppe C, Roberto A. Periodontal evaluation in patients undergoing maxillary expansion. *J Craniofac Surg.* 2000 Sep;11(5):491-4.
- 23- Ribeiro GLU, Retamoso LB, Moschetti AB, Mei RMS, Camargo ES, Tanaka OM. Palatal expansion with six bands: an alternative for young adults. *Rev Clín Pesq Odontol.* 2009; 5(1):61-6.
- 24- Carmen M, Marcella P, Giuseppe C, Roberto A. Periodontal evaluation in patients undergoing maxillary expansion. *J Craniofac Surg.* 2000 Sep;11(5):491-4.
- 25- Anttila A, Finne K, Keski-Nisula K, Somppi M, Panula K, Peltomäki T. Feasibility and long-term stability of surgically assisted rapid maxillary expansion with lateral osteotomy. *Eur J Orthod.* 2004 Aug;26(4):391-5.
- 26- Ramieri G, Spada MC, Austa M, Bianchi SD, Berrone S. Transverse maxillary distraction with a bone-anchored appliance: dentoperiodontal effects and clinical and radiological results. *Int J Oral Maxillofac Surg.* 2005 Jun;34(4):357-63.
- 27- Koudstaal M, van der Wal KJH, Wolvius EB, Schulten AJM. The Rotterdam Palatal Distractor: introduction of the new bone-borne device and report of the pilot study. *Int J Oral Maxillofac Surg.* 2006 Jan;35(1):31-5.
- 28- Neyt NM, Mommaerts MY, Abeloos JV, De Clercq CA, Neyt LF. Problems, obstacles and complications with transpalatal distraction in non-congenital deformities. *J Craniofac Surg.* 2002 Jun;30(3):139-43.

29- Seitz O, Landes CA, Philipp DJ, Sader R, Klein CM. Reliable surgically assisted rapid palatal expansion by maxillary widening device. *J Craniofac Surg.* 2008 May; 19(3): 846-9.