



Case report

Liquid fluorocarbon lavage to clear thrombus from the distal airways after severe pulmonary hemorrhage requiring extracorporeal life support (ECLS)



Christopher M. Horvat¹, Joseph A. Carcillo¹, Cameron Dezfulian^{1,2,*}

Department of Critical Care, University of Pittsburgh Medical Center, Pittsburgh, PA, USA

A B S T R A C T

Keywords:

Liquid fluorocarbon
Pulmonary hemorrhage
Extracorporeal life support
Airway thrombus

Massive pulmonary hemorrhage can pose a significant therapeutic challenge. Traditional methods of airway clearance using saline lavage and direct thrombus removal via bronchoscopy have limited ability to retrieve thrombi from deep airways. We report a patient on extracorporeal life support with massive pulmonary hemorrhage resulting in extensive alveolar and airway thrombus extending well beyond the proximal airways and the novel use of perfluorodecalin lavage to facilitate airway clearance and lung recruitment.

Clinical trial registration: None.

© 2015 The Authors. Published by Elsevier Ltd. This is an open access article under the CC BY-NC-ND license (<http://creativecommons.org/licenses/by-nc-nd/4.0/>).

Introduction

Conventional approaches to treating pulmonary hemorrhage rely on sustained positive pressure ventilation to tamponade bleeding, with eventual expectoration and absorption of coagulated blood once the acute hemorrhage has resolved. In cases of severe pulmonary hemorrhage with significant compromise of oxygenation and ventilation, extracorporeal life support (ECLS) can be used to provide time for lung recovery. This therapy is complicated, however, by the need for anticoagulation. After bleeding has stopped, bronchoscopy is the primary therapeutic option for reopening obstructed airways, though its utility is largely limited to the proximal airways, where suction and biopsy forceps can be used to manually retrieve clot [1,2]. We describe the use of perfluorodecalin (PFD) lavage to facilitate airway clearance and lung recruitment in the setting of pulmonary hemorrhage.

Case

A previously healthy 17 year-old female presented with a 5 day history of fevers, chills, cough, myalgia and shortness of breath. She

was treated for community-acquired pneumonia but had substantial increase in her oxygen requirements resulting in transfer to the PICU and mechanical ventilation. Placement of a pigtail catheter for pneumothorax was complicated by the development of hemothorax, pulmonary hemorrhage and marked hemodynamic instability. On hospital day #10 she was placed on veno-arterial ECLS.

Chest CT demonstrated fluid-filled airways with complete opacification of both lungs and bronchoscopy revealed thrombus occluding both mainstem bronchi. Sequential attempts at saline lavage to clear these thrombi were minimally successful. The patient's inability to wean from ECLS in the setting of her lung disease prompted the care team to explore less conventional modalities of pulmonary lavage. PFD (OriGen Biomedical, Inc, Austin, TX, USA) was obtained on a compassionate use basis and several aliquots were used to lavage the distal airways of the left lung. Subsequently, the patient was able to cough up some clot debris. Based on the relative success of these small-volume lavages, 250 mL, or approximately 4 mL/kg of PFD was gradually introduced to the left lung over approximately 4 h under bagged pressures of 20/10 mmHg. The patient was then placed on pressure control mechanical ventilation, 20/10 mmHg, overnight. Repeat bronchoscopy the following day demonstrated soft thrombus in the main trachea just distal to the endotracheal tube that had apparently been softened and buoyed up by the PFD. Clot was removed over approximately 4 h with simple suctioning until only clear liquid could be aspirated. A short period of high-frequency oscillatory ventilation was used to optimize recruitment, with the subsequent chest xray demonstrating significant recruitment of the bilateral upper lobes and left lower

* Corresponding author. Department of Critical Care Medicine, 3434 Fifth Avenue, Pittsburgh 15260, PA, USA. Tel.: +1 412 383 3128; fax: +1 412 383 1080.

E-mail address: dezfulianc@upmc.edu (C. Dezfulian).

¹ Department of Critical Care Medicine, Suite 0200 Faculty Pavilion, Children's Hospital of Pittsburgh UPMC, 4401 Penn Avenue, Pittsburgh, PA 15224.

² Safar Center for Resuscitation Research, 3434 Fifth Avenue, 206B Hill Building, Pittsburgh, PA 15260, USA. No reprints will be ordered.

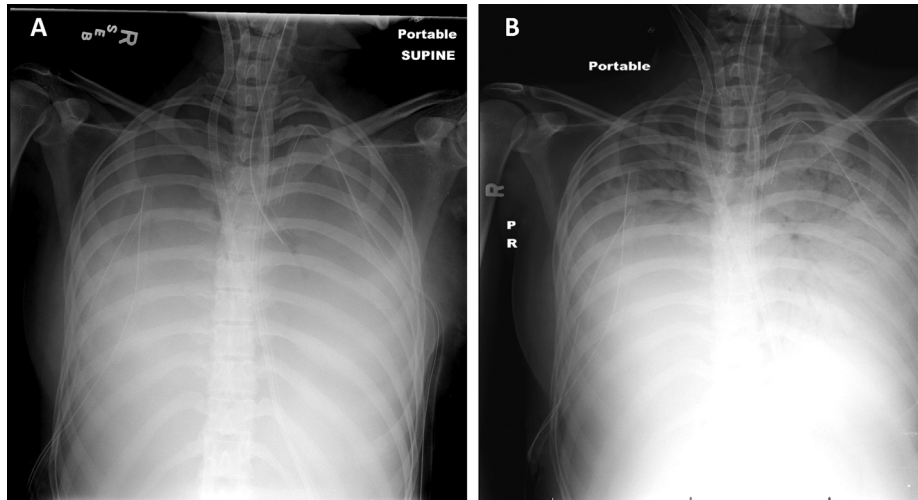


Fig. 1. Chest X-rays obtained prior to pulmonary lavage with PFD (A) and following suctioning of PFD, thrombus and approximately 24 h of recruitment with high-frequency oscillatory ventilation (B). There is interval improvement in aeration and new air bronchograms consistent with clot removal. PFD, perflurodecalin.

lobe far beyond the extent to which bronchoscopy can visualize (Fig. 1). The patient's primary disease process prevented further weaning from ECLS and she eventually received a double lung transplant, with the explanted lung revealing extensive necrosis and pneumonia attributed to *Staphylococcus aureus*.

Discussion

Perfluorocarbons have been examined for a variety of potential pulmonary applications, including tidal liquid ventilation, partial liquid ventilation, and as lavage solutions [3,4]. PFD also holds unique potential in airway lavage and alveolar recruitment in the setting of pulmonary hemorrhage. The density of human clot has been reported as $(1.08 \pm 0.02) \times 10^3 \text{ kg/m}^3$, which is slightly greater than aqueous 0.9% NaCl, which has a density of $1.00 \times 10^3 \text{ kg/m}^3$ at 37 °C [5,6]. In contrast, the density of PFD is $1.93 \times 10^3 \text{ kg/m}^3$, allowing it to buoy thrombus to the proximal airways where it can be retrieved via bronchoscopy [7]. Alveolar surface phospholipids are inhibited by the presence of fibrin, thereby raising the surface tension and promoting alveolar derecruitment [8]. The addition of small volumes of liquid fluorocarbon has been shown to significantly decrease the magnitude of pressure required to recruit alveoli [9,10]. This impact is theorized to stem from the positive spreading coefficient of liquid fluorocarbons relative to surfactant, particularly at the alveolar septal crests [10,11].

Once sufficient lung function has recovered, PFD can be removed via direct suction or allowed to passively evaporate. Systemic absorption of PFD has not been reported, though patients treated with perflubron, a comparable liquid fluorocarbon, demonstrate small but quantifiable serum levels of the substance following instillation in the lungs [12]. While promising for acute therapies, it must be noted that robust long-term data on the effects of perfluorocarbon lavage and ventilation do not exist, though existing case reports of patients evaluated 9–12 years following treatment make no mention of any detrimental impact [13,14]. The use of PFD lavage in this case demonstrates the potential utility of this unique medium for concomitant ventilation and lavage in patients suffering from severe pulmonary hemorrhage with distal airway obstruction resulting from in situ thrombus.

Funding source

No external funding was secured for this study.

Financial disclosure

The authors have no financial relationships relevant to this article to disclose.

Conflict of interest

The authors have no conflicts of interest to disclose.

Acknowledgments

Dr. Dezfulian is supported by NINDS (K08NS069817).

References

- [1] Kamat PP, Popler J, Davis J, Leong T, Piland SC, Simon D, et al. Use of flexible bronchoscopy in pediatric patients receiving extracorporeal membrane oxygenation (ECMO) support. *Pediatr Pulmonol* 2011 Nov 1;46(11):1108–13.
- [2] Prentice E, Mastropietro CW. Flexible bronchoscopy for children on extracorporeal membrane oxygenation for cardiac failure *. *Pediatr Crit Care Med* July 2011;12(4):422–5.
- [3] Wolfson MR, Shaffer TH. Pulmonary applications of perfluorochemical liquids: ventilation and beyond. *Paediatr Respir Rev* 2005 Jun;6(2):117–27.
- [4] Clark LC, Gollan F. Survival of mammals breathing organic liquids equilibrated with oxygen at atmospheric pressure. *Science* 1966 Jun 24;152(3730):1755–6.
- [5] Nahirnyak VM, Yoon SW, Holland CK. Acousto-mechanical and thermal properties of clotted blood. *J Acoust Soc Am* 2006 Jun;119(6):3766–72.
- [6] Maidment DR, editor. *Handbook of hydrology*. New York: McGraw-Hill; 1993. p. 1.
- [7] [Internet] Perflurodecalin. 2014 Aug 11. Available from: <http://fluoromed.com/products/perflurodecalin.html>.
- [8] Seeger W, Günther A, Thede C. Differential sensitivity to fibrinogen inhibition of SP-C- vs. SP-B-based surfactants. *Am J Physiol* 1992 Mar;262(3 Pt 1):L286–91.
- [9] Houmes R-J, Lachmann RA, Haitsma JJ, Lachmann B. Small-dose perfluorocarbon reduces the recruitment pressure needed to open surfactant-deficient atelectatic lungs. *Acta Anaesthesiol Scand* 2006 May;50(5):586–92.
- [10] Cox PN, Frndova H, Karlsson O, Holowka S, Bryan CA. Fluorocarbons facilitate lung recruitment. *Intensive Care Med* 2003 Dec;29(12):2297–302.
- [11] Weibel ER, Bachofen H. How to stabilize the pulmonary alveoli: surfactant or fibers? *Physiology* 1987 Apr 1;2(2):72–5.
- [12] Reickert C, Prankoff T, Overbeck M, Kazerooni E, Massey K, Bartlett R, et al. The pulmonary and systemic distribution and elimination of perflubron from adult patients treated with partial liquid ventilation. *Chest* 2001 Feb;119(2):515–22.
- [13] Hagerty RD, Phelan MP, Morrison SC, Hatem SF. Radiographic detection of perflubron fluoromediastinum and fluororetroperitoneum 9 years after partial liquid ventilation. *Emerg Radiol* 2008 Jan;15(1):71–5.
- [14] Servaes S, Epelman M. Perflubron residua: 12 years following therapy. *Pediatr Radiol* 2009 Apr;39(4):393–5.