



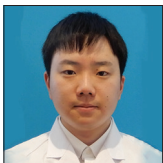
Case Report

Superior sagittal sinus dural arteriovenous fistula with changes in angiographic findings associated with contiguous parasagittal meningioma: A case report

Takahiko Nakazawa¹, Masanori Aihara¹, Hiroyuki Mizuno², Rei Yamaguchi¹, Yuhei Yoshimoto¹

¹Department of Neurosurgery, Gunma University Graduate School of Medicine, Mebashi, ²Department of Neurosurgery, Subaru Health Insurance Society Ota Memorial Hospital, Ota, Gunma, Japan.

E-mail: *Takahiko Nakazawa - takahiko.n0525@gmail.com; Masanori Aihara - masa.a6221@gmail.com; Hiroyuki Mizuno - m09201080@gunma-u.ac.jp; Rei Yamaguchi - rei.yamaguchi@gunma-u.ac.jp; Yuhei Yoshimoto - yyoshimo@gunma-u.ac.jp



*Corresponding author:

Takahiko Nakazawa,
Department of Neurosurgery,
Gunma University Graduate
School of Medicine, Mebashi,
Gunma, Japan.

takahiko.n0525@gmail.com

Received : 23 January 2022

Accepted : 01 June 2022

Published : 23 June 2022

DOI

10.25259/SNI_95_2022

Videos available on:

www.surgicalneurologyint.com

Quick Response Code:



ABSTRACT

Background: Meningioma and dural arteriovenous fistula (dAVF) located at the same site are rare. The present case demonstrated the transformation of tumor feeding vessels into the pial feeder of the dAVF over time, which may help to elucidate the pathogenesis of tumor-associated dAVF.

Case Description: A 71-year-old man presented with convulsion. Magnetic resonance (MR) imaging showed a right parasagittal sinus meningioma invading the superior sagittal sinus (SSS). Bilateral external carotid angiography showed dAVF at the SSS, near the site of tumor invasion. The right internal carotid angiography showed tumor staining from the anterior cerebral artery with intra-tumor arteriovenous shunting, with stagnation of tumor blood flow, suggesting impairment of perfusion to the SSS. Four years after the initial diagnosis, the patient was admitted to hospital with status epilepticus, and MR imaging showed an enlarged tumor. Carotid angiography revealed transformation of the tumor feeders to the pial feeder of the dAVF. The findings of shunting to the SSS had intensified, and stenosis had occurred in the posterior third of the SSS. The venous return showed retrograde flow anteriorly to the SSS. The patient underwent endovascular embolization and tumor resection. The shunt had disappeared.

Conclusion: This report supports the proposal that impaired venous return is an important factor in the shunt occurrence of dAVF. Neurosurgeons should consider that cases of meningioma invading the venous sinuses may be complicated by dAVF and changes may occur over time.

Keywords: Dural arteriovenous fistula, Meningioma, Venous pressure

INTRODUCTION

The etiology of dural arteriovenous fistula (dAVF) is still unclear, but may include congenital factors and acquired factors such as venous sinus hypertension caused by obstruction of the venous sinuses due to trauma, surgical invasion, infection, or tumor.^[14] dAVF commonly coexists with meningioma, sometimes associated with occlusion of the venous sinuses by the meningioma.^[1-3,5-9,13-17] dAVF may also occur at the same site or a distant site from the tumor. Most dAVFs occurring at the same site as the meningioma are located in the transverse-sigmoid sinus and rarely occur in the superior sagittal sinus (SSS).

This is an open-access article distributed under the terms of the Creative Commons Attribution-Non Commercial-Share Alike 4.0 License, which allows others to remix, transform, and build upon the work non-commercially, as long as the author is credited and the new creations are licensed under the identical terms.

©2022 Published by Scientific Scholar on behalf of Surgical Neurology International

We experienced a rare case, in which cerebral angiography showed that the tumor feeding vessels of a parasagittal meningioma with SSS invasion were transformed into the pial feeder for a dAVF that developed in the same region, with acute aggravation of the vessels. This observation may suggest a link to the pathogenesis of tumor-associated dAVF.

CASE DESCRIPTION

A 71-year-old man presented with convulsive symptoms. Computed tomography (CT) showed a 3-cm isodense mass in the right parasagittal region. T1-weighted magnetic resonance (MR) imaging showed prominent enhancement with dural tail sign after gadolinium-diethylenetriaminepenta-acid administration, suggestive of meningioma [Figures 1a and b]. Cerebral angiography showed tumor staining from the anterior cerebral artery (ACA) posterior internal frontal artery (PIFA), with an arteriovenous shunt. Simultaneous congestion findings suggested impaired drainage to the SSS [Figures 1c and d]. Bilateral external carotid angiography showed shunt blood flow from the bilateral MMAs, superficial temporal artery (STA), and occipital artery (OA) to the SSS collocated with the tumor invasion site [Figures 1e and f]. No occlusion of the SSS was detected at the site of tumor invasion, and the SSS was perfused progressively without cortical venous reflux, so the dAVF was Cognard type I.^[4]

After the initial diagnosis, the seizures were controlled and the neurological findings detected no abnormalities. The patient did not wish to receive treatment and was discharged for follow-up. Four years after the first diagnosis, he was hospitalized with status epilepticus causing intractable convulsive aggravation, so deep sedation/ventilator control was established for 5 days with propofol and midazolam. On admission, CT showed small subcortical hemorrhage in the left frontal lobe [Figure 2a]. Subsequent to the period of sedation, the patient continued to have prolonged impaired consciousness, Glasgow Coma Scale E1V1M4, severe right paralysis, and aphasia. MR imaging showed that the tumor had increased to 4 cm in size compared to 4 years ago [Figures 2b and c]. Carotid angiography showed a pial shunt from the ACA PIFA to the SSS and slight tumor staining [Figure 2d]. The findings of stagnant perfusion from the ACA were improved compared to the initial carotid angiography taken 4 years before [Figure 2e]. The SSS at the site of tumor infiltration was mildly stenotic but not occluded. The stenosis of the posterior third of the SSS and the development of dAVF seemed to have caused retrograde blood flow anteriorly in the SSS, indicating left frontal cortical venous regurgitation [Figures 2e and f]. External carotid angiography showed an increased shunt from the bilateral STAs, OAs, and MMAs to the SSS similar to the tumor invasion [Figures 2g and h]. The presence of retrograde venous sinus reflux and cortical venous reflux changed classification of the dAVF to Cognard

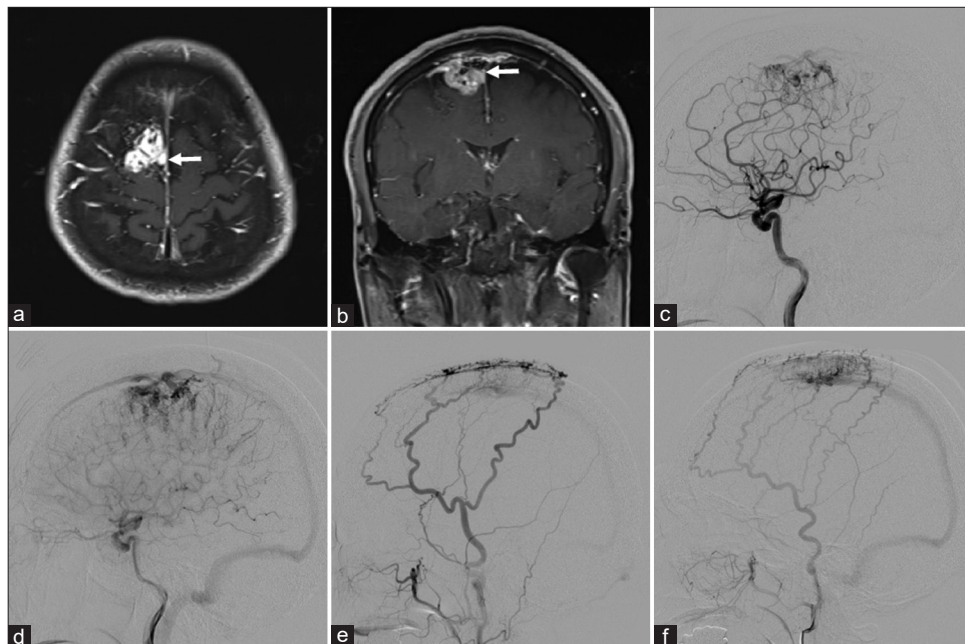


Figure 1: Parasagittal meningioma. Axial (a) and coronal (b) T1-weighted magnetic resonance images showing an enhanced tumor in the right parasagittal region that extends toward the superior sagittal sinus (SSS) (white arrow). (c) Lateral right internal carotid angiogram, arterial phase, showing a tumor blush supplied by the anterior cerebral artery (ACA). (d) Lateral right internal carotid angiogram, capillary phase, showing stasis of tumor blood flow. (e) Lateral right external carotid angiogram showing that both the middle meningeal artery (MMA) and superficial temporal artery (STA) supply the dural arteriovenous fistula (dAVF). (f) Lateral left external carotid angiogram showing that both the MMA and STA supply the dAVF.

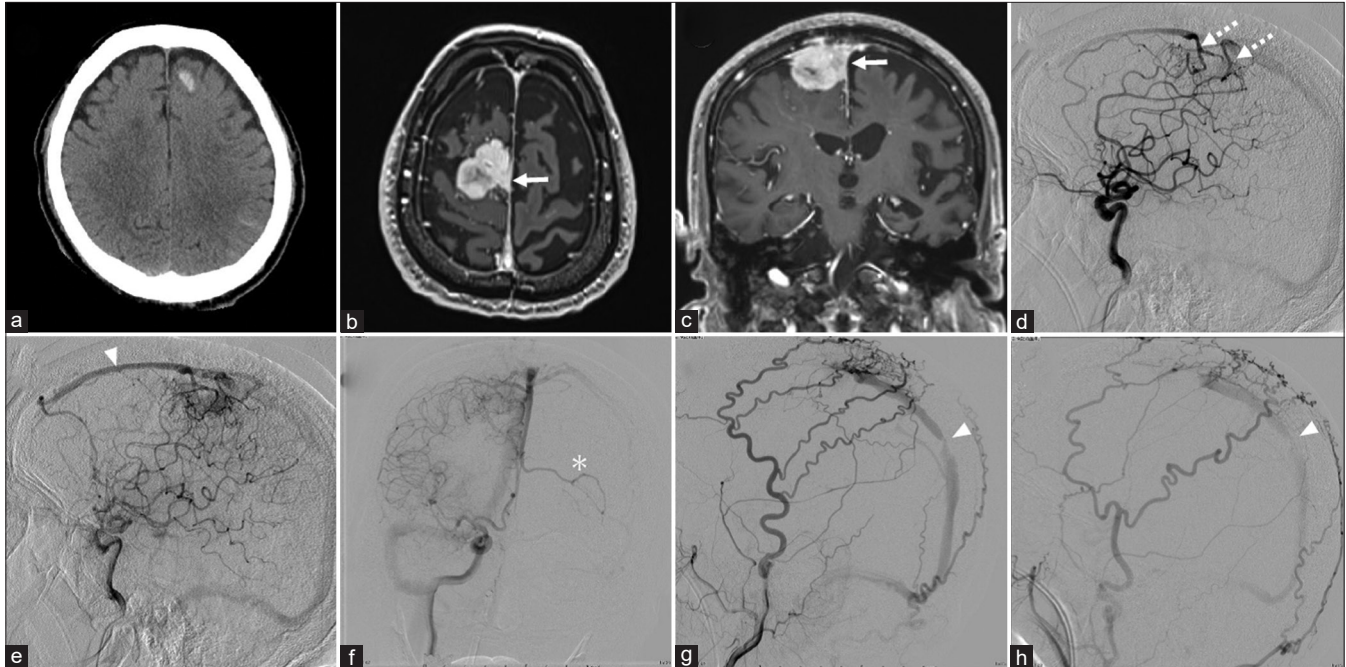


Figure 2: (a) Computed tomography scan showing left frontal subcortical hemorrhage. Axial (b) and coronal (c) T1-weighted magnetic resonance images showing a homogeneous enhanced growing tumor in the right parasagittal region that extends toward the superior sagittal sinus (SSS) (white arrow). (d) Lateral right internal carotid angiogram, arterial phase, showing a pial AVF fed by the ACA (white dotted arrow). (e) Lateral right internal carotid angiogram, capillary phase, showing retrograde blood flow anteriorly in the SSS (white arrowhead). (f) Anteroposterior right internal carotid angiogram showing cortical venous reflux in the left frontal cortex (white asterisk). Lateral right (g) and left (h) external carotid angiograms showing that the MMA, STA, and occipital artery supply the dAVF and stenosis of the posterior third of the SSS (white arrowhead).

type II a + b.^[4] Subcortical hemorrhage in the left frontal lobe was thought to be hemorrhage associated with increased left frontal cortical venous pressure.

We hypothesized that the impaired cerebral venous drainage due to stenosis of the outflow tract of the SSS dAVF was the cause of the prolonged disturbance of consciousness. To reduce the shunt blood flow, ligation of bilateral STAs and embolization of the bilateral MMAs and OAs with platinum coils were performed. Post embolization angiography showed a significant decrease in shunt blood flow from the MMAs, OAs, and STAs. However, the tumor staining and pial shunt from the ACA, and the left frontal lobe cortical venous reflux persisted [Video 1]. Ten days after the embolization, tumor removal and shunt dissection were performed [Figure 3]. After coagulation and dissection of the feeding vessels from the ACA to the tumor, the shunting vein to the SSS was coagulated and dissected. The tumor was detached from the dural attachment, but the part that infiltrated into the SSS was not removed. The dural attachment was thoroughly coagulated but partially remained, resulting in Simpson Grade IV removal.

Postoperative MR imaging showed partial removal of the tumor except for the part inside the SSS [Figures 4a and b]. Postoperative carotid angiography showed disappearance

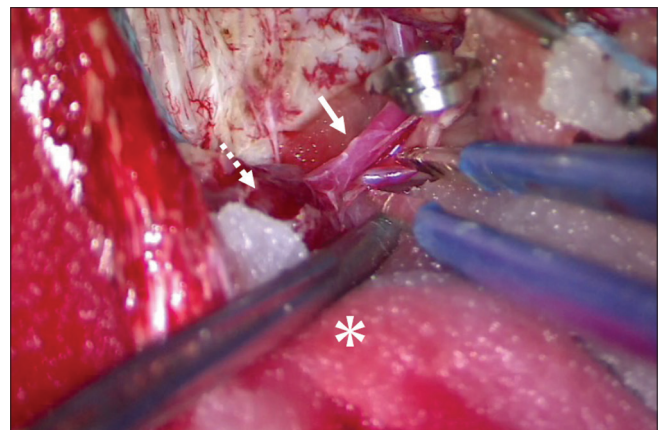


Figure 3: Tumor removal through right frontal craniotomy. The PIFA (white arrow) of the ACA was incised into the tumor (white asterisk) and a shunt vessel (white dotted arrow) was found on the anterior surface of the tumor.

of tumor staining and shunt blood flow from the ACA, and disappearance of shunt blood flow from the bilateral OAs, STAs, and MMAs to the lesion [Figures 4c-4f]. The SSS showed antegrade blood flow and no cortical venous reflux in the left frontal lobe. The postoperative pathological findings were transitional meningioma. The patient's

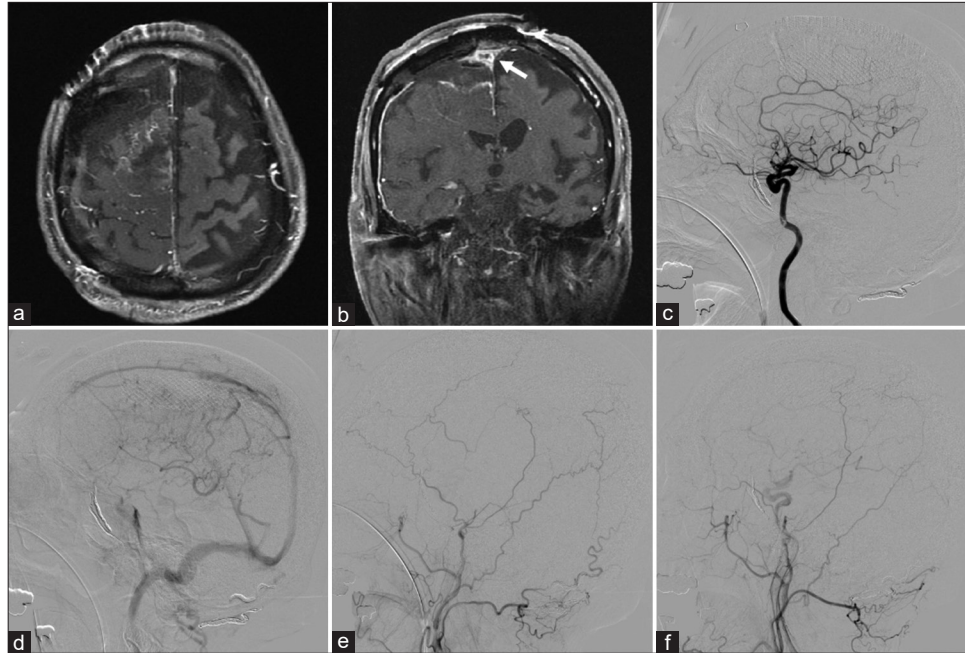
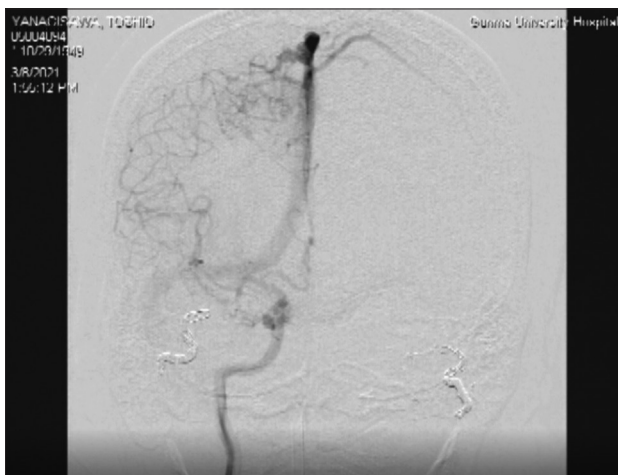

Figure 4: Postoperative axial (a) and coronal (b) T1-weighted magnetic resonance images confirming gross total resection of the tumor except for the superior sagittal sinus (SSS) invasion (white arrow). (c) Postoperative lateral right internal carotid angiogram, arterial phase, demonstrating disappearance of a pial AVF fed by the ACA. (d) Lateral right internal carotid angiogram, venous phase, showing antegrade flow of the SSS. Lateral right (e) and left (f) external carotid angiograms demonstrating disappearance of the dAVF.



Video 1: We upload a video of post-embolization right internal carotid angiography as supplementally data. Video is accessible from the portal.

condition slowly improved after the surgery, and right neglect disappeared. The right hemiparesis improved to manual muscle testing grade 2/5, and he was transferred to the rehabilitation center on postoperative day 12.

DISCUSSION

The rapid worsening of this case was apparently caused by stenosis of the posterior third of the SSS, which is the

outflow route of the dAVF with increased shunt blood flow. In addition, cerebral angiography confirmed transformation of the tumor feeding vessels into the pial feeder of the dAVF.

dAVF is a rare disease, accounting for 10–15% of all intracranial arteriovenous malformations. However, the causes of dAVF are still unknown, but are thought to be associated with a history of head trauma or craniotomy, tumor, infection, or cerebral venous sinus embolism.^[11] Meningeal tumor is often reported as associated with dAVF.^[1-3,5-9,13-17] Most previous reports describe single cases, but a series of ten cases was reported in 2014.^[2] However, the tumor and dAVF were located far apart in all cases, with no cases that occurred at the same site. Only ten cases of dAVF in the vicinity of meningeal tumor invading the venous sinuses are shown [Table 1].^[2,3,5-9,13,15,16] Five of these ten cases occurred in the transverse-sigmoid sinus,^[2,3,5,6,16] four cases were tumor invasion of the SSS with concomitant dAVF,^[8,9,13,15] one of which was not resected and was treated only as dAVF,^[15] and two were hemangiopericytomas.^[8,9] Only one case was meningioma.^[13] Acute exacerbation of dAVF at the same region as an enlarging parasagittal meningioma has only been reported in our case.

The mechanism of secondary dAVF in intracranial tumors has not been clarified. The proposed mechanisms by which meningiomas may be associated with dAVFs include direct increase in venous pressure due to invasion or compression of the venous sinuses by the tumor, indirect increase in venous

Table 1: Summary of patients with dAVF associated with meningeal tumor.

Author, Year	Age (years)/Sex	Side	Tumor location	Location of dAVF	Occluded sinus	Arterial feeders of dAVF	Treatment	Pathology
Yokota <i>et al.</i> , 1993 ^[16]	65/F	Rt	Tentorium	TS	Yes (TS)	Rt TA, Rt OA, Rt MMA	TAE+tumor resection	Transitional meningioma
Arnautovic <i>et al.</i> , 1998 ^[2]	63/F	Lt	Tentorium	TS	Yes (TS)	Rt OA, Rt MMA	TAE+tumor resection	Meningioma
Chung <i>et al.</i> , 1999 ^[3]	62/F	Rt	Tentorium	TS	Yes (TS)	Rt OA	Tumor resection	Fibroblastic type of meningioma
Vilela <i>et al.</i> , 2001 ^[15]	51/M	Rt	Falx	SPS, Convexity	Yes (SSS)	Rt MMA, Rt MHT	Shunt disconnection	-
Horinaka <i>et al.</i> , 2003 ^[6]	69/F	Rt	Tentorium	TS	Yes (TS)	Rt OA, Rt PMA	Tumor resection	Fibrous meningioma
Inoue <i>et al.</i> , 2007 ^[7]	76/M	Lt	Sphenoid ridge	CS	No (CS)	Rt MMA, Lt MHT	TAE+tumor resection	Meningothelial meningioma
Toledo <i>et al.</i> , 2010 ^[13]	60/M	Lt	Parasagittal	SSS	Yes (SSS)	Blt MMA, Blt STA	TAE+tumor resection	Meningioma
Kalani <i>et al.</i> , 2011 ^[8]	25/F	Lt	Parasagittal	SSS	Yes (SSS)	Lt MMA, Lt STA	TAE+tumor resection	Hemangiopericytoma
Enatsu <i>et al.</i> , 2012 ^[5]	76/F	Rt	Tentorium	TS	Yes (TS)	Rt OA, Rt MMA	TAE+tumor resection	Transitional meningioma
Kurisu <i>et al.</i> , 2014 ^[9]	23/M	-	Sinus confluence	Sinus confluence	Yes (SSS)	Lt PCA	TAE+tumor resection	Hemangiopericytoma
Present case	71/M	Rt	Parasagittal	SSS	No (SSS)	Blt MMA, Blt OA, Blt STA, Rt ACA	TAE+tumor resection	Transitional meningioma

ACA: Anterior cerebral artery, Blt: bilateral, CS: cavernous sinus, F: female, Lt: left, M: male, MHT: meningohypophyseal trunk, MMA: middle meningeal artery, OA: occipital artery, PCA: posterior cerebral artery, PMA: posterior branches of the middle meningeal artery, Rt: right, SPS: superior petrosal sinus, SSS: superior sagittal sinus, STA: superficial temporal artery, TA: tentorial artery, TAE: transcatheter arterial embolization, TS: transverse-sigmoid sinus, dAVF: Dural arteriovenous fistula

pressure due to brain edema around the tumor, increase in venous pressure due to meningioma with abundant blood flow, hypercoagulability of the tumor itself, or induction of angiogenic substances such as hypoxia-inducible factor-1 and vascular endothelial growth factor by the meningioma.^[2,5-7,14] The previous animal studies have shown that elevated venous pressure contributes to the formation of dAVF.^[12] In this case, we speculate that the SSS stenosis caused by infiltration of the parasagittal meningioma into the SSS may have led to an increase in venous pressure and triggered the secondary development of dAVF.

Changes in the angiographic findings were also noteworthy. At the time of the first seizure, carotid angiography showed that the blood flow of the ACA, which is the feeding vessel of the tumor, stagnated due to the increased venous pressure of the SSS. However, 4 years later, the findings of flow stagnation in the tumor feeders were improved and predominantly appeared as a pial feeder of the dAVF in the SSS. At the time of the first seizure, flow stagnation in the tumor feeder may reflect relatively early changes in intracranial blood flow due to the venous hypertension associated with dAVF. Then, we speculate that the persistent stagnation of the tumor blood flow from the ACA may have triggered the formation of a pial shunt from the ACA to the SSS dAVF. We also speculate that the persistent

increase in venous pressure caused stenosis of the SSS, leading to acute exacerbation of the dAVF symptoms. Therefore, this case may provide valuable data for elucidating the mechanism of secondary dAVF associated with tumors, based on our imaging of the changes in the shunting of the dAVF.

No definitive treatment policy has been established for cases of dAVF associated with meningioma. Some cases of dAVF spontaneously disappeared after only meningioma removal,^[1,3,10] suggesting that elevated venous pressure due to tumor may be a cause of secondary dAVF. In our case, the SSS was not completely occluded, so the tumor inside the SSS was allowed to remain. Postoperative carotid angiography showed that the compression of the SSS by the tumor improved and the perfusion of the venous sinus progressively improved, but the tumor persisted in the SSS, so elevated venous pressure may have continued. Therefore, we believe that careful imaging follow-up is necessary not only to detect tumor recurrence, but also to monitor for dAVF recurrence in the future.

CONCLUSION

This case report may support the proposal that impaired venous return is an important factor in the shunting of dAVF.

Neurosurgeons should consider that cases of meningioma invading the venous sinuses may be complicated by dAVF and changes may occur over time.

Declaration of patient consent

The authors certify that they have obtained all appropriate patient consent.

Financial support and sponsorship

Nil.

Conflicts of interest

There are no conflicts of interest.

REFERENCES

- Ahn JY, Lee BH, Cho YJ, Joo JY, Lee KS. Dural arteriovenous fistula associated with meningioma: Spontaneous disappearance after tumor removal. *Neurol Med Chir (Tokyo)* 2003;43:308-11.
- Arnautovic KI, Al-Mefty O, Angtuaco E, Phares LJ. Dural arteriovenous malformations of the transverse/sigmoid sinus acquired from dominant sinus occlusion by a tumor: Report of two cases. *Neurosurgery* 1998;42:383-8.
- Chung YG, Lee KC, Lee HK, Lee NJ. Tentorial meningioma encroaching the transverse sinuses and sigmoid sinus junction area associated with dural arteriovenous fistulous malformation: A case report. *J Korean Med Sci* 1999;14:465-8.
- Cognard C, Gobin YP, Pierot L, Bailly AL, Houdart E, Casasco A, *et al.* Cerebral dural arteriovenous fistulas: Clinical and angiographic correlation with a revised classification of venous drainage. *Radiology* 1995;194:671-80.
- Enatsu R, Asahi M, Matsumoto M, Hirai O. Meningioma-related dural arteriovenous fistula fed via a vascular tumor bed: A case report and literature review. *Clin Neurol Neurosurg* 2012;114:1010-3.
- Horinaka N, Nonaka Y, Nakayama T, Mori K, Wada R, Maeda M. Dural arteriovenous fistula of the transverse sinus with concomitant ipsilateral meningioma. *Acta Neurochir (Wien)* 2003;145:501-4; discussion 504.
- Inoue T, Nishimura S, Hayashi N, Numagami Y, Tomita T, Nishijima M. Cavernous sinus dural arteriovenous fistula associated with the development of sphenoidal ridge meningioma--case report. *Neurol Med Chir (Tokyo)* 2007;47:317-21.
- Kalani MY, Martirosyan NL, Eschbacher JM, Nakaji P, Albuquerque FC, Spetzler RF. Large hemangiopericytoma associated with arteriovenous malformations and dural arteriovenous fistulae. *World Neurosurg* 2011;76:592.e7-10.
- Kurusu K, Motegi H, Osanai T, Kobayashi H, Terasaka S, Houkin K. Regression of dural arteriovenous fistulae after venous flow reconstructive surgery in a case with hemangiopericytoma at the confluence of sinuses. *Case Rep Neurol* 2014;6:207-12.
- Manzo M, D'Urso PI. Convexity meningioma associated with noncontiguous dural arteriovenous fistula. *Surg Neurol Int* 2020;11:127.
- Reynolds MR, Lanzino G, Zipfel GJ. Intracranial dural arteriovenous fistulae. *Stroke* 2017;48:1424-31.
- Terada T, Higashida RT, Halbach VV, Dowd CE, Tsuura M, Komai N, *et al.* Development of acquired arteriovenous fistulas in rats due to venous hypertension. *J Neurosurg* 1994;80:884-9.
- Toledo MM, Wilson TJ, Dashti S, McDougall CG, Spetzler RF. Dural arteriovenous fistula associated with superior sagittal sinus occlusion secondary to invasion by a parafalcine meningioma: Case report. *Neurosurgery* 2010;67:205-7; discussion 207.
- Vellimana AK, Daniels DJ, Shah MN, Zipfel GJ, Lanzino G. Dural arteriovenous fistulas associated with benign meningeal tumors. *Acta Neurochir (Wien)* 2014;156:535-44.
- Vilela P, Willinsky R, terBrugge K. Dural arteriovenous fistula associated with neoplastic dural sinus thrombosis: two cases. *Neuroradiology* 2001;43:816-20.
- Yokota M, Tani E, Maeda Y, Yamaura I. Meningioma in sigmoid sinus groove associated with dural arteriovenous malformation: Case report. *Neurosurgery* 1993;33:316-9; discussion 319.
- Zhou LF, Chen L, Song DL, Gu YX, Leng B. Dural arteriovenous fistula of the sphenobasilar sinus with concomitant meningioma: Case report and review of the literature. *Neurosurg Rev* 2007;30:269-74; discussion 274.

How to cite this article: Nakazawa T, Aihara M, Mizuno H, Yamaguchi R, Yoshimoto Y. Superior sagittal sinus dural arteriovenous fistula with changes in angiographic findings associated with contiguous parasagittal meningioma: A case report. *Surg Neurol Int* 2022;13:275.