



Inside-Out Transcanal Endoscopic Mastoidectomy: Literature Revision

Renan Gonçalves Bessa¹ Robinson Koji Tsuji¹

¹Department of Otorhinolaryngology, Faculty of Medicine, University of São Paulo (USP), São Paulo, Brazil

Address for correspondence Renan Bessa, MD, Avenida Dr Arnaldo 455, São Paulo 01246903, Brazil (e-mail: renangbessa@hotmail.com).

Int Arch Otorhinolaryngol 2023;27(2):e370–e376.

Abstract

Introduction Recently, there have been significant advancements in transcanal endoscopic ear surgery (TEES). The combination of rigid and thin otoendoscopes with high-definition cameras enabled a less invasive transcanal access to the middle ear and a clearer view of the surgical field. Several surgeons have recently published studies about cholesteatoma resection via transcanal endoscopic surgery, even in cases where the disease has extended to the mastoid, requiring transcanal endoscopic mastoidectomy.

Objectives To analyze the currently available literature on transcanal endoscopic inside-out mastoidectomy, and to determine its efficacy as a surgical technique by evaluating the disease's relapse/recurrence rate.

Data Synthesis Initially, the titles and abstracts of articles identified were analyzed. At this stage, 117 articles were analyzed, 97 of which were excluded for not meeting the inclusion criteria. The 20 remaining articles were further evaluated. The articles were classified on the basis of five levels of scientific evidence.

Final Comments The analysis of the studies showed that the transcanal endoscopic approach is effective in providing access to the attic or antrum, especially in cases of sclerotic mastoids. There was only one study with grade A recommendation, which showed the efficacy of endoscopic ear surgery in the treatment of cholesteatoma. Furthermore, there were three studies with grade B recommendation, showing less relapse/recurrence after TEES. More studies with grade A and B recommendations are needed to better evaluate the effectiveness of TEES, especially compared with that of traditional microscopic surgery.

Keywords

- ▶ grade
- ▶ endoscopic
- ▶ recommendation
- ▶ cholesteatoma
- ▶ otology
- ▶ neurotology

Introduction

Recently, there have been significant advancements in transcanal endoscopic ear surgery (TEES), especially in minimally invasive surgery for cholesteatoma.¹ The combination of rigid and thin otoendoscopes with high-definition cameras enabled a less invasive transcanal access to the middle ear and a clearer view of the surgical field.²

Several surgeons have recently performed cholesteatoma resection via transcanal endoscopic surgery, even in cases where the disease has extended to the mastoid, requiring transcanal endoscopic mastoidectomy.³

Objectives

The objective of this systematic review was to analyze the currently available literature on transcanal endoscopic

received
September 1, 2021
accepted after revision
October 27, 2021

DOI <https://doi.org/10.1055/s-0043-1768202>.
ISSN 1809-9777.

© 2023. Fundação Otorrinolaringologia. All rights reserved.
This is an open access article published by Thieme under the terms of the Creative Commons Attribution-NonDerivative-NonCommercial-License, permitting copying and reproduction so long as the original work is given appropriate credit. Contents may not be used for commercial purposes, or adapted, remixed, transformed or built upon. (<https://creativecommons.org/licenses/by-nc-nd/4.0/>)
Thieme Revinter Publicações Ltda., Rua do Matoso 170, Rio de Janeiro, RJ, CEP 20270-135, Brazil

inside-out mastoidectomy, and to determine its efficacy as a surgical technique by evaluating the disease relapse/recurrence rate.

Materials and Methods

Search Strategy

The basic question of this review was as follows: Is transcanal endoscopic inside-out mastoidectomy effective in reducing disease recurrence/relapse?

The search strategy was based on the combination of three indicators in Portuguese and three in English, which are described in detail in **Table 1**.

The following databases were searched to identify relevant articles: PubMed, Embase, ScienceDirect, and Medline. No language or publication date restrictions were imposed.

- Subjects: Patients of any age and gender.
- Intervention: Transcanal endoscopic inside-out mastoidectomy.
- Comparison: Analysis of disease relapse/recurrence rates after applying the evaluated technique and its comparison with other established techniques.
- Outcome: Disease relapse/recurrence rate after treatment using the evaluated technique.
- Types of studies analyzed: Clinical trials, cohort studies, case-control studies, case series, and case reports.

Pre- and postoperative hearing assessments were also analyzed.

Selection Criteria

We included clinical trials, cohort studies, case-control studies, case series, and case reports with participants of any age and gender who underwent transcanal endoscopic inside-out mastoidectomy to gain access to the attic and/or antrum.

We excluded studies with participants who did not undergo transcanal endoscopic inside-out mastoidectomy, or who underwent transcanal mastoidectomy using only a microscope.

The flowchart (**Fig. 1**), shows the steps involved in the study selection process.

Literature Review

Data Analysis

Initially, the titles and abstracts of all the articles identified with the aforementioned combinations were analyzed; the articles meeting the inclusion criteria were then selected.

Table 1 Descriptors used in the systematic review

Search Strategies in Portuguese	Search Strategies in English
(mastoidectomia OU mastoidectomias OU mastoide) E (endoscópica OU endoscopia OU endoscópios OU endoscópio) E (de dentro para fora OU transcanal)	(mastoidectomy OR mastoidectomies OR mastoid) AND (endoscopic OR endoscopy OR endoscopes OR endoscope) AND (inside out OR inside-out OR transcanal)

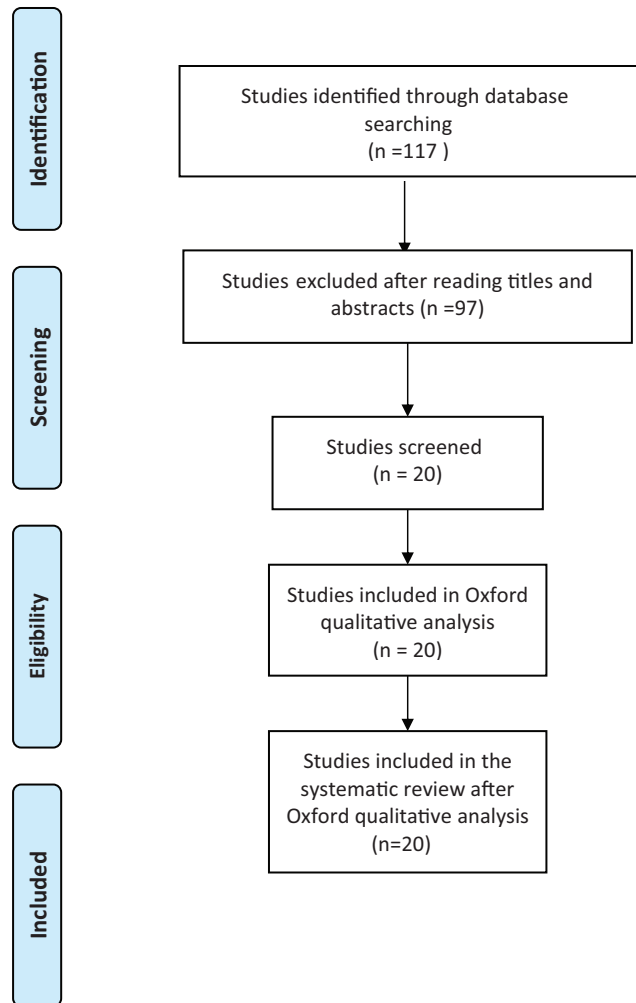


Fig. 1 Flowchart of the study selection process.

At this stage, 117 articles were analyzed, 97 of which were excluded due to not meeting the inclusion criteria.

Subsequently, the Oxford classification (**Table 2**) was used for a qualitative analysis of the 20 remaining articles (**Table 3**). The articles were classified on the basis of five levels of scientific evidence, with level 1 being the highest and most relevant level, assigned grade A recommendation.

Results

Among the articles analyzed here ($n = 20$), the oldest was published in 2000 and the most recent one in 2019. Based on the Oxford classification criteria (**Table 2**), the study types were as follows: case report ($n = 1$; level of evidence, 4; grade of recommendation, C), case series ($n = 11$; level of evidence,

Table 2 Oxford Classification

Level of Scientific Evidence per study type, Oxford Centre for Evidence-based Medicine – Latest update: May of 2001			
Level of Recommendation	Level of Evidence	Treatment/Prevention --Etiology	Diagnosis
A	1A	Systematic Review (with homogeneity) of Randomized and Controlled Clinical Trials	Systematic Review (with homogeneity) of Level Diagnostic Studies, Level 1B Diagnostic Studies Criterion, in different clinical centers
	1B	Randomized and Controlled Clinical Trial with a Narrow Confidence Interval	Validated cohort, with a good Diagnostic Criterion Referenced Standard tested in a single clinical center
	1C	“Everything or Nothing” Type of Therapeutic Outcomes	Sensitivity and Specificity near 100%
B	2A	Systematic Review (with homogeneity) of Cohort Studies	Systematic Review (with homogeneity) of diagnostic studies of level > 2
	2B	Cohort Study (including a lower quality Randomized Clinical Trial)	Exploratory cohort with a good Diagnostic Criterion Referenced Standard derived or validated in fragmented samples or databases
	2C	Observation of Therapeutic Outcomes (outcomes research) Ecological study	
	3A	Systematic Review (with homogeneity) of Case Control Studies	Systematic review (with homogeneity) of level > 3B diagnostic studies
	3B	Case Control Study	Non-consecutive selection of cases, or reference standard applied in an inconsistent fashion
C	4	Case Reports (including lower quality Case Control or Cohort)	Case Control study; or non-independent poor reference standard
D	5	Opinion without critical assessment, or based on basic subjects (physiological study or study with animals)	

4; grade of recommendation, C), observations of therapeutic results ($n=2$; level of evidence, 2C; grade of recommendation, B), cohort studies ($n=4$; level of evidence, 2B; grade of recommendation, B), case control study ($n=1$; level of evidence, 3B; grade of recommendation, B), and randomized clinical trial ($n=1$; level of evidence, 1B; grade of recommendation, A). Following the qualitative analysis based on the Oxford classification, a descriptive analysis of the articles was performed.

► **Table 4** shows the number of articles according to the grade of recommendation.

► **Table 5** lists studies with grade C recommendation.

► **Table 6** lists studies with grade A or B recommendation.

In the only study with classification 1B (N (number of patients) = 68), wherein the use of an endoscope was compared with that of a microscope for the treatment of attic cholesteatoma, the mean required area for attic exposure was significantly smaller in the endoscopic group than in the microscopic group, with a 5% significance level. Furthermore, middle ear visibility was better ($p < 0.0001$), the mean operative time was shorter ($p < 0.05$), and the mean postoperative pain was lower in the ($p < 0.05$) endoscopic group than that in the microscopic group. No significant differences were observed between groups in vertigo and air–bone gap closure postoperatively. A statistical analysis of the article,

based on the study sample, showed the results to be statistically relevant as there was substantial evidence to reject the null hypothesis.

Discussion

Of the 20 selected studies, 1 evaluated the area to be resected in the external auditory meatus for treating cholesteatoma invading the attic and/or antrum¹. TEES was the only procedure performed. The study concluded that the mean area and volume that needed to be resected were 37.3 mm² and 417 mm³, respectively, with the values being proportional to cholesteatoma size. At the 14-month follow-up, 3 of the 25 evaluated ears presented residual disease; however, there was no recurrence. Five patients underwent chain reconstruction, and all of them exhibited postoperative hearing improvement (reduced air–bone gap).

According to the literature, the use of ultrasonic aspirators or curettes confers safety and efficacy in transcanal endoscopic inside-out mastoidectomy, especially in cases of small, sclerotic mastoids. Ultrasonic equipment allows simultaneous bone cutting, irrigation, and aspiration using a single hand piece, thereby reducing the difficulty of endoscopic surgery by allowing surgeons to perform the procedure using only one hand.^{2,18}

Table 3 Articles selected for this systematic review

Number	Year	Title	Authors	Periodical	Oxford evidence
1	2016	Endoscopic Management of Attic Cholesteatoma Long-term Results (<i>n</i> = 234)	Alicandri-Ciuffelli et al. ⁴	Otolaryngol Clin N Am	4–Grade C
2	2019	Comparison of the Clinical Results of Attic Cholesteatoma Treatment: Endoscopic Versus Microscopic Ear Surgery (<i>n</i> = 20)	Bae et al. ⁵	Clinical and Experimental Otorhinolaryngology	2B – Grade B
3	2019	Endoscopic Versus Microscopic Management of Attic Cholesteatoma: A Randomized Controlled Trial (<i>n</i> = 78)	Das et al. ⁶	The Laryngoscope	1B – Grade A
4	2017	Ultrasonic bone aspirator use in endoscopic ear surgery: feasibility and safety assessed using cadaveric temporal bones (<i>n</i> = 5)	Gardner et al. ⁷	The Journal of Laryngology & Otology	4–Grade C
5	2019	Trans-canal endoscopic ear surgery and canal wall-up tympano-mastoidectomy for pediatric middle ear cholesteatoma (<i>n</i> = 49)	Glikson et al. ⁸	European Archives of Oto-Rhino-Laryngology	2B – Grade C
6	2008	Transcanal Antrotomy (<i>n</i> = 47)	Holt ⁹	The Laryngoscope	4–Grade C
7	2016	The resected area of the posterior wall of the external auditory canal during transcanal endoscopic ear surgery for cholesteatoma (<i>n</i> = 25)	Imai et al. ¹	Auris Nasus Larynx	4–Grade C
8	2019	Recidivism After Endoscopic Treatment of Cholesteatoma (<i>n</i> = 94)	Killeen et al. ¹⁰	Otology & Neurotology	2B – Grade B
9	2011	Endoscopic open technique in patients with middle ear cholesteatoma (<i>n</i> = 12)	Marchioni et al. ¹¹	Eur Arch Otorhinolaryngology	2C – Grade B
10	2011	Exclusive Endoscopic Ear Surgery for Acquired Cholesteatoma: Preliminary Results (<i>n</i> = 30)	Migirov et al. ¹²	Otology & Neurotology	2C – Grade B
11	2018	The Impact of the Transcanal Endoscopic Approach and Mastoid Preservation on Recurrence of Primary Acquired Attic Cholesteatoma (<i>n</i> = 110)	Presutti et al. ¹³	Otology & Neurotology	2B – Grade B
12	2000	Endoscopic management of cholesteatoma: long-term results (<i>n</i> = 69)	Tarabichi ¹⁴	Otolaryngology Head Neck Surg	4–Grade C
13	2010	Transcanal Endoscopic Management of Cholesteatoma (<i>n</i> = 147)	Tarabichi ¹⁵	Otology & Neurotology	4–Grade C
14	2019	The Antrum-Malleus-Tegmen Score: A Pilot Study Assessing	Tolisano et al. ¹⁶	Otology & Neurotology	3B – Grade B

(Continued)

Table 3 (Continued)

Number	Year	Title	Authors	Periodical	Oxford evidence
		Preoperative Radiographic Predictors for Transcanal Endoscopic Cholesteatoma Dissection ($n = 58$)			
15	2019	Improvement of otoendoscopic surgery for epitympanic cholesteatoma invading the mastoid ($n = 46$).	Wu et al. ¹⁷	Acta Oto-Laryngologica	4-Grade C
16	2013	Extension of Indications for Transcanal Endoscopic Ear Surgery Using an Ultrasonic Bone Curette for Cholesteatomas ($n = 43$)	Kakehata et al. ²	Otology & Neurotology	4-Grade C
17	2019	Endoscopic Inside-Out Mastoidectomy with the Ultrasonic Bone Aspirator ($n = 5$)	Mehta et al. ¹⁸	Otolaryngology Head Neck Surg	4-Grade C
18	2019	A novel endoscopic hydro-mastoidectomy technique for transcanal endoscopic ear surgery ($n = 1$)	Nishiike et al. ³	The Journal of Laryngology & Otology	4-Grade C
19	2017	Endoscopic transcanal modified canal-wall-down mastoidectomy for cholesteatoma ($n = 4$)	Sajjadi ¹⁹	World Journal Otorhinolaryngology – Head Neck Surgery	4-Grade C
20	2018	Transcanal Endoscopic Inside-out Mastoidectomy: Our Experience ($n = 25$)	Trahan et al. ²⁰	Otolaryngology – Head and Neck Surgery	4-Grade C

Note: *N* represents number of patients included in each study.

Table 4 Articles according to the grade of recommendation

Grade of recommendation	Number of articles
A	1
B	7
C	12
D	0

Three studies analyzed the use of an ultrasonic curette in atticoantrotomy via TEES. In one of them, head dissections were performed in nine patients using an ultrasonic curette ($n = 5$) or a standard ear curette ($n = 4$). Dissection time was, on average, 12 minutes shorter with the ultrasonic curette than with the standard ear curette. No complications were observed after using the former, whereas ossicular chain rupture occurred in three-fourth of the patients after the use of the latter. In the other two studies, a total of 44 patients were evaluated, with the disease extending to the antrum in 18 of them. The disease was completely removed in all patients. Only one of the studies, comprising a total of five patients, evaluated disease recurrence (no recurrence was observed in any patient at 1 year follow-up) and hearing improve-

ment (three patients undergoing reconstruction exhibited improvement after 3 months).

Resection of a cholesteatoma extending to the mastoid can be performed either via the transcortical or transcanal route. The transcortical route often requires the removal of healthy bone and mucosa; therefore, the transcanal route is preferred whenever possible.¹ A study compared the possibility of access to the attic/antrum between transcanal endoscopic surgery and traditional microscopic surgery for the treatment of cholesteatoma. In this study, a score called the antrum–malleus–tegmen (AMT) score was developed. The score¹⁶ is based on three variables: intact tegmen, intact malleus, and aerated antrum. An AMT score ≥ 2 indicates a high probability of using TEES as the single procedure for cholesteatoma resection.

According to a concept proposed by Tarabichi,¹ cholesteatoma mainly originates in the tympanic cavity and invades the mastoid in most advanced cases. This concept favors transcanal access as the most logical approach for cholesteatoma resection. Kapadiya et al.²¹ reported an increased use of endoscopic surgery as the main treatment technique for ear surgery, especially between 2011 and 2018.

Tarabichi^{15,22} reported that the transcanal microscopic view is limited by the narrowest segment of the external

Table 5 Articles with grade C recommendation

Author	Year	N	Grade of recommendation	Relapse/Recurrence TEES	Relapse/Recurrence exclusive microscope
Alicandri-Ciuffelli et al. ⁴	2016	234	C	78	Unrealized
Gardner et al. ⁷	2017	5	C	No data	Unrealized
Holt ⁹	2008	47	C	6	Unrealized
Imai et al. ¹	2016	25	C	3	Unrealized
Tarabichi ¹⁴	2000	69	C	6	Unrealized
Tarabichi ¹⁵	2010	147	C	11	Unrealized
Wu et al. ¹⁷	2019	46	C	4	No data
Takehata et al. ²	2013	43	C	No data	No data
Mehta et al. ¹⁸	2019	5	C	No data	Unrealized
Nishiike et al. ³	2019	1	C	No data	Unrealized
Sajjadi ¹⁹	2017	4	C	No data	Unrealized
Trahan et al. ²⁰	2018	20	C	2	Unrealized

Abbreviations: TEES, transcanal endoscopic ear surgery.

Table 6 Articles with grade A or B recommendation

Authors	Year	N	Grade of recommendation	Relapse/Recurrence TEES	Relapse/Recurrence exclusive microscope
Das et al. ⁶	2019	78	A	3	7
Bae et al. ⁵	2019	20	B	0	0
Glikson et al. ⁸	2019	49	B	9	19
Killeen et al. ¹⁰	2019	94	B	13	15
Marchioni et al. ¹¹	2011	12	B	2	Unrealized
Migirov et al. ¹²	2011	30	B	9	Unrealized
Presutti et al. ¹³	2018	110	B	16	40
Tolisano et al. ¹⁶	2019	58	B	No data	No data

Abbreviations: TEES, transcanal endoscopic ear surgery.

auditory canal, often leaving surgeons at a disadvantage. As conventional ear surgery usually involves the mastoid, the best approach is to gain the transcortical, retroauricular, and parallel accesses, primarily to obtain a better view of the attic, hypotympanum, and facial recesses. The transcanal endoscopic access bypasses the narrowest segment of the external auditory canal, thereby facilitating a better angle of vision and wider access to the attic, which is the most frequent site of cholesteatoma.

Mastoid cell preservation may lead to better outcomes in the treatment of acquired attic cholesteatoma, as the mastoid cell mucosa seems to significantly influence the middle ear gas exchange. Thus, the preservation of healthy mucosa and the use of a more physiological ventilation route, removing only what is necessary for treatment, are key advantages for a successful transcanal access.¹³

Small, sclerotic mastoids can present a challenge to the surgeon. The risk of injury to the tegmen, sigmoid sinus,

lateral canal, and facial nerve increases when using the classical transcortical technique with the microscope. The inside-out mastoidectomy seems to be safer in such cases.¹⁸

A total of 615 patients were analyzed in 10 studies evaluating the use of transcanal endoscopic surgery to access the attic, aditus ad antrum, or antrum. The follow-up period ranged from 12 to 122 months, with a mean of 33 months. A total of 323 patients exhibited mastoid involvement of the disease. Within that group, 83 patients experienced relapse (13.4%), 43 (6.99%) of whom exhibited mastoid involvement, and 38 patients had disease recurrence (6.1% of the total). Of the 48 patients who underwent ossicular reconstruction, 37 (77% of 48 patients) exhibited postoperative hearing improvement. One of the studies reported the use of hydro-mastoidectomy in TEES, describing that a saline infusion device coupled to the endoscope would facilitate the surgical field view and ameliorate the shadow effect caused by excess bone dust and blood during surgery.³

Three studies compared TEES and the traditional canal wall up (CWU) surgery in terms of access to both the attic and antrum. Postoperative relapse and/or recurrence rates were compared between the two. In total, 135 patients underwent TEES and 109 underwent CWU surgery. In the TEES group, 18 patients experienced relapse and 17 had disease recurrence, whereas in the CWU group, 26 patients experienced relapse and 26 had disease recurrence. The mean follow-up period was of 18.5 months for both groups. Improvement in the ability to recognize words was evaluated postoperatively, with the TEES and CWU groups exhibiting a 7.6% and 2% decrease in this ability, respectively. There was no significant difference between groups in the postoperative air–bone gap.

Two studies compared the outcomes of TEES and transcanal microscopic surgery in a total of 98 patients. The mean follow-up period was of 15 months for the former and 27 months for the latter. Of all patients, 49 underwent TEES. Four patients experienced relapse: two in the TEES group and two in the transcanal microscopic surgery group. Furthermore, disease recurrence was observed in six patients: one in the TEES group and five in the transcanal microscopic surgery group. There was no significant difference between groups in the postoperative air–bone gap.

Final Comments

The analysis of the studies showed that the transcanal endoscopic approach is effective in providing access to the attic or antrum, especially in cases of sclerotic mastoids. There was only one study with grade A recommendation, showing the efficacy of endoscopic ear surgery in the treatment of cholesteatoma. Furthermore, there were seven studies with grade B recommendation, showing less relapse/recurrence after TEES. Although no study showed greater relapse/recurrence after TEES than that after procedures using other techniques, more studies with grade A and B recommendations are needed to better evaluate the effectiveness of TEES, especially compared with that of traditional microscopic surgery.

Conflict of Interests

The authors have no conflict of interests to declare.

References

- Imai T, Nishiike S, Oshima K, Tanaka H, Tsuruta Y, Tomiyama Y. The resected area of the posterior wall of the external auditory canal during transcanal endoscopic ear surgery for cholesteatoma. *Auris Nasus Larynx* 2017;44(02):141–146. Doi: 10.1016/j.anl.2016.06.003
- Kakehata S, Watanabe T, Ito T, Kubota T, Furukawa T. Extension of indications for transcanal endoscopic ear surgery using an ultrasonic bone curette for cholesteatomas. *Otol Neurotol* 2014;35(01):101–107
- Nishiike S, Oshima K, Imai T, Uetsuka S. A novel endoscopic hydro-mastoidectomy technique for transcanal endoscopic ear surgery. *J Laryngol Otol* 2019;133(03):248–250
- Alicandri-Ciuffelli M, Marchioni D, Kakehata S, Presutti L, Villari D. Endoscopic Management of Attic Cholesteatoma: Long-Term Results. *Otolaryngol Clin North Am* 2016;49(05):1265–1270
- Bae MR, Kang WS, Chung JW. Comparison of the clinical results of attic cholesteatoma treatment: Endoscopic versus microscopic ear surgery. *Clin Exp Otorhinolaryngol* 2019;12(02):156–162
- Das A, Mitra S, Ghosh D, Sengupta A. Endoscopic Versus Microscopic Management of Attic Cholesteatoma: A Randomized Controlled Trial. *Laryngoscope* 2020;130(10):2461–2466
- Gardner EG, Sappington J, Arriaga MA, Kanotra SP. Ultrasonic bone aspirator use in endoscopic ear surgery: feasibility and safety assessed using cadaveric temporal bones. *J Laryngol Otol* 2017;131(11):987–990
- Glikson E, Feinmesser G, Sagiv D, Wolf M, Migirov L, Shapira Y. Trans-canal endoscopic ear surgery and canal wall-up tympanomastoidectomy for pediatric middle ear cholesteatoma. *Eur Arch Otorhinolaryngol* 2019;276(11):3021–3026. Doi: 10.1007/s00405-019-05588-1
- Holt JJ. Transcanal antrotomy. *Laryngoscope* 2008;118(11):2036–2039
- Killeen DE, Tolisano AM, Kou YF, Kutz JW Jr, Isaacson B. Recidivism After Endoscopic Treatment of Cholesteatoma. *Otol Neurotol* 2019;40(10):1313–1321
- Marchioni D, Villari D, Alicandri-Ciuffelli M, Piccinini A, Presutti L. Endoscopic open technique in patients with middle ear cholesteatoma. *Eur Arch Otorhinolaryngol* 2011;268(11):1557–1563
- Migirov L, Shapira Y, Horowitz Z, Wolf M. Exclusive endoscopic ear surgery for acquired cholesteatoma: preliminary results. *Otol Neurotol* 2011;32(03):433–436
- Presutti L, Anschuetz L, Rubini A, et al. The Impact of the Transcanal Endoscopic Approach and Mastoid Preservation on Recurrence of Primary Acquired Attic Cholesteatoma. *Otol Neurotol* 2018;39(04):445–450
- Tarabichi M. Endoscopic management of cholesteatoma: long-term results. *Otolaryngol Head Neck Surg* 2000;122(06):874–881
- Tarabichi M. Transcanal endoscopic management of cholesteatoma. *Otol Neurotol* 2010;31(04):580–588. Doi: 10.1097/MAO.0b013e3181db72f8
- Tolisano AM, Killeen DE, Hunter JB, Kutz JW Jr, Isaacson B. The Antrum-Malleus-Tegmen Score: A Pilot Study Assessing Preoperative Radiographic Predictors for Transcanal Endoscopic Cholesteatoma Dissection. *Otol Neurotol* 2019;40(09):e901–e908
- Wu N, Wang F, Hou Z, Yang S. Improvement of otoendoscopic surgery for epitympanic cholesteatoma invading the mastoid. *Acta Otolaryngol* 2019;139(06):492–496. Doi: 10.1080/00016489.2019.1597985
- Mehta R, Mankekar G, Mayland E, Melder K, Arriaga MA. Endoscopic Inside-Out Mastoidectomy with the Ultrasonic Bone Aspirator. *OTO Open* 2019;3(01):X18821923
- Sajjadi H. Endoscopic transcanal modified canal-wall-down mastoidectomy for cholesteatoma. *World J Otorhinolaryngol Head Neck Surg* 2017;3(03):153–159. Doi: 10.1016/j.wjorl.2017.08.003
- Trahan JR, Mehta R. Transcanal Endoscopic Inside-out Mastoidectomy: Our experience. *Otolaryngol Head Neck Surg* 2018;159(1, suppl):258–286
- Kapadiya M, Tarabichi M. An overview of endoscopic ear surgery in 2018. *Laryngoscope Investig Otolaryngol* 2019;4(03):365–373
- Tarabichi M. Endoscopic management of limited attic cholesteatoma. *Laryngoscope* 2004;114(07):1157–1162